

# Original Research Article

## Effects of Sub-chronic Administration of Crude Ethanol Extract of *Cola nitida* On Stomach Mucosa Epithelia Lining and Liver Function Enzymes in Albino Rats

### ABSTRACT

**Aim:** This study investigated the effects of sub-chronic administration of crude ethanol extract of *Cola nitida* mucosa epithelia lining and liver function enzymes in albino rats.

**Place and Duration of Study:** Department of Biochemistry and Molecular Biology and Chemical Pathology Usmanu Danfodiyo University, Sokoto, between March 2017 and January 2018.

**Methodology:** Twenty (20) albino rats were randomly divided into five (5) groups of A, B, C, D and E of four rats each and were fed with equal volume of ethanol extract of *Cola nitida* of 600, 1200, 1800 and 2400 mg/kg body weight of the rats by oral administration for 28 days, while group A serve as control, respectively.

**Results:** Result indicates the LD50 was above 5000 mg/kg B.W., serum aspartate transaminase (AST) and alanine transaminase (ALT) activity revealed a significant increase ( $P = .05$ ) for AST ( $31.23 \pm 9.39$ ), ( $40.44 \pm 12.24$ ), ( $44.59 \pm 8.69$ ), and ( $36.30 \pm 13.18$ ) in rats fed with 600, 1200, 1800 and 2400 mg/kg, and ALT ( $33.66 \pm 7.94$ ) for group fed with 2400 mg/kg B.W as compared against the control group ( $16.97 \pm 6.58$ ) and ( $20.11 \pm 4.39$ ). The serum alkaline phosphatase (ALP) also showed significant increase ( $P = .05$ ) ( $7.99 \pm 2.89$ ), ( $7.07 \pm 2.21$ ), and ( $5.49 \pm 1.28$ ) in group fed with 1200, 1800 and 2400 mg/kg as compared to the control ( $2.34 \pm 0.84$ ). Histological studies on the mucosa epithelial lining showed an eroded epithelium and vacuolations at dose above 1200 mg/kg as compared to the control group.

**Conclusion:** This study was able to establish that crude ethanol extract of *Cola nitida* have some deleterious effects on mucosa epithelia lining, liver function enzymes

**Keywords:** Liver enzymes; AST, ALT and ALP, mucosal epithelia lining, sub-chronic, *Cola nitida*

### 1. INTRODUCTION

The World Health Organization has shown that about 80% of the population from Asian and African uses traditional medicine in their primary health care system [1]. The prime benefit of using plant derived agents as medicine is their relative availability than synthetic alternatives,

thus offering profound therapeutic benefits and affordable treatment [2]. In contrast, the pharmacological benefits, and consumption of crude extracts of some of these plants may cause significant tissue damage due to potential toxic compounds and wrong agricultural practice during cultivation [3, 4]. The increasing interest and reliance on traditional medicine and many claims by some local practitioners is therefore requires a continuous risk assessment of various indigenous preparations used in the treatment of diseases [5].

*Cola nitida* of genus *Cola*, belong to the family *Sterculiaceae*; found in the tropical rainforests of Africa [6]. Its fruits contain seeds; kolanuts. The nuts is use as an aphrodisiac, appetite suppressant, and in the treatment of morning sickness, migraine headache, and indigestion [7]. It also been reported that *Cola nitida* may aggravates gastric and duodenal ulcers by increasing the level of gastric acid secretion [8]. Studies on its chemical contents such as methyl-xanthine and theobromine have been reported [9].

Previous studies have reported that administration of kolanut extract stimulates the central nervous system activities [10], increases the cardiac muscle contraction, increases glucose uptake in skeletal muscle in dogs and causes relaxation smooth muscle [11-13]. Caffeine is the major component of the kolanut extract that elicit its biological effects [14].

Researches such as Ikegwuonu et al. [15]; Salahdeen et al. [14] and Emmanuel at al. [16] have made effort to study the chronic, acute toxicity on renal and gas chromatography mass spectrometry of kolanut using different extractions. We therefore, investigated sub-chronic toxicity of ethanol extract of kolanut on liver and gastric mucosa lining which to the best of our knowledge is the first time reported.

## **2. MATERIAL AND METHODS**

### **2.1 Experimental Animals**

A total of twenty albino rats of both sexes weighing between 104 – 178 g were used for this study. The animals were procured and maintained in the animal house of the Department of Biological Sciences, Usmanu Danfodiyo University, Sokoto – Nigeria. The animals were treated in accordance with the “Guide for the Care and Use of Laboratory Animals” prepared by the National Academy of Sciences and published by the National Institute of Health (NIH, 1985). The animals were housed in metal cages and maintained on standard rat chow (Neimeth Livestock Feed, Ikeja, Lagos) *ad libitum* and allowed free access to clean drinking water.

### **2.2 Plant Material**

Fresh *Cola nitida* seeds were procured from a local market in Sokoto Metropolis, Sokoto State, Nigeria between the months of March 2017 to January 2018. The fresh *cola nitida* seeds were then taken to the herbarium section of the Department of Biological Sciences, Usmanu Danfodiyo University Sokoto for identification and documentation. The plant material was given a voucher specimen number UDUH/ANS/0854.

### **2.3 Sample Digestion**

The fresh *Cola nitida* nuts was washed with distilled water and cut into pieces, dried and pulverized. One hundred grams (100g) portion of the powdered seeds was extracted by macerating with 70% ethanol and allowed for 3 days after which it was filtered using a clean muslin cloth and subsequently with cleaned Whatman no. 1 filter paper. The filtrate was

evaporated to dryness at temperature between 40-45°C. The extract obtained was stored in a plastic container and kept at 4 °C prior to use.

## **2.4 Sub-Chronic Toxicity Studies**

A total of twenty (20) albino rats were randomly distributed into five (5) groups: A, B, C, D and E ( $n = 4$ ). Animals in groups B, C, D and E were fed with equivalent volume of 600, 1200, 1800 and 2400 mg/kg body weight of ethanol crude extract of *Cola nitida* by oral intubation for a period of 28 days, while a control group A received equivalent volume of distilled water. After the 28 days period of administration, the animals were fasted overnight after which they were anaesthetized in chloroform and blood samples collected via cardiac puncture for biochemical analyses and desired organs were also harvested and fixed in 10% normal saline for histological analysis.

## **2.5 Serum Biochemical Parameters Determination**

Serum enzymes; alanine aminotransferase (ALT), aspartate aminotransferase (AST) and alkaline phosphatase (ALP) were determined by the method of Duncan et al.[17] using enzyme kits prepared by Randox Laboratories Ltd, UK. The total bilirubin and conjugated bilirubin concentrations were determined as described by Balistreri and Shaw, [18]. The unconjugated bilirubin concentration was calculated as the difference between total and conjugated bilirubin. The total protein was measured using biuret reaction Lanzatol et al. [19], while albumin levels were measured by spectrophotometric estimation by (Sigma Diagnostics, UK).

## **2.6 Tissue Processing for Histopathology**

### **2.6.1 Collection of Tissues**

Histopathological examination of tissues/organs started with surgery of the abdominal portion of the albino rats. The tissues/organs of interest were removed from the body of the test animals following their anesthetization with chloroform. The tissues/organs were then fixed using 10% formyl saline to prevent decay prior to the histopathological examination.

### **2.6.2 Gross Examination**

Tissues were fixed in formaldehyde before gross examination was conducted, which consists of specimen description and placement of parts into a small plastic fixative cassette which holds the tissue while it's being processed unto a paraffin block.

### **2.6.3 Tissue Processing**

The tissues were processed after being prepared into a thin microscopic section using paraffin. Tissues embedded in paraffin were sectioned into 3 to 10 microns, usually 6-8 routinely. The main steps in this process were dehydration and clearing. Wet fixed tissues (in aqueous solutions) were dehydrated. This was done with a series of alcohols with increasing concentrations; say 70% to 95% to 100%. The cassettes containing the tissues allowed the reagents to get in contact freely with the tissues. Clearing followed which involved the removal of de-hydrants. The clearing agent used was xylene. The tissues were impregnated with paraffin wax at temperature between 54-60°C for a period of 4 hours. This was done to remove the clearing agent and moisten the tissues. Finally, the impregnated tissues were placed in a mould with their labels and then fresh melted paraffin wax was poured in it and allowed to settle and solidified. Once the block had cooled sufficiently to form a surface skin, it was immersed in ice water to cool rapidly. After the block was completely cooled, it was cut

into individual blocks. Finally, blocking was conducted which allows the tissues to be chopped into small sections using a microtome for microscopic examination.

#### **2.6.4 Staining**

The tissues were viewed under the light microscope in section after staining with pigment dye. The cellular components of the tissues to be examined was revealed. Prior to staining, tissues sections were first de-paraffinised by running them through xylene or substitute alcohols as no staining can be done on tissues containing paraffin. The staining process makes use of a variety of dyes chosen for their ability to stain various cellular components of tissue. The tissues were stained using haematoxylin and eosin (H and E). Haematoxylin was used to stain the nuclei blue, while eosin stains the cytoplasm and the extracellular connective tissue matrix pink.

#### **2.7 Statistical Analysis**

Data was analyzed using Graph Pad software (San Diego, U.S.A) and one-way analysis of variance (ANOVA) was conducted. Differences in mean  $\pm$  standard deviation (SD) were statistically significant at a  $P$  value of  $\leq 0.05$ .

### **3. RESULTS AND DISCUSSION**

The study examined sub-chronic toxicity of ethanol extract of *Cola nitida* on body weight, Liver Function parameters as well as its histological effects on the stomach mucosa of Albino rats. Following oral administration of the ethanol extract of *Cola nitida* for 28 days, a progressive increase in body weight gain within the group in animals treated with different sub-chronic doses was noted shown in Table 1 from first week to fourth week, which may indicate that the extract has no effect on the feeds utilization ratio of the rats. A significant reduction in body weight gain was associated with toxic effect of some chemical compounds (anti-nutrients) in the extract which may result in complex formation with some vital nutrients thereby reducing their body absorption and utilization in the treated rats [20, 21]. This was contrary to our result that show body weight gain ( $P < 0.05$ ) within treated groups from week one to week four, Table 1. A slight increase in body weight gain by ethanol extract of *Cola nitida* may be attributed to enhanced lipogenesis, decreased thermogenesis, lipolysis and fat oxidation [22, 23]. Also, could be related to an increase in body water retention, which interfere with kidney function, thought, we did not investigate that, nephrotoxicity may be implicated [16].

The study also shows a gradual increase in serum enzyme activities; liver enzymes of animals in the experimental groups treated with the extract as compared to the control group. The findings suggest that the extract at doses (600-2400mg/kg), may have an adverse effect on the liver enzymes. From the result, serum aspartate transaminase enzyme (AST) showed the most significant increase with increased dosage presented in Table 2. Repeated treatments with *Cola nitida* extract significantly increased the level of serum AST and alanine amino transaminase (ALT), this corroborated with the submission by Adedapo et al. [24]. These enzymes serve as useful biochemical markers in the identification of liver diseases such as necrosis and inflammation of the liver cells [25]. ALT is largely concentrated in the liver, however, show significant presence in other peripheral tissues like; skeletal muscles and kidney but is more liver specific than AST [26, 27]. In chronic liver diseases such as cirrhosis, ALT has shown to be released more than AST [28]. These enzymes play an important role in protein and amino acid metabolism in different tissues of the body, and are shown to be affected in diseases or tissue injuries which lead to their

release into the blood stream in high concentrations [29]. Increase in serum Alkaline Phosphatase (ALP) as indicated in Table 2, may be considered as an indicator of cholestasis, which could result from cellular hepatic canaliculi obstruction associated with inflammation [30]. Studies by Salahdeen et al. [14] reported an increase in AST and ALT activity in rats treated with ethanol extract of *Cola nitida* which corroborated well with our result and additionally, studies by Emmanuel et al. [16] also reported an increase in the activity of these enzymes in rats fed with methanol extract of *Cola nitida*.

**Table 1.** Effect of sub-chronic administration of crude ethanol extract of *C. nitida* on the body weights of albino rats.

Group	Initial Weight	Weeks			
		1	2	3	4
Control	119.25±10.44	122.00±9.56	125.25±9.07	131.25±8.90	135.25±9.30
600mg/kg	131.25±2.22	135.25±2.50	138.75±3.09	142.25±2.90	147.25±2.36
1200mg/kg	137.50±2.52	140.25±2.22	144.00±2.94	150.00±1.80	154.50±1.29
1800mg/kg	150.00±8.72	155.67±13.32	159.67±15.04	164.33±13.60	166.00±13.00
2400mg/kg	171.67±6.51	175.33±6.11	179.00±7.91	183.67±9.10	187.00±8.72

\* Values are expressed as mean ± standard deviation of rats treated for 28 days.

**Table 2.** Effect of crude ethanol extract of *C. nitida* on liver marker enzymes in albino rats.

Group	AST (U/L)	ALT (U/L)	ALP (IU/L)
Control	16.97±6.58	20.11±4.39	2.335±0.840
600mg/kg	31.23±9.39*	26.45±4.08	4.448±3.990
1200mg/kg	40.44±12.24*	28.26±5.06*	7.990±2.895*
1800mg/kg	44.59±8.69*	26.46±1.22	7.070±2.210*
2400mg/kg	36.30±13.18*	33.66±7.94*	5.487±1.279*

\* Values are represented as mean ± standard deviation; \*ANOVA indicated  $P = .05$ ; values are significantly ( $P = .05$ ) different from the respective control. AST – Aspartate Aminotransferase, ALT – Alanine Aminotransferase, ALP – Alkaline Phosphatase

Serum Proteins levels have shown no significant increase in concentration in experimental animals except at doses of 1800 and 2400mg/kg where Total Protein and Globulin levels show an increase in concentration in test animals as compared to the control group as in Table 3. A decrease in total protein, albumin and globulin level may be associated with liver dysfunction, malnutrition, malabsorption, diarrhea and nephrosis [31, 32]. An increase in total protein and globulin as reported here could be associated with capability of the hepatocytes to synthesize protein under these concentrations [33].

**Table 3.** Serum proteins (g/dl) level of rats treated with crude extract of *C. nitida* for 28 days

Group	TP	ALB	GLB
Control	12.795±1.369	7.378±0.339	5.418±1.416
600mg/kg	12.790±1.230	7.325±1.251	5.465±0.998
1200mg/kg	12.456±1.105	7.068±0.314	5.390±0.981
1800mg/kg	15.613±1.734*	7.307±0.521	8.307±1.438*
2400mg/kg	15.463±3.731*	7.770±1.300	7.693±3.063*

\*Values are expressed as mean  $\pm$  standard deviation of rats treated for 28 days with ANOVA indicating no significant difference in values as compared to the control. TP – Total Protein, ALB – Albumin, GLB - Globulin

Serum Bilirubin levels; total, direct and unconjugated showed a significant increase followed an increased dosage in a dose-dependent pattern of the extract. Serum total bilirubin showed significant ( $P = .05$ ) increase in concentration at doses above 600mg/kg with direct bilirubin showing a significant increase ( $P = .05$ ) at the dose of 2400mg/kg as presented in Table 4. Elevation of total bilirubin which results from decreased uptake and conjugation of bilirubin by the liver is caused by liver cell dysfunction, while increased levels of direct or conjugated bilirubin is due to decreased secretion from the liver or obstruction of the bile ducts [37].

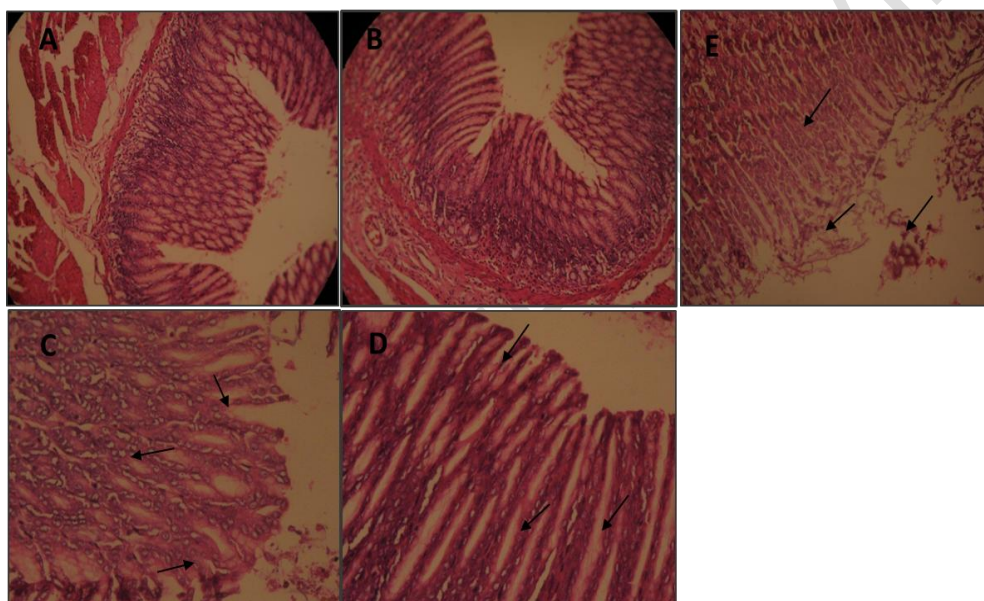
**Table 4.** Serum Bilirubin (mg/dL) levels of rats treated with crude extract of *C. nitida* for 28 days

Group	TB	DB	UB
Control	2.514±0.647	1.717±0.545	0.797±0.471
600mg/kg	4.552±1.420	2.088±1.595	2.464±1.333*
1200mg/kg	6.005±0.749*	4.756±1.756*	1.249±1.085
1800mg/kg	6.242±1.324*	4.612±2.035*	1.649±1.094*
2400mg/kg	8.190±1.550*	6.154±0.645*	2.036±2.150*

Values are expressed as mean  $\pm$  standard deviation; ANOVA indicated \* = significantly different from control ( $P = .05$ ). TB – Total Bilirubin, DB – Direct Bilirubin, UB – Unconjugated Bilirubin.

Histological examination of sections of the stomach from the control group (Fig. 1A) showed better organized epithelium and well preserved mucosa compared to those of the third to fifth experimental groups. Necrotized surface epithelium, degeneration of the gastric mucosa and destruction of glandular elements (Figures C - E) observed in the experimental groups may be due to the high content of N-nitroso compounds found in *Cola nitida*. This may also be responsible for the aggravation of stomach ulcer earlier reported [8, 34]. For instance, Ibu *et al.* [8] discouraged the use of *Cola nitida* by ulcer patient due to its caffeine and its tannin content. Tannins, found in many plants, are substances that can irritate the stomach [35]. The observed gastric lesion was believed to be pronounced due to increased dosage of the extract as those administered with lower doses showed little to no gastric distortion (Fig. 1, B - D). These affirmed earlier report that *Cola nitida* should be used with caution and should

not be taken over long period [8]. Other constituents of *Cola nitida* include theobromine, d-catechin, l-epicatechin, kolatin, kolanin, glucose, starch, fatty matter, tannins, anthocyanin pigment, betaine and protein [34]. *Cola nitida* may not be toxic if mildly used [35]; reports however showed that in Nigeria, where the chewing of cola nuts is very common, there is a high occurrence of oral and gastrointestinal cancers, which may be due to this practice. The destruction of the glandular elements (characterized by many apoptotic bodies) in our present study was concomitant with the destruction of the cytoplasm of the parietal and zymogenic cells thus leading to the discharge of their contents into the gastric lumen thereby increasing the gastric acid content. This may be one of the mechanism by which *Cola nitida* brings about the ulceration of the gastric mucosa observed in this present investigation as well as previous works. These observations conform to earlier reports that kola nuts have fat-burning properties and stimulate the secretion of gastric juices [8, 36]. The gastric juices, so indiscriminately discharged, are capable of digesting the surface epithelium if not put under control [8]. *C. nitida* is widely consumed by quite majority and still in use as an alternative medicine; this may be mainly due to its caffeine content and antidepressant properties [8, 34 & 36].



**Fig. 1. Effect of different doses of Ethanol extract of *Cola nitida* (A = control, B = 600, C = 1200, D = 1800 and E = 2400 mg/kg body weight) on Stomach Epithelial lining of Albino Rats. (A)** Section of the stomach of control rats showing normal mucosa, sub-mucosa and muscularis propria. The cells lining the mucosal gland appear within normal limit **(B)** Section of the stomach showing the four layers in the gastrointestinal lining. **Note** the well organized and preserved mucosa **(C)** Section of the stomach of animal treated with 1200mg/kg body weight of extract showing gradually eroded epithelium. Note arrow marks. **(D)** Section of the stomach of animal group treated with 1800mg/kg body weight of extract showing eroded epithelium. Note the vacuolations in the mucosa (arrows) **(E)** Section of the stomach of animal group treated with 2400mg/kg body weight of the extract showing eroded, necrotized epithelium and vacuolated mucosa. Note the dispersal in the epithelial lining of the stomach **(Magnification: x400).**

#### 4. CONCLUSION

It can be concluded from the result of the study that sub-chronic administration of ethanol extract of *Cola nitida* causes an increase in liver marker enzymes, total protein, bilirubin and unconjugated bilirubin, and affect the gastric mucosa epithelia lining. Therefore, further

studies including developmental and genetic toxicity need to be recommended for the complete elucidation of the potential effects of *Cola nitida*.

#### COMPETING INTERESTS DISCLAIMER:

Authors have declared that no competing interests exist. The products used for this research are commonly and predominantly use products in our area of research and country. There is absolutely no conflict of interest between the authors and producers of the products because we do not intend to use these products as an avenue for any litigation but for the advancement of knowledge. Also, the research was not funded by the producing company rather it was funded by personal efforts of the authors.

#### REFERENCES

1. WHO. Traditional medicine and modern health care: Progress report by the direct general. Document No A44/10, 2005. World Health Organization, Geneva.
2. Iwu MM. African Medicinal Plants in the search for new drugs based on ethnobotanical, Ciba Foundation Symposium. 1994;185: 116-125.
3. Amdur MO., Doull J, and Klaassen CD (eds) Casarett and Doull's Toxicology – The Basic Science of Poisons. 4<sup>th</sup> Edition, Pergamon Press, New York, U.S.A. 1991;12-24, 804-809, 974.
4. Evans WC. Trease and Evans Pharmacognosy. 14<sup>th</sup> Edn., Saunders, London, 1999;5-7, 119-130, 438-440, 488-491.
5. Yakubu MT, Adebayo OJ, Egwim EC, and Owoyele BV. Increased Liver Alkaline Phosphatase and Aminotransferase activities following administration of ethanolic extract of *Khaya senegalensis* stem bark to rats. Biokemistri, 2005;17:27-32.
6. Russel TA. The Kolanut of West Africa. World Crops 1955;7:221-225.
7. Esimone CO, Adikwu MU, Nworu CS, Okoye FBC, and Odimegwu DC. Adaptogenic potentials of *Camellia sinensis* leaves, *Garcinia kola* and *Kola nitida* seeds. Science Research Essays. 2007;2 (7): 232-237.
8. Ibu JO, Iyama AC, Ijije CT, Ishmael D, Ibeshi M, Nwokediuko S. The effect of *cola acuminata* and *cola nitida* on gastric acid secretion. Scand J. Gastroenterol Suppl. 1986;124: 39-45.
9. Eteng MU, Eyong EU, Akpanyong EO, Agiang MA, and Aremu CY. Recent Advances in caffeine and theobromine toxicities: A review. Plant Food for Human Nutrition. 1997;51, 231 – 243.
10. Scotto G, Maillard C, Vion – Dury J, Balansard G, Jadot G. Behavioural effects resulting from subchronic treatment of rats with extract of fresh stabilized cola seeds. Pharmacol. Biochem. Behav. 1987; 26:841-845.
11. Chukwu LU, Odiete WO, and Briggs LS. Basal Metabolic Responses and Rhythmic Activity of Mammalian Hearts to Aqueous Kola nut Extracts. Afri. J. Biotechnol. 2006;5 (5): 484-486.
12. Salahdeen HM, Alada ARA. Effects of caffeine and ethanolic extract of kolanut on glucose uptake in the canine hindlimb at rest and during contraction. Niger. J. Physiol. Sci. 2009;24:33-45.



13. Salahdeen HM, Omoaghe AO, Isehunwa GO, Murtala BA, Alada ARA. Effects of chronic administration of ethanolic extract of kolanut (*Cola nitida*) and caffeine on vascular function. *Afr. J. Med. Sci.* 2014;43:17-27.
14. Salahdeen HM, Omoaghe AO, Isehunwa GO, Murtala BA, Alada AR. Gas chromatography mass spectrometry (GC-MS) analysis of ethanolic extracts of kolanut (*Cola nitida*) (vent) and its toxicity in rats. *Journal of Medicinal Plant Research.* 2015;9(3):56-70. DOI: 10.5897/JMPR2014.5711
15. Ikegwonu FI, Aire TA, Ogwuegbu SO. Effect of kola-nut extract administration on the liver, kidney, brain, testis and some serum constituents of the rats. *J. Appl. Toxicol.* 1981;1:292-294.
16. Emmanuel EU, Ebhohon SO, Adanma OC, Edith OC, Florence ON, Chioma N, Roberts UI, Ndukaku OY. Acute toxicity of methanol extract of *Cola nitida* treatment on antioxidant capacity, hepatic and Renal functions in wistar rats. *Int. J. Biochem. Res. & Rev.* 2016; 13(4): 1-6. DOI: 10.9734/IJBCRR/2016/28593
17. Duncan JR, Prasse KW, Mahaffey EA. *Veterinary Laboratory Medicine (Clinical Pathology)*, 3rd Ed. Iowa State University Press, America. 1994;94-98.
18. Balistreri WR, Shaw LM. Liver function. In: *Fundamental of Clinical Chemistry*, Tietz NW (Ed). 3rd Ed, W.B. Saunders Company, Philadelphia. 1987;729-761.
19. Lanzatot PM, Barahona VM, Manuel IS, Manuel F, Cassidy R. Hematologic, protein electrophoresis, biochemistry and cholinesterase values of free-living black stork nestlings (*Ciconia nigra*) *J. Wildlife Dis.* 2005;41:379-386.
20. Zheng G, Sayama K, Okubo T. Anti-obesity effects of three major components of green tea, catechins, caffeine and theanine in mice. *In Vivo* 2004;18:55-62.
21. Lopez-Garcia E, Van Dam RM, Rajpathak S, Willett WC, Manson JE, Hu FB. Changes in caffeine intake and long term weight change in men and women. *Am. J. Clin. Nutr.* 2006;83:674-680.
22. Greenberg JA, Axen KV, Schnoll R. Coffee, tea and diabetes: the role of weight loss and caffeine. *Int. J. Obes.* 2005;29:1121-1129.
23. Conway KJ, Orr R, Stannard SR. Effect of a divided caffeine dose on endurance cycling performance, postexercise urinary caffeine concentration, and plasma paraxanthine. *J. Appl. Physiol.* 2003;94:1557-1562.
24. Adedapo AA, Abatan MO, Olorunsogo OO. Effects of some plants of the spurge family on haematological and biochemical parameters in rats. *Vet. Arch.* 2007;77(1):29-38.
25. Tilkain SM, Conover MB, and Tilkain AG. *Clinical implications of laboratory tests*; C.V. Mosby Company; St. Louis, Toronto. London; 1979;3-44; 117-132: 154-159.
26. Kaplan MM. Serum alkaline phosphatase – another piece is added to the puzzle. *Hepatology* 1986;6:526.
27. Etuk EU, Muhammad AA. Safety evaluations of aqueous stem bark extract of *Lophira lanceolata* in Sprague dawley rats. *Int. J. Res. Pharm. Sci.* 2010;1:28-33.
28. Whitby LG, Smith AF, and Becket GJ. *Lecture Notes on Clinical Chemistry* Fourth Edition; Blackwell Scientific Publications; Oxford, London, Edinburgh, Boston, Melbourne; 1989;38-178.
29. Kuzminkaya UA, Bersan LV. The effects of the sodium salt of dichlorophenoxy-acetic acid on the glycolysis. ATPase and transketolase activity of erythrocytes. *J. Farmakol. Toksikol.* 1975;38:102- 104.
30. Birkner E, Grucka-Mamczar E, Zwirska-Korczala K, Zalejska-Fiolka J, Stawiarska-Pieta B, Kasperczyk S, Kasperczyk A. Influence of sodium fluoride and caffeine on the kidney function and free-radical processes in that organ in adult rats. *Biol. Trace Elem. Res.* 2006;112:169- 47.
31. Shin MO, Yoon S, and Moon JO. The proanthocyanidins inhibit dimethylnitrosamineinduced liver damage in rats. *Arch Pharm Res.* 2010;33:167-173.

32. Yousef MI, Omar SA, El-Guendi MI, and Abdelmegid LA. Potential protective effects of quercetin and curcumin on paracetamol-induced histological changes, oxidative stress, impaired liver and kidney functions and haematotoxicity in rat. *Food Chem Toxicol.* 2010;48:3246-32461.
33. Omobowale TO, Oyagbemi AA, Abiola JO, Azeez IO, Adedokun RAM, Nottidge HO. Effect of chronic administration of methanol extract of *Moringa oleifera* on some Biochemical indices in female wistar rats. *Niger. J. Physiol. Sci.* 2014; 107-111.
34. Newall C. Anderson LA, Phillipson JD. *Herbal Medicines: A Guide for Health-Care Professionals.* London, England: Pharmaceutical Press. 1996;84.
35. Blumenthal M. *The Complete German Commission E Monographs, Therapeutic Guide to Herbal Medicines.* Boston, Mass: Integrative Medicine Communications. 1998;113–114.
36. Chioma AA, Uchenna BU, Ogachi N. Effect of ethanol extract of *Pyrenacantha staudtii* leaves on carbontetrachloride induced hepatotoxicity in rats. *BIOKEMISTRI.* 2008; 20(1): 17-22.