

# Cardiac Tamponade during TAVI

## **ABSTRACT:**

Transcatheter aortic valve implantation (TAVI) is a new minimally invasive procedure for symptomatic patients with severe aortic stenosis and surgical high-risk.

Although numerous technical improvements have been implemented to simplify the procedure, reduce the incidence of complications, and be compatible with or even superior to the conventional surgical aortic valve replacement (SAVR), temporary pacing by using a right ventricular lead remains mandatory to ensure transient hypotension and low cardiac output while performing predilation of the aortic annulus and accurately position and deploy the valve. Temporary pacing is also crucial as a backup pacing device if complete atrioventricular block develops after TAVI. Implanting a temporary pacing wire requires additional venous vascular access and a pacing lead, both of which may generate complications.

Cardiac tamponade during TAVI is a rare complication. We present the case of a cardiac tamponade during TAVI probably due to right ventricular perforation associated with pacing. We report some measures to avoid such complications and improve the TAVI procedure.

## **INTRODUCTION:**

Transcatheter aortic valve implantation (TAVI) is a new approach for the treatment of severe aortic stenosis (1,2). It has become a widely accepted treatment strategy for patients with severe aortic stenosis who are not eligible for surgical valve replacement because of their high-risk profiles (3).

This report presents the successful treatment course of a patient who developed cardiac tamponade during the temporary pacing for TAVI.

## **Presentation of case:**

An 85-year-old woman with a history of breast cancer, pulmonary embolism and hypertension was admitted to our department for acute heart failure. Her symptoms included chest discomfort and orthopnea with NYHA functional class III. Chest radiography revealed normal cardiac silhouette with marked calcification over the aortic annulus. Her ECG showed sinus rhythm, narrow QRS complex and electric signs of LV hypertrophy (Figure 1). Her transthoracic echocardiography showed severe aortic stenosis: AVA= 0,6 cm<sup>2</sup>; Mean Gd= 46mmHg ; Vmax= 4,34m/s (Figure 2). The logistic EuroSCORE and the STS score predicted respectively a risk of mortality of 6.21 % and 8.54%. The decision of the heart team was TAVI because of the patient's advanced age and high surgical risk.

During bilateral common femoral artery cannulation with ProGlide vascular closure devices (Abbott Vascular Devices, CA, USA), a temporary pacing wire (Pacel bipolar pacing catheter, St. Jude Medical, MN, USA) was inserted in the right ventricular wall via the right femoral vein by making an ultrasound-guided puncture. A 26-mm self-expandable valve (CoreValve EVOLUT R, Medtronic) was deployed under rapid pacing at a rate of 140 beats/min (Figure 3). Angiographic control showed a significant aortic regurgitation due to an inferior suboptimal deployment of the valve. Post-dilation using a 22 mm balloon under rapid pacing at 140 bpm was performed (Figure 4).

After the deployment of the valve, the patient's hemodynamic status crashed dramatically. A transthoracic echocardiography was performed showing a major pericardial effusion with compression of the right ventricular wall. Considering cardiac tamponade, emergency pericardiocentesis was performed. Approximately 460 ml of blood was aspirated immediately, and a drainage tube was placed in the pericardial cavity. The patient's hemodynamic status stabilized and her blood pressure quickly became normal. The cause of cardiac tamponade was attributable to tearing and perforation of the right ventricular wall while placing the temporary pacing lead. Conservative treatment was performed, and the patient had an uneventful recovery course thereafter. Her control TTE showed TAVI valve: Vmax 1.9 m/sec, mean gradient 8 mm Hg and no pericardial effusion. Four days later, she was discharged after the drainage tube was removed under improved functional status.

## **DISCUSSION:**

The emergence of TAVI provides a feasible, low-risk alternative for frail and older patients who are considered poor candidates for surgery. The placement of a temporary pacing wire is considered a routine in most transcatheter valve procedures to facilitate controlled or rapid ventricular pacing during balloon expansion or valve deployment. Compared with SAVR, TAVI has the drawback of higher rates of conduction disturbance and permanent pacemaker implantation (17% in TAVI vs. 5% in SAVR) (4, 5).

The temporary pacing wire is typically kept in place after TAVI and may be removed several days later if no subsequent conduction disturbance occurs. Traditionally, many institutions leave the RV pacing wire in situ for 24 hours, especially in patients receiving self-expandable valves, owing to the risk of late complete AVB. This approach is no longer required because of decreased occurrence of AVB associated with the new generation of valves, improved implantation technique, and frequent late (after over 24 hours) AVB development.

Direct LV pacing through stiff guidewire is an alternative to RV pacing. Meier and Rutishauser<sup>12</sup> first reported on the use of guidewires for pacing during cardiac procedures in 1985. They described a LV pacing technique with the 0.035-inch wire used in a series of 10 patients undergoing diagnostic cardiac catheterization. This method was used in several cases of aortic valvuloplasty in both adult and pediatric patients and subsequently neglected. (6,7) Since then, the use of TAVI has rapidly expanded, procedures have been gradually simplified and become safer and less invasive. Meanwhile, this strategy has been reported only in a few publications (8,9,10, 11, 12). A randomized EASY TAVI (Direct Left Ventricular Rapid Pacing via the Valve Delivery Guide-wire in TAVR) trial comparing LV guidewire pacing with conventional RV lead pacing has been recently published (13). The main findings of the trial were that the use of the LV guidewire for rapid ventricular pacing during TAVI with a balloon-expandable valve was safe and effective. It was associated with reduced procedure duration, fluoroscopy time, and cost compared with the use of

conventional RV lead pacing. The EASY TAVI trial included only a highly selected group of patients undergoing balloon-expandable TAVI procedures.

Safely performed implantation of the temporary pacing wire is the best means of avoiding perforation of the ventricular wall during TAVI. According to previously published reports, right ventricle (RV) perforation may be completely avoided by pacing the septum rather than the apex or free wall of the RV (14,15). The ideal pacing position over the septum of the right ventricular outflow tract should be confirmed to eliminate the risk by real-time transesophageal echocardiography or fluoroscopy during the procedure (16). An excessively long pacing lead under tension should also be avoided because it may generate additional force leading to perforation (17,18).

Measures to avoid such complications as a learning point:

Nonsystematic predilation

Dilatation with balloon not requiring pacing

Pacing the septum rather than the apex or free wall of the RV

Partial inflation of the balloon-tipped pacing lead

Pacing through a left ventricular super-stiff wire

## **CONCLUSION:**

Careful monitoring of every detail during the perioperative period is key for substantially improving TAVI outcomes and avoid possible perioperative complications.

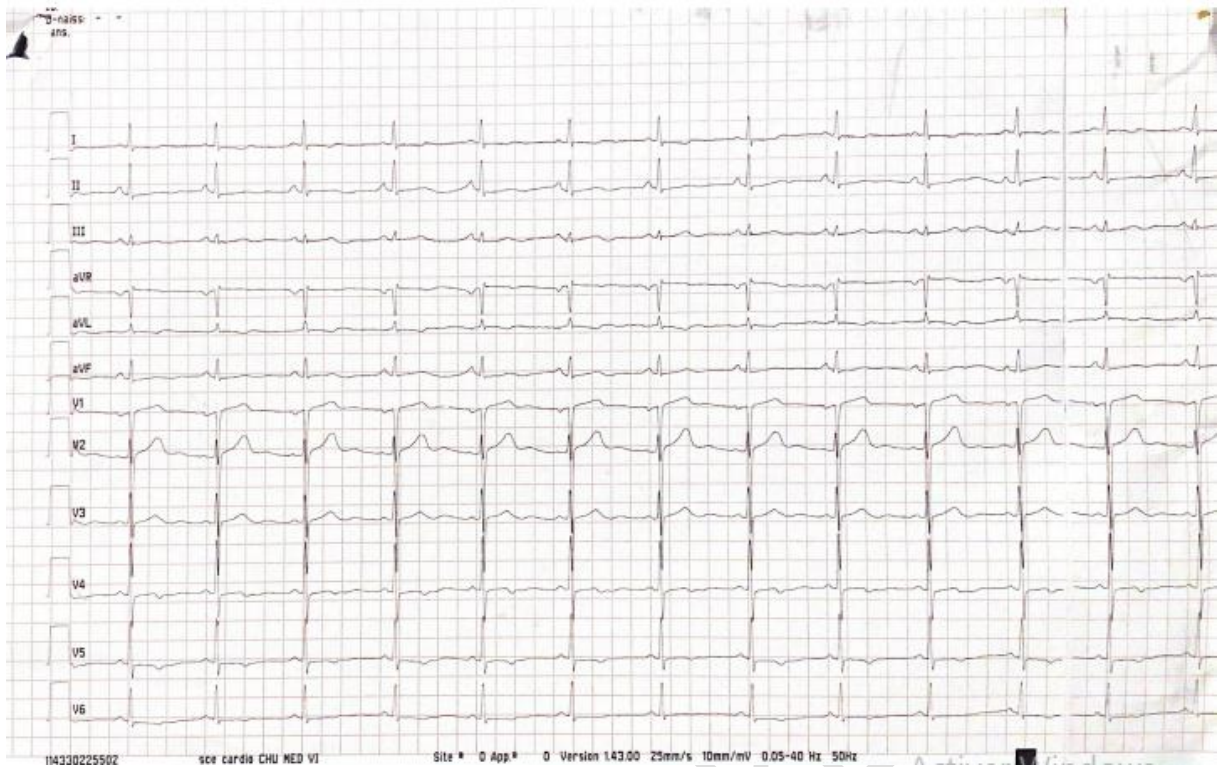## **COMPETING INTERESTS DISCLAIMER:**

Authors have declared that no competing interests exist. The products used for this research are commonly and predominantly use products in our area of research and country. There is absolutely no conflict of interest between the authors and producers of the products because we do not intend to use these products as an avenue for any litigation but for the advancement of knowledge. Also, the research was not funded by the producing company rather it was funded by personal efforts of the authors.

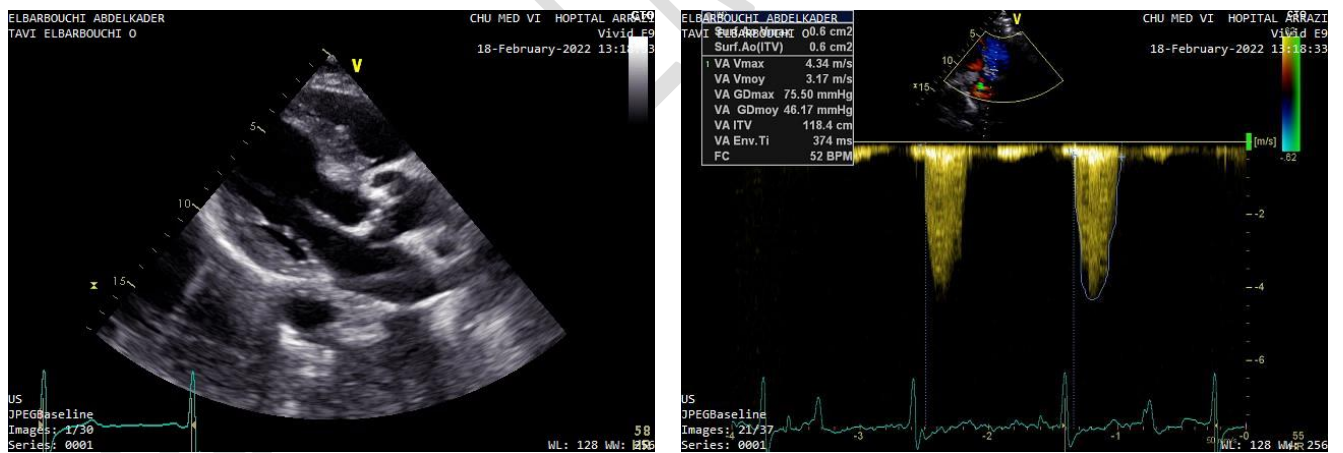
## **REFERENCES**

1. Ross J Jr., Braunwald E. Aortic stenosis. *Circulation* 1968;38:61–7.
2. Bonow RO, Carabello BA, Chatterjee K, et al. 2008 focused update incorporated into the ACC/AHA 2006 guidelines for the management of patients with valvular heart disease: a report of the American College of Cardiology/American Heart Association Task Force on Practice Guidelines (Writing Committee to revise the 1998 guidelines for the management of patients with valvular heart disease). Endorsed by the Society of Cardiovascular Anesthesiologists, Society for Cardiovascular Angiography and Interventions, and Society of Thoracic Surgeons. *J Am Coll Cardiol* 2008;52:e1–142.

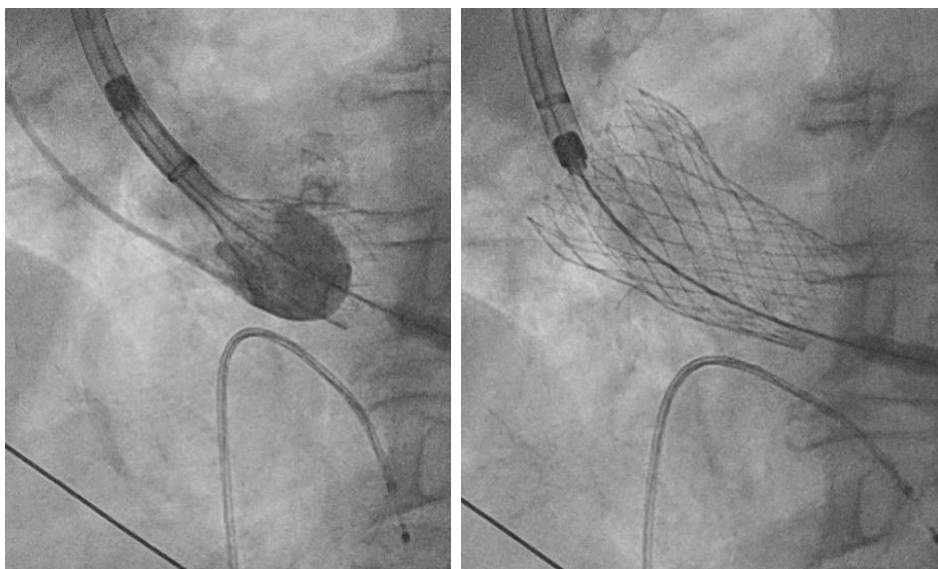
3. Baumgartner H, Falk V, Bax JJ, et al. 2017 ESC/EACTS Guidelines for the management of valvular heart disease. *Eur Heart J*. 2017;38:2739–2791.
4. Siontis GC, Juni P, Pilgrim T, et al. Predictors of permanent pacemaker implantation in patients with severe aortic stenosis undergoing TAVR: a meta-analysis. *J Am Coll Cardiol*. 2014;64:129–140.
5. Husser O, Pellegrini C, Kessler T, et al. Predictors of permanent pacemaker implantations and new-onset conduction abnormalities with the SAPIEN 3 balloon-expandable transcatheter heart valve. *JACC Cardiovasc Interv*. 2016;9:244–254.
6. Karagöz T, Aypar E, Erdoğan I, et al. Congenital aortic stenosis: a novel technique for ventricular pacing during valvuloplasty. *Catheter Cardiovasc Interv*. 2008; 72: 527-530.
7. Navarini S, Pfammatter JP, Meier B. Left ventricular guidewire pacing to simplify aortic balloon valvuloplasty. *Catheter Cardiovasc Interv*. 2008; 73: 426-427.
8. Ertugrul I, Karagoz T, Celiker A, et al. The impact of rapid left ventricular pacing during pediatric aortic valvuloplasty on postprocedural aortic insufficiency. *Congenit Heart Dis*. 2016; 11: 584-588
9. Faurie B, Abdellaoui M, Wautot F, et al. Rapid pacing using the left ventricular guidewire: Reviving an old technique to simplify BAV and TAVI procedures. *Catheter Cardiovasc Interv*. 2016; 88: 988-993.
10. Krishnan S, Daniels D, McCabe JM. Novel bipolar preshaped left ventricular pacing wire for transcatheter aortic valve replacement. *Catheter Cardiovasc Interv*. 2018; 92: 1015-1017
11. Díaz de la Llera LS, Cubero Gómez JM, Casquero Domínguez S, et al. Guidewire-driven left ventricular pacing during transcatheter aortic valve implantation. *Rev Española Cardiol*. 2018; 71: 869-871.
12. Guérios ÊE, Wenaweser P, Meier B. Left ventricular guidewire pacing for transcatheter aortic valve implantation. *Catheter Cardiovasc Interv*. 2013; 82: 919-921.
13. Faurie B, Souteyrand G, Staat P, et al. Left ventricular rapid pacing via the valve delivery guidewire in transcatheter aortic valve implantation. *JACC Cardiovasc Interv*. 2019; 12: 2449-2459.
14. Lau EW, Shannon HJ, McKavanagh P. Delayed cardiac perforation by defibrillator lead placed in the right ventricular outflow tract resulting in massive pericardial effusion. *Pacing Clin Electrophysiol*. 2008;31:1646–1649.
15. Laborderie J, Barandon L, Ploux S, et al. Management of subacute and delayed right ventricular perforation with a pacing or an implantable cardioverter-defibrillator lead. *Am J Cardiol*. 2008;102:1352–1355.
16. Hahn RT, Kodali S, Tuzcu EM, et al. Echocardiographic imaging of procedural complications during balloon-expandable transcatheter aortic valve replacement. *JACC Cardiovasc Imaging*. 2015;8:288–318.
17. Maziarz A, Zabek A, Malecka B, et al. Cardiac chambers perforation by pacemaker and cardioverter-defibrillator leads. Own experience in diagnosis, treatment and preventive methods. *Kardiol Pol*. 2012;70:508–510
18. Sterlinski M, Przybylski A, Maciag A, et al. Subacute cardiac perforations associated with active fixation leads. *Europace*. 2009;11:206–212.



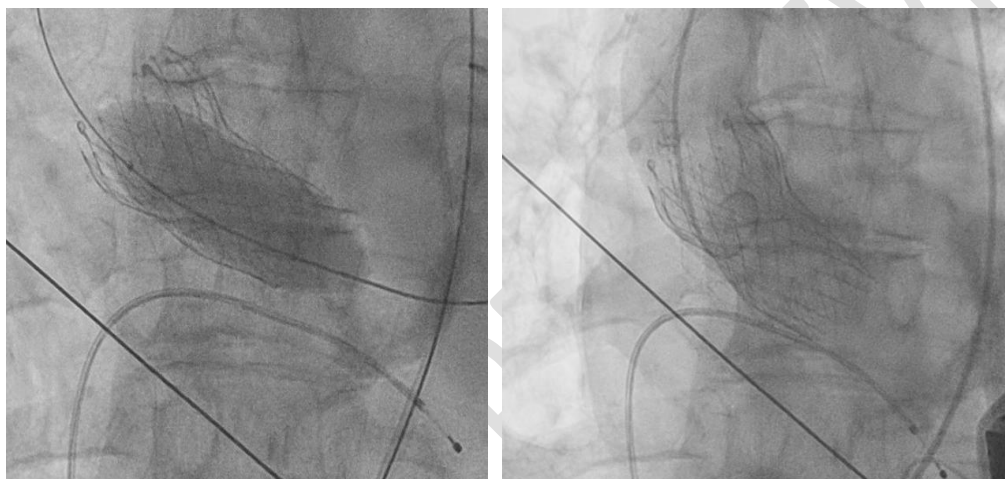
**Figure 1 : Patient ECG**



**Figure 2 : Patient TTE findings showing sever aortic stenosis**



**Figure 3: 26mm self-expandable valve deployment**



**Figure 4: Post-dilatation of the valve with a 22mm balloon**