

### **Evaluation of Immediate Reconstruction with Lipofilling Following Breast Conserving Surgery for Early Breast Cancer**

#### **Abstract**

**Background:** Early-stage breast cancer is defined as disease confined to the breast with or without regional lymph node involvement, and the absence of distant metastatic disease. In Breast-conserving surgery (BCS), only the tumor (lumpectomy) or maximally the quadrant where the tumor located is removed.

**Aim of the Work:** to evaluate the cosmetic outcome and oncologic safety of immediate lipofilling in cases of early breast cancer eligible for breast conserving surgery.

**Methods:** This prospective study was conducted on 40 patients presented with early breast cancer at the Surgical Oncology Unit, General Surgery Department, Tanta University Hospitals. All patients underwent breast conserving surgery by wide local excision of the tumor with free resection margins. Immediate lipofilling was performed by variable volumes of processed fat according to the volumes of the resultant resection defects. The patients were followed up clinically after 15 days, 3 months postoperatively to detect the early and late complications. After 6 months, mammography with complementary ultrasonography were performed to evaluate the graft and detect any complication. FNAC was done to reach the precise diagnosis of any radiological abnormality and exclude any local recurrence. The aesthetic outcome was evaluated objectively and subjectively after 6 months by a scoring system of five items: Asymmetry, breast shape, nipple, skin, wound (ABNSW Score)

**Results:** The average volume of resection defects was 24.4 cc. The average volume of the grafted fat was 49.7 cc. Fifteen days postoperatively, 28 cases had normal skin, four cases had small hematoma, four cases developed mild cellulitis, and four cases had superficial wound infection. After three months, 38 cases had normal overlying skin and two case still had mild wound infection that improved by treatment. After six months, mammography with complementary ultrasonography revealed architectural distortion in 18 cases, calcified hematoma in 14 cases, oil cyst in 4 cases, and chronic abscess in 4 cases. By FNAC, sixteen cases (40%) had giant cell reaction, ten cases (25%) had chronic inflammation, fat necrosis was diagnosed in 8 cases (20%), normal breast tissue was detected in 4 cases (10%). No local recurrence was recorded in any case. Fortunately, 38 cases had good to excellent results by the scoring system ABNSW with the mean total score was 13.2.

**Conclusion:** Breast conserving surgery with immediate lipofilling offers superior cosmetic outcomes than traditional reconstructive techniques.

**Keywords:** Breast conservation surgery, Lipofilling, ABNSW score.

## **Introduction:**

Early-stage breast cancer is defined as disease confined to the breast with or without regional lymph node involvement, and the absence of distant metastatic disease. This is based on the fact that early-stage breast cancer is potentially curable, while patients with distant metastatic disease are not <sup>(1)</sup>.

In Breast-conserving surgery (BCS), only the tumor (lumpectomy) or maximally the quadrant where the tumor located is removed. BCS represents nowadays around 75 % of procedures in breast oncologic surgery, due to its aesthetic results, and patient's satisfaction <sup>(2)</sup>. Some recent investigators reported that the survival outcomes from BCS and adjuvant therapy could be better than mastectomy <sup>(3,4)</sup>.

Oncoplastic Surgery (OPS) is based on two techniques: the first is the volume displacement procedures in which combined resection with one of different breast-reshaping techniques; the second is the volume replacement procedures in which the volume of excised breast tissue is replaced with autologous tissue or implants <sup>(5)</sup>.

Lipofilling (Coleman's technique), also known as autologous fat mini grafting (AFG)/transfer), has been widely used to improve poor cosmetic outcomes in selected patients after BCS <sup>(6)</sup>.

AFG involves harvesting the patient's own subcutaneous fat, from distant sites, and injecting this tissue to the resection defect. There are several advantages to this procedure; as minimal donor site morbidity and, it avoids cosmetic disturbances resulting from the implants. Also, it avoids the complex flap procedures. AFG can rejuvenate breast skin which antagonizes the effects of aging and radiotherapy <sup>(7)</sup>.

However, there are some disadvantages of this procedure as the injected fat into a loose and poorly vascularized space puts it at risk of necrosis. Necrotic fat can initiate an inflammatory reaction resulting in fibrosis, cyst formation, calcification or local infection <sup>(8)</sup>.

Oncological safety is an important point in this work. The recurrence rate in patients reconstructed with autologous fat grafts after BCS was not significantly different from the recurrence rate of the control BCS patients <sup>(9)</sup>.

The aim of this study was evaluation of the cosmetic outcome and oncologic safety of immediate lipofilling with Breast Conservative Surgery in early breast cancer patients.

This prospective study was done on 40 patients aged from 35 to 55 years presented with early breast cancer at the Surgical Oncology Unit, General Surgery Department, Tanta University Hospitals during the period from February 2020 to February 2021.

### **Inclusion criteria**

Patients with T1 or T2 breast cancer with clinically negative axillary lymph nodes at the physical exam and preoperative image staging.

Well-motivated patient of average body mass index willing to have oncoplastic surgery.

### **Exclusion criteria**

Patients with bilateral, multifocal or multicentric tumors.

Patients with stage III and IV breast cancer.

Patients with recurrent breast cancer.

Patients with a history of steroid dependent collagen disease as scleroderma and systemic lupus erythematosus.

## **Methods:**

### **Preoperative work up includes:**

All Patients will be subjected to the following:

Written informed consent after detailed description of the procedure before entry to the study. The consent form approved by the Medical Ethical Committee of Tanta University. Full history taking with considerable emphasis on age of the patient, menstrual history, obstetric history, family history, and history of previous surgery.

General examination with great affords to exclude presence of distant metastasis.

Local examination of both breasts and axillary lymph nodes.

Radiological investigations that include: Bilateral mammography with complementary ultrasonography.

Metastatic work-up that includes chest X-ray, pelvi-abdominal ultrasound, chest computerized tomography (CT) if needed, and bone scan.

Routine laboratory investigations that include complete blood count (CBC), liver and kidney function tests.

Histological confirmation of breast cancer by Fine Needle Aspiration Cytology (FNAC) and/or Tru-cut needle biopsy.

Digital photographs of their breasts pre- and post-operatively every 15 days, 3 months, 6 months.

#### **Surgical technique:**

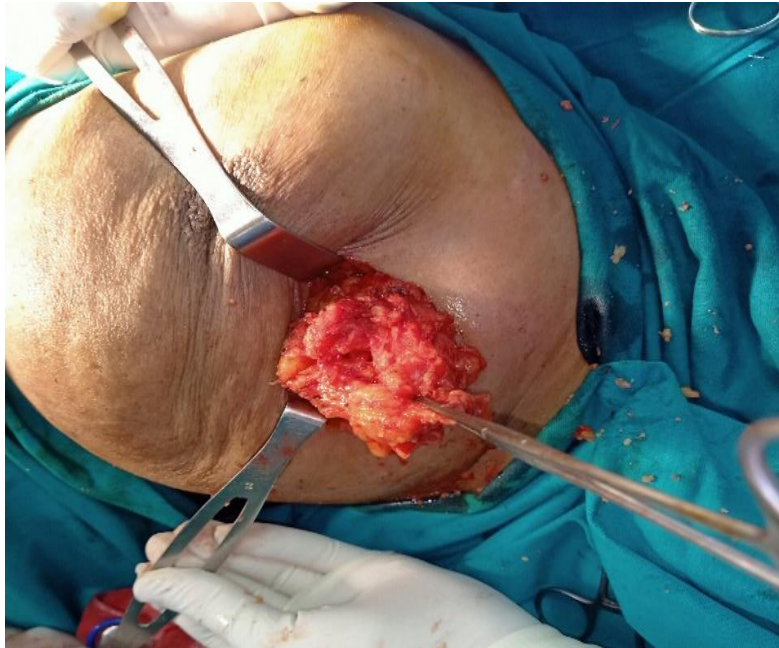**The procedure includes two main steps:**

##### **Excision of the tumor by breast conserving surgery:**

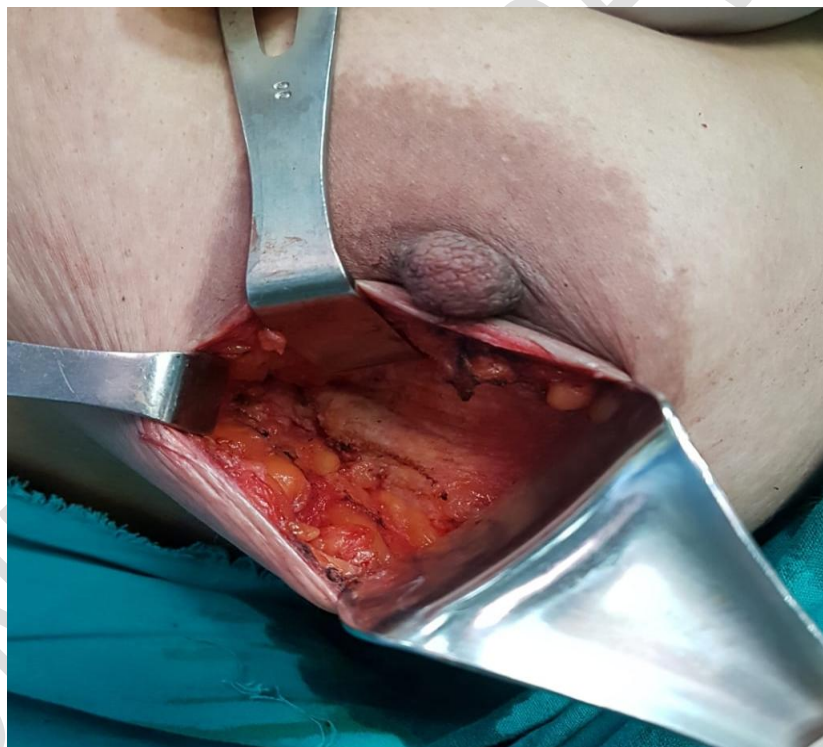The procedure was done under general anesthesia in a supine position, the torso and abdomen were prepared and draped.

All patients underwent B.C.S in the form of wide local excision with the standard safety margin. (which is 2 mm according to American Society of Clinical Oncology)

The free surgical margin was confirmed intra-operatively by histopathological examination of frozen sections or imprint cytology. **(Figure 1)**



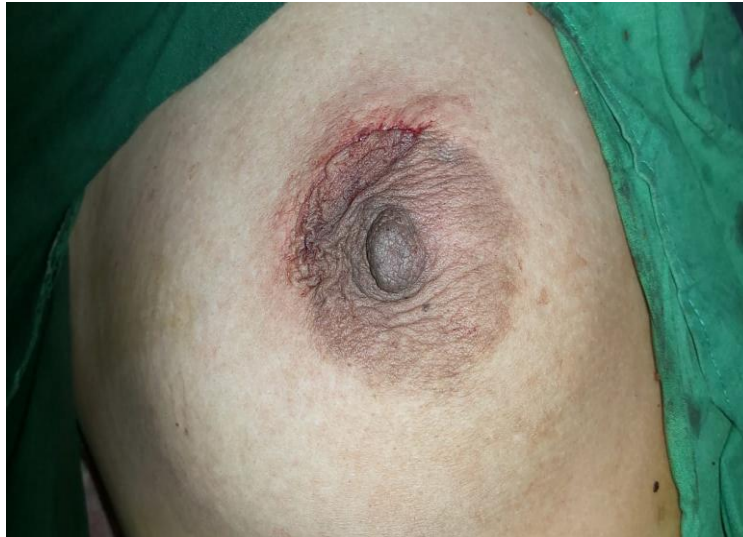***Figure (1): Wide local excision of the tumor with safety margin.***



***Figure (2): The resection defect after wide local excision of the tumor.***

The resection defect created inside the breast after tumor resection was meticulously closed by Vicryl2/0. (**Figure 3**).

Formal axillary lymph node dissection was done (during the infiltration, harvesting and processing phases) from separate incision and drain is inserted in axillary space that closed meticulously by sutures



*Figure (3): Closure of the incision after removal of the tumor.*

## **2- Lipofilling technique:**

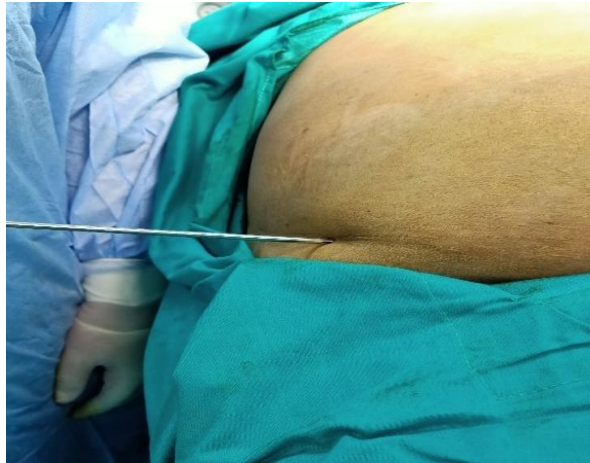### **Infiltration phase:**

The donor site was the abdomen for fat harvesting. A fluid solution containing 0.9% NaCl with epinephrine (1/1000) was injected by a 3 mm blunt-tipped fat harvest cannula causes hydrodissection and hemostasis, thus facilitating the subsequent aspiration, with decreased ecchymosis.

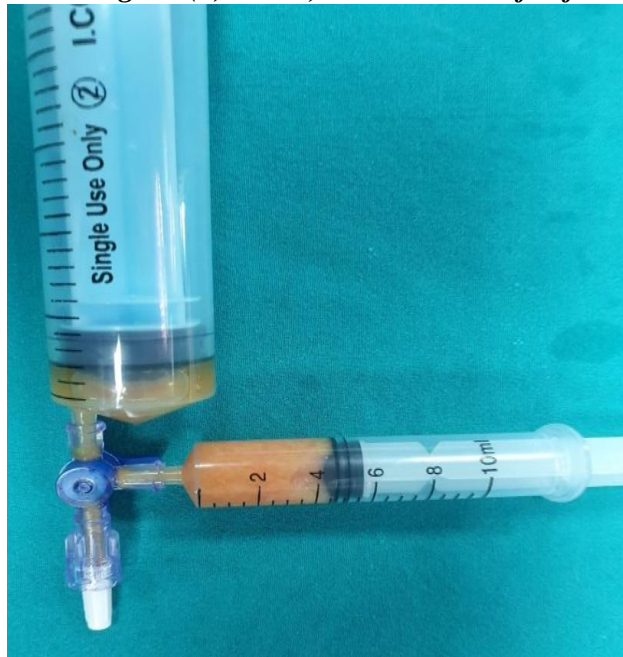### **Liposuction phase:**

Harvesting fat graft tissue by the Coleman's technique using a 3-mm, blunt-edged, 2-hole cannula (GOLD<sup>TM</sup>) connected to a 50-mL syringe. The cannula was pushed through the donor site (through stab wound measure about 5 ml), as the surgeon uses digital manipulation to pull back on the plunger of the syringe and create a gentle negative pressure. Fat is harvested by passing the cannula back and forth through the fat in a fan pattern, avoiding over harvest in any particular location. When filled, the syringe was disconnected from the cannula and evacuated into 10 ml syringe by connector (stop cock) and placed into a centrifuge .(**Figure 4-8**)

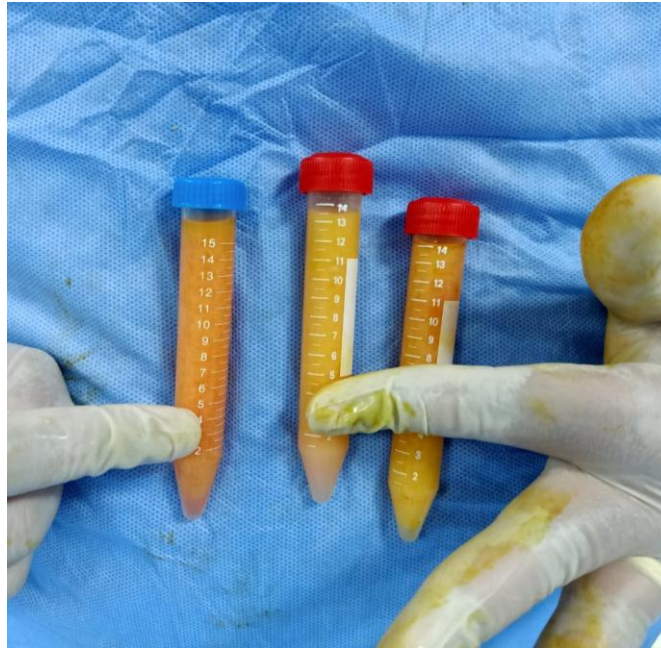



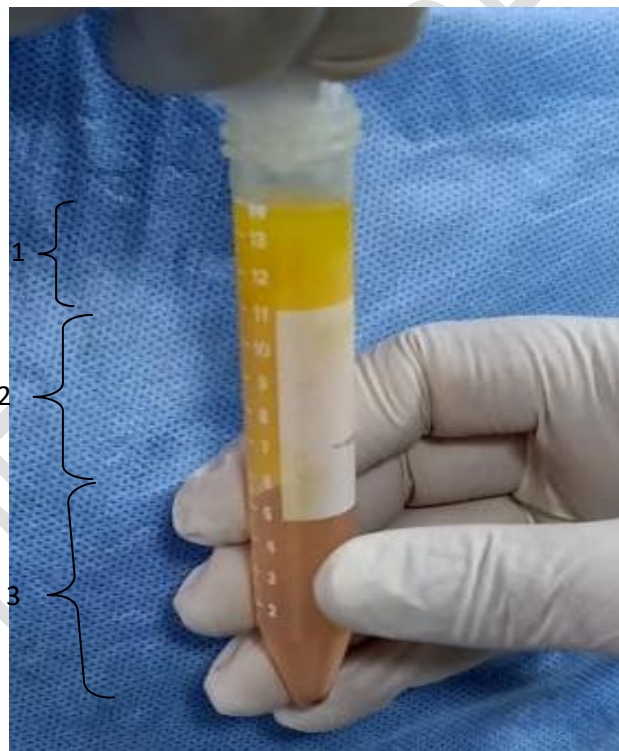
***Figure (4):3 mm, blunt cannula for fat harvesting***



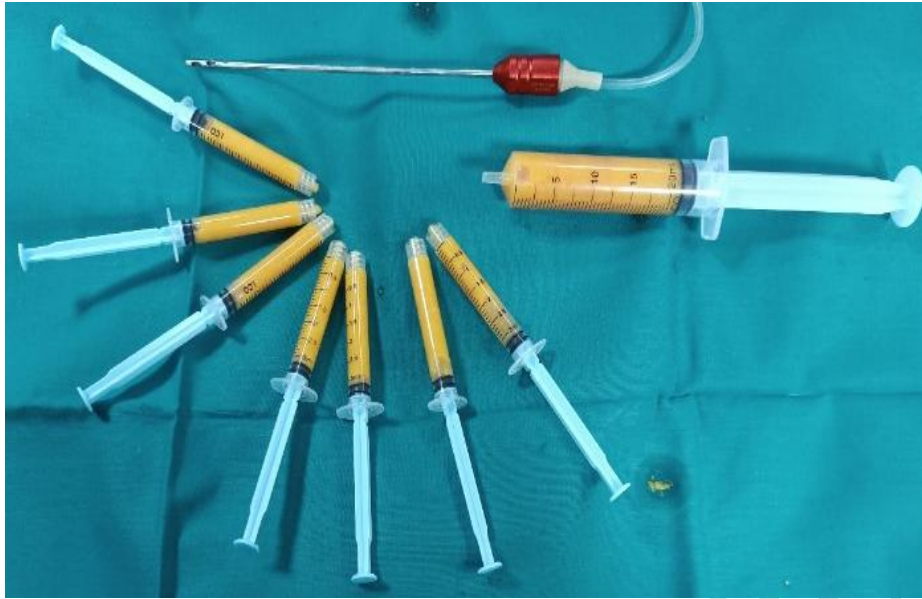***Figure (5):Fat evacuation in 10 ml syringe by connector (stop cock)***



***Figure (6):The harvested fat.***



***Figure (7): Layers of fat after centrifugation (1; oily fluid , 2; fatty tissue, 3; blood and tissue fluid).***



*Figure (8):Centrifuged harvested fat ready for lipoinjection with lipofilling cannula .*

#### **Fat processing:**

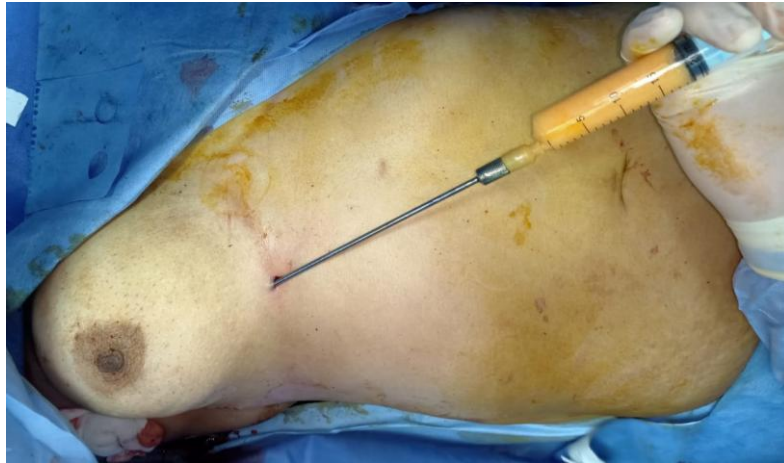As the lipoaspirate contains not only adipocytes but also collagen fibers, blood, and debris. The aspirate was spun at 3000 rpm for 3 min to isolate the fat. After the centrifugation, three layers were observed: **the first layer** included oily fluid, it was poured off; **the second layer** included fatty tissue; this is the layer we used for adipose tissue grafting, and **the third layer** was blood and tissue fluid and was ejected from the base of syringe.

#### **Injection phase:**

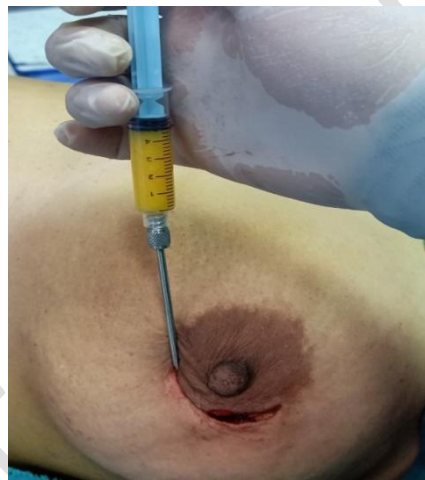Fat was injected using lipofilling cannula 9 ml. The volume of fat we injected was nearly equals twice the volume of resection defect in the breast to compensate for the anticipated resorption. We avoided depositing larger volumes of fat to avoid failure of revascularization, oil cysts, microcalcification or fat necrosis Fat was injected at a slow rate (low shear stress) to gain better fat graft retention than fat injected at a fast rate (high shear stress).

Injection was done from puncture incision in inframammary fold through multiple tunnels technique in fanning manner in the subcutaneous tissue overlying the resected part and around its margins, also injection at sometimes wase done through lateral end of the incision after closure of its subcutaneous tissue. **(Figure 9-11)**

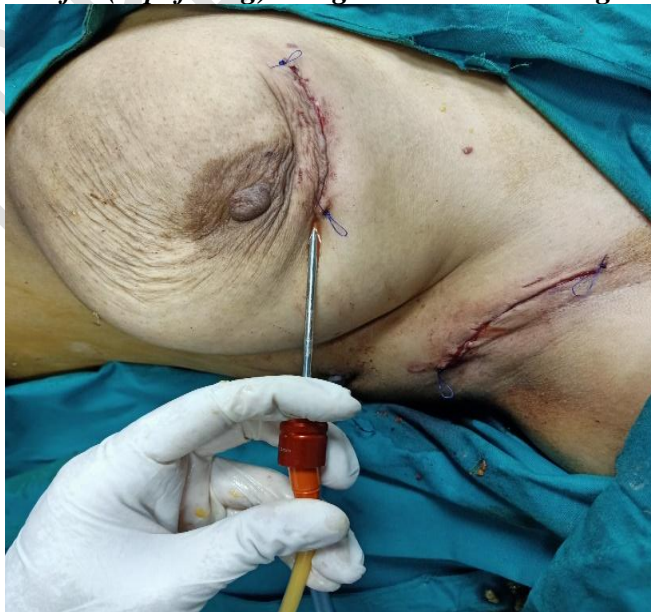



***Figure (9): Injection of the fat (Lipofilling) using 2ml cannula from inframammary fold.***



***Figure (10): Injection of the fat (Lipofilling) using 2ml cannula through the wound .***



***Figure (11): Injection of the fat (Lipofilling)***

The incisions used for infiltration as well as those used for harvesting were closed with 6/0

monofilament. Finally, an elasticized bandage and soft dressings were applied to attain the highest immobilization of the graft and avoid direct compression of the breast, which is vital to ensure its subsistence.

Donor site is closed by an elasticized bandage that removed after two weeks to minimize risk of hematoma.

### Clinical Variables

The clinical variables that were analyzed include: age, weight, body mass index (BMI), tumor location and size, histopathological features, postoperative complications. Other variables were the volume of breast tissue resected, volume of the resection defect, and the volume of fat grafted.

All patients were followed up clinically after 15 days, 3 months.

All cases started radiotherapy one month after operation as long as the wound is clean with no complications.

#### Six months after surgery:

**Mammography with complementary ultrasonography** were done to assess the graft and detect any complication.

**FNAC** was performed in all cases to reach the precise diagnosis of any detected radiological abnormality and to exclude any local recurrence.

**The aesthetic outcome** was evaluated objectively and subjectively by a scoring system of five items (ABNSW). The five items are: asymmetry (A), breast shape (B), nipple shape (N), skin condition (S), and wound scar (W). Each item was scored on a 0 to 3 scale: 0: poor, 1: fair, 2: good, 3: excellent. These 5 item scores were calculated with a maximum ABNSW score of 15. Results were defined as follows: 15; excellent, 11-14; good, 6-10; fair, 5 or less; poor<sup>(10)</sup>.

### Ethical considerations

Written informed consent after detailed description of the procedure before entry to the study. The consent form approved by the Medical Ethical Committee of Tanta University.

### Statistical analysis

Data collected throughout the study were coded, entered and analyzed using Microsoft Excel software. Data were then imported into Statistical Package for the Social Sciences (SPSS version 20.0, Inc., Chicago, Illinois, USA), software for analysis. Qualitative data were represented as number and percentage, while quantitative data were represented by mean; P value was set at < 0.05 for significant results.

### Results:

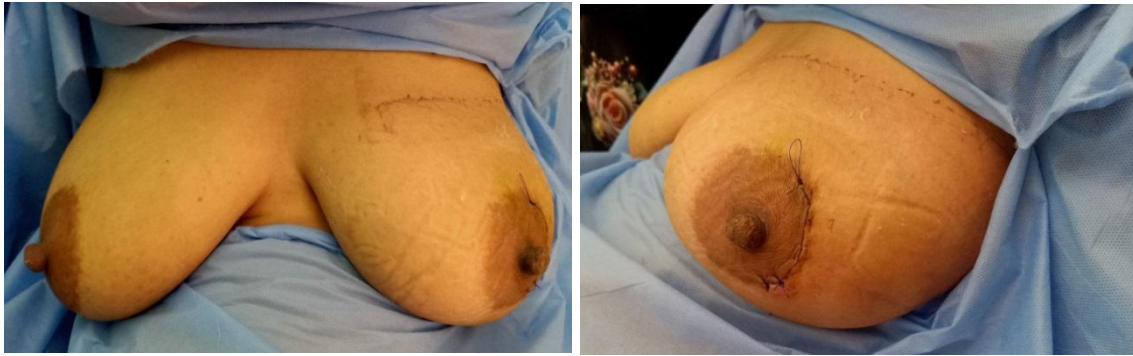All patients subjected to wide local excision (BCS). With intraoperative frozen section examination, all the specimens had a free margin (at least 2mm). Four cases required reexcision once. The volume of fat grafted was doubled as the volume of resected breast tissue. The size of the **resected tumors** ranged from 1.7×2.3 ×3.5 cm<sup>3</sup> to 3 ×3.2×4 cm<sup>3</sup>. The volume of the **resection defects** ranged from 15cc to 36 cc with a mean of 24.4 cc. The volume of **fat grafted** ranged from 30 cc to 70 cc with a mean of 49.7 cc. (Table 1)

**Table (1): Estimation of the fat grafted**

Size of resected tumor	Volume of resection defect	Volume of fat grafted (cc)
------------------------	----------------------------	----------------------------

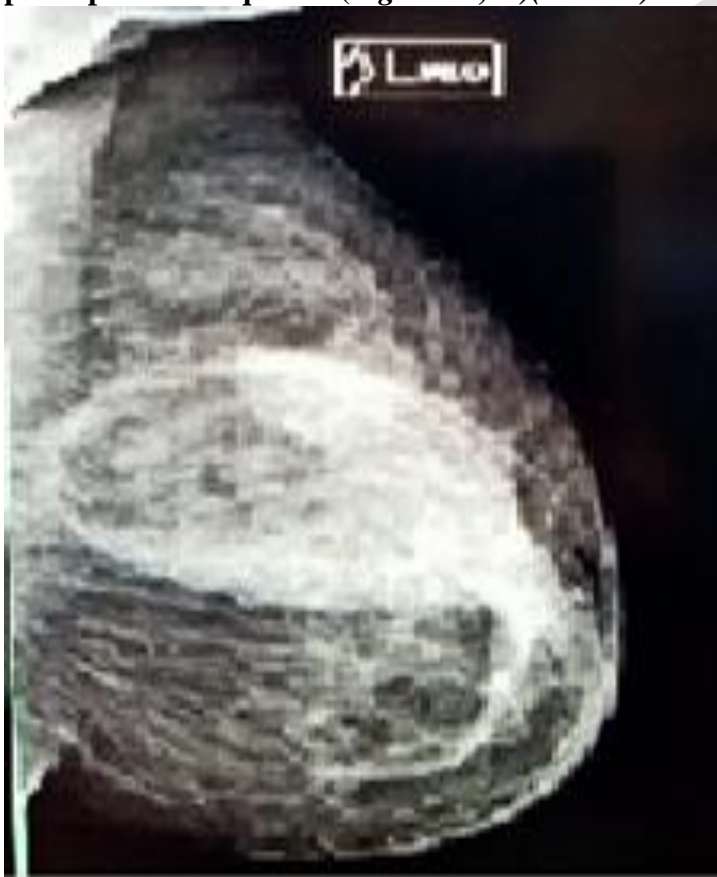(cm)	(cc)	
3 ×3.2×4 cm <sup>3</sup>	36 cc	70 cc
3×3.1×3.6 cm <sup>3</sup>	33 cc	70 cc
2.9×3.3×3.6 cm <sup>3</sup>	34 cc	70 cc
2×2.5×3 cm <sup>3</sup>	15 cc	30 cc
2.2×3×3.2 cm <sup>3</sup>	20 cc	40 cc
2.7×3.2×4 cm <sup>3</sup>	34cc	70 cc
2.3×2.6×3.3 cm <sup>3</sup>	20 cc	40 cc
2.2×3.4×3.7 cm <sup>3</sup>	27cc	50 cc
2.1×2.7×3.4 cm <sup>3</sup>	20cc	40 cc
2.3×2.6×3.3 cm <sup>3</sup>	20 cc	40 cc
2.5 ×2.9×3.5 cm <sup>3</sup>	25 cc	50 cc
2.2×2.9×3.8 cm <sup>3</sup>	25 cc	50 cc
2.7×3.3×3.6 cm <sup>3</sup>	32 cc	60 cc
2.2 ×2.3×2.5 cm <sup>3</sup>	15 cc	30 cc
1.9×2.2×3.6 cm <sup>3</sup>	22 cc	40 cc
2.1× 2.3×3.8 cm <sup>3</sup>	18 cc	40 cc
3.1×3.3×3.6 cm <sup>3</sup>	36 cc	70 cc
2.7 ×3.2× 4.1 cm <sup>3</sup>	35 cc	70 cc
3.1×3.3×3.6 cm <sup>3</sup>	36 cc	70 cc
1.7×2.3 ×3.5 cm <sup>3</sup>	15 cc	30 cc
3.4×2.1×2.7 cm <sup>3</sup>	19 cc	40 cc
1.7×2.5×3.1 cm <sup>3</sup>	15 cc	30 cc
2.1×2.9×3.6 cm <sup>3</sup>	22 cc	50 cc
1.9×2.3×3.9 cm <sup>3</sup>	17 cc	40 cc
3.1×2.7×2.8 cm <sup>3</sup>	25 cc	50 cc
2.6×3.2×3.2 cm <sup>3</sup>	27 cc	60 cc
2.3×3.5×3.6 cm <sup>3</sup>	30 cc	60 cc
2.1×3.1×4.2 cm <sup>3</sup>	28 cc	60 cc
1.7×2.2×4.3 cm <sup>3</sup>	16 cc	30 cc
2.1×2.6×2.7 cm <sup>3</sup>	15 cc	30 cc
2.7×2.4×3.7 cm <sup>3</sup>	25 cc	50 cc
2.2×2.8×3.6 cm <sup>3</sup>	22 cc	50 cc
2.9×3.1×3.1 cm <sup>3</sup>	28 cc	60 cc
3.2×2.2×2.9 cm <sup>3</sup>	22 cc	50 cc
1.8×3.5×3.3 cm <sup>3</sup>	21 cc	40 cc
2.7×2.6×3.8 cm <sup>3</sup>	27 cc	50 cc
1.6×2.8×3.7 cm <sup>3</sup>	17 cc	40 cc
2.4×3.3×3.2 cm <sup>3</sup>	25 cc	50 cc
2.7×2.7×3.6 cm <sup>3</sup>	26 cc	50 cc
3.3×3.1×3.3 cm <sup>3</sup>	34 cc	70 cc
<b>Mean</b>	<b>24.4</b>	<b>49.7 cc</b>

**After 15 days**, 28 cases (70%) had normal overlying skin, without any other complications. On the other hand, 4 cases (10%) had small hematoma at the site of operation, 4 cases (10%) had mild cellulitis, and 4 cases (10%) had superficial wound infection. (**Figure 12**)

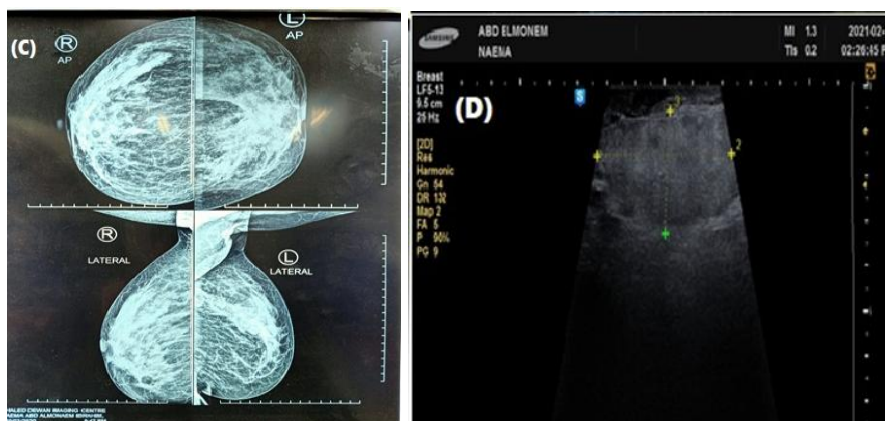


**Figure 12: Early postoperative photo showing normal left breast shape, normal overlying skin, and clean wound with symmetry of both breasts.**

After 6 months, mammography with complementary U/S showed 4 cases (10 %) have cystic lesion with clear content most likely oil cyst. Also, detected small cystic lesion with turbid content likely abscess (chronic) in 4 cases (10 %). Also, fourteen case (35 %) showed well defined area with some calcification most likely calcified hematoma. In addition, eighteen cases (45%) showed ill-defined area of architectural distortion due to post-operative sequelae. (Figure 13,14)(Table 2)



**Figure( 13): Mammographic appearance after 6 months showing postoperative sequelae in the form of fairly defined area of architectural distortion.**



**Figure (14):** Radiological evaluation after 6 months. Mammography (left) demonstrates likely benign findings in the form of architectural distortion, but the ultrasound scanning (right) was performed due to a palpable mass showing areas of fat necrosis with tiny oil cysts.

**Table (2):** Radiologic finding after 6 months of fat grafting.

Mammography with complementary US	No	%
Oil cyst	4	10
Chronic abscess	4	10
Calcified hematoma	14	35
Architectural distortion due to Post-operative sequelae	18	45

The results of FNAC were as follow: sixteen cases (40%) had giant (foreign body) cell reaction, ten cases (25%) had chronic inflammation, fat necrosis was diagnosed in 8 cases (20%), normal breast tissue was detected in 4 cases (10%). Also, two case with a good breast shape and normal skin refused doing FNAC. (Table 3)

**Table (3):** FNAC after 6 months of operation

FNAC after 6 months	No	(%)
Giant cell reaction	16	40
Chronic inflammation	10	25
Fat necrosis	8	20
Normal breast tissue	4	10
Hematoma	2	5

The aesthetic outcome was excellent (ABNSW score=15) in two case, good (ABNSW score = 11-14) in 37 cases, and fair (ABNSW score = 8) in one case. The mean total ABNSW score was 13.2. So, most cases had good to excellent results. (Table 4)

**Table (4):** Cosmetic outcome (ABNSW SCORE) after 6 months individually:

Cases	A (asymmetry)	B (breast shape)	N (nipple)	S (skin)	W (wound)	Maximum
1	2	3	3	3	2	13
2	2	3	3	2	2	12
3	2	2	3	3	3	13



4	3	3	3	3	2	14
5	2	2	3	3	2	12
6	2	2	3	3	3	13
7	1	1	3	2	1	8
8	3	2	3	3	1	12
9	3	3	3	3	3	15
10	2	1	3	3	2	11
11	3	2	3	2	3	13
12	3	3	3	2	3	14
13	3	3	3	3	3	15
14	2	2	3	2	2	11
15	3	3	3	2	3	14
16	3	2	3	3	3	14
17	2	3	3	2	3	13
18	2	2	3	2	2	11
19	3	3	3	3	2	14
20	3	3	3	3	2	14
21	3	3	3	2	3	14
22	2	3	3	3	3	14
23	3	2	3	3	3	14
24	3	3	3	3	2	14
25	2	1	3	3	3	12
26	3	2	3	2	3	13
27	3	3	3	3	2	14
28	3	3	3	2	3	14
29	3	2	3	3	3	14
30	2	3	3	3	2	13
31	2	3	3	2	3	13
32	3	2	3	3	3	14
33	3	3	3	3	2	14
34	3	3	3	2	3	14
35	2	3	3	3	3	14
36	3	2	3	3	2	13
37	3	3	3	2	3	14
38	2	3	3	3	3	14
39	3	2	3	3	3	14
40	2	3	3	3	2	13
Mean:	2.5	2.5	3	2.4	2.5	13.2

0-3 scale (0: poor), (1: fair), (2: good) (3: excellent)

#### Discussion:

All our patients were followed-up clinically after two weeks, after 3 months, and after 6 months postoperatively.

**After 15 days**, 28 cases (70%) had normal overlying skin, no cellulitis or any other complication. On the other hand, 4 cases (10%) had small hematoma at the site of operation, 4 cases (10%) had mild cellulitis, and 4 cases (10%) had superficial wound infection.

After lipofilling, among the common benign **late** postoperative findings are fat necrosis, calcifications, and oil cysts. It is impossible to determine the exact etiology of these findings; however, it likely represents areas of poor graft take. <sup>(11)</sup>

**After Three months**, we found 38 cases (95%) had preserved breast shape without any complications, while the cases that had wound infection, cellulitis and hematoma showed improvement by medical treatment with preserved breast shape.

**After 6 months**, mammography with complementary U/S showed architectural distortion in 18 cases due to post-operative sequelae, seven cases showed calcified hematoma, four cases showed chronic abscess, four cases showed oil cyst.

**In the report of Mann RA et al**, Follow-up ranged from 1 to 99 months (mean 29.5 mo). follow-up mammography for their cases who underwent lipofilling was unremarkable for 8 out of 31 cases (25.8%). Benign-appearing lesions, such as scarring, fat necrosis, or oil cysts were detected in 20 breasts (64.5%). Suspicious lesions were noted in three cases (9.7%); all biopsies were negative for malignancy and revealed a ruptured apocrine cyst, a lipoma, and fat necrosis.<sup>(11)</sup>

In agreement with our study, **Petit et al**<sup>(12)</sup>. They concluded that Lipofilling after breast cancer treatment leads to a low complication rate and does not affect radiologic follow-up after breast-conserving surgery.

Our findings indicate that autologous fat grafting appears to be a safe option for the reconstruction of BCS defects, as evidenced by low surgical and postoperative major complications. In our cases, imaging was able to confirm the normal postsurgical changes, fat necrosis, calcifications, or oil cysts, however, we were eager to exclude any suspicious lesions by biopsy (FNAC) for all patients.

Other report on 2407 patients didn't find any evidence denoting that immediate lipofilling significantly increases the risk of locoregional recurrence when used as part of a procedure after BCS, and considered this method of reconstruction as an oncologically safe procedure in suitable patients with careful oncological follow-up<sup>(13)</sup>.

In a report by **Khan et al.**,<sup>(14)</sup> the results of BCS with immediate lipofilling in 32 women were compared with 39 women who had BCS alone. They found at a median follow-up of 36 months, a significantly better cosmetic outcomes with lipofilling (most  $p < 0.001$ ). Also, no local recurrences were recorded in either group. They concluded that BCS and immediate lipofilling provides superior cosmetic outcomes to standard BCS.

In our study, the aesthetic outcome was evaluated objectively and subjectively by a scoring system of five items (ABNSW). It was excellent (ABNSW score=15) in two case, good (ABNSW score = 11-14) in 37 cases, and fair (ABNSW score = 8) in one case. The mean total ABNSW score was 13.2. So, most our cases had good to excellent results.

In a study conducted by our team performed a traditional breast conserving surgery (batwing mastopexy) using the same scoring system, the excellent results were obtained in 4.3%, the good results were obtained in 78.2%, and the fair results were obtained in 17.3%.<sup>(15)</sup>

Although our results are encouraging, we realized that our study has a number of limitations that should be addressed and taken into consideration. This study included a limited number of patients in a single center, and a limited short follow-up period. Moreover, the incidence of **locoregional recurrence** and patient safety could not be fully assessed. Therefore, our study needs further studies on a larger number of patients and a longer follow-up period to make this technique reproducible. The patients may also need additional rounds of fat grafting in the future.

## References:

1. Coleman MP, Quaresma M, Berrino F, et al. Cancer survival in five continents: a worldwide population-based study (CONCORD). *The Lancet Oncol* 2008; 9(8):730-756.
2. Haloua MH, Krekel NM, Winters HA, et al. A systematic review of oncoplastic breast-conserving surgery: current weaknesses and future prospects. *Ann Surg* 2013; 257:609–662.

3. Abdulkarim BS, Cuartero J, Hanson J, et al. Increased risk of locoregional recurrence for women with T1-2N0 triple-negative breast cancer treated with modified radical mastectomy without adjuvant radiation therapy compared with breast-conserving therapy. *J Clin Oncol* 2011; 29(21):2852-2858.
4. Johns N, and Dixon JM. Should patients with early breast cancer still be offered the choice of breast conserving surgery or mastectomy? *Eur J Surg Oncol* 2016; 42(11):1636-1641.
5. Delay E, Gosset J, Toussoun G, et al., Efficacy of lipomodelling for the management of sequelae of breast cancer conservative treatment. *Ann Chir Plast Aesthet.* 2008; 53(2):153-168.
6. Dixon JM. Breast-conserving surgery: the balance between good cosmesis and local control, in JM Dixon (ed) *A Companion to Specialist Surgical Practice: Breast Surgery*. 5th edition, London: Elsevier, 2014; 51-70.
7. Raposio E, Simonacci F, & Perrotta RE. Adipose-derived stem cells: comparison between two methods of isolation for clinical applications. *Ann Med Surg* 2017; 20: 87-91.
8. Ueberreiter K. A Short History of Transplantation of Autologous Adipose Tissue. In *Autologous fat tissue transfer*. Springer, Cham 2019; 3-4.
9. Castelli J, Figl A, Raoust I, et al. Second conservative radio surgical treatment for ipsilateral breast cancer recurrence. *Cancer Radiother* 2011; 15:130-135.
10. Biazus JV, Stumpf CC, Melo MP, et al. Breast-conserving surgery with immediate autologous fat grafting reconstruction: oncologic outcomes. *Aesthet Plast Surg* 2018; 42(5):1195-1201.
11. Mann RA, Ballard TNS, Brown DL, et al. Autologous fat grafting to lumpectomy defects: complications, imaging, and biopsy rates. *J Surg Res.* 2018; 231:316-322.
12. Petit JY, Lohsiriwat V, Clough KB, et al. The oncologic outcome and immediate surgical complications of lipofilling in breast cancer patients: a multicenter study—Milan-Paris-Lyon experience of 646 lipofilling procedures. *Plast Reconstr Surg* 2011; 128(2):341-346.
13. Losken A, Pinell-White X, Hodges M, et al. Evaluating outcomes after correction of the breast conservation therapy deformity. *Ann Plast Surg* 2015; 74:209-213.
14. Khan LR, Raine CR, Dixon JM. Immediate lipofilling in breast conserving surgery. *Eur J Surg Oncol.* 2017; 43(8):1402-1408.
15. Elghalban M, Ghazaly M, Darwish A, et al. Evaluation of a Single Oncoplastic Technique for Peri-Areolar Upper Quadrants Breast Cancer. *Surg Gastroenterol Oncol* 2021; 26(2):131-137.