

# **Spontaneous rupture and calcification of a neglected double J ureteral stent revealed by stenturia: a case report and review of the literature**

## **Abstrac**

Double J or JJ ureteral catheters are used for various indications. If forgotten or neglected, they can undergo physical changes leading to degradation, calcification or encrustation. We are reporting a case of spontaneous rupture and calcification of a neglected double J ureteral stent revealed by stenuria and managed endoscopically.

**Key words:** double J stent, complication, rupture, endo-urology

## **Introduction**

Ureteral stents are widely used in endo-uological procedures. They can be overlooked or neglected leading to serious complications, including fragmentation or rupture, migration and urosepsis (1). Few studies report spontaneous fragmentation or rupture of double J catheters, and stenturia is an unusual or unknown manifestation. Our objective is to present this rare case with an endo-uological management.

## **Clinical case**

Its about a 31 year- old female patient with a history of endoscopic fragmentation of a right pyelic stone with placement of a protective double-J stent for which she neglected her appointment for stent removal. Seven months later , she began to present irritative lower urinary tract disorders followed by the expulsion of whitish fragments in the urine before her consultation .

The clinical examination showed a conscious and stable patient with a slight right loin pain . The rest of the examination was normal.

The complete blood count(CBC) and renal function test were normal. The cyto- bacteriological examination of urines showed leucocyturia without bacteriuria.

The plain x-ray without preparation of the urinary tree showed three fragments of double J catheter (upper loop, body and lower loop of the JJ) with calcification of one fragment at the vesical level (image 1).

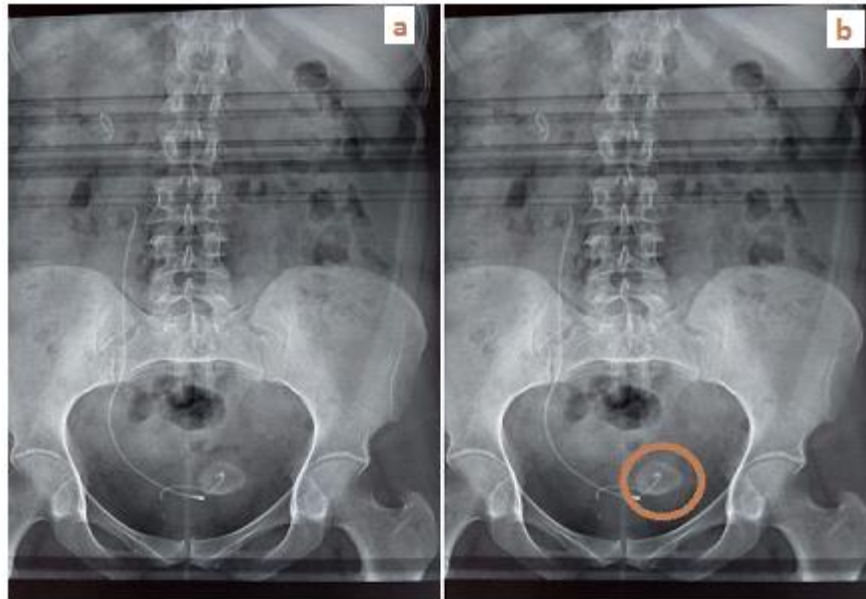


Image 1: double J ureteral stent ruptured into several fragments with calcified distal loop

The management of this condition was endoscopic. This consisted of laser fragmentation of the calcification at the bladder level and removal of the fragments under cysto-ureteroscopy (image 2).



Image 2 : fragments of the double J stent after removal

## Discussion

Double J (JJ) ureteral catheters are widely used in the practice of modern urology . Ideal characteristics include biological inertness, chemical stability in urine, resistance to infection

and encrustation, long-term urine flow, stability, lack of discomfort and cost (2). Double j stents are not free of complications. Stent-related complications are mainly mechanical: stent migration, encrustation, stone formation and fragmentation or rupture (3). We are reporting a case of spontaneous rupture and calcification of a neglected double J ureteral stent revealed by stenturia.

Fragmentation or rupture is a serious complication of forgotten or neglected double J stents. It is caused by loss of tensile strength due to degeneration of the stent polymers and hardening of the stent (4). In the series by El-Faqih et al, the fragmentation rate was 0.3% for a duration longer than 3 months (5). The duration of the double J stent was 7 months in our patient. Kumar et al defined stenturia as ureteral stents fragmented into several pieces that pass into the urine (6). This symptomatology was observed late and was the main reason for consultation.

Stone formation in a remaining stent or fragment is a common complication. It is mainly seen in patients with an increased risk of stone formation and long catheter duration. Dehydration, stent obstruction, urinary tract infection, chronic renal failure may also contribute to stone formation (3).

In case of forgotten or neglected stents, management depends on the type of complication. Removal may be endoscopic or surgical. In some conditions, management may be multi-modal, combining endoscopy and surgery (7). (7). Nephrectomy may be indicated in case of a silent kidney (8). Our approach was completely endoscopic, combining laser cystoureteroscopy with fragmentation and removal of the fragments.

## Conclusion

The omission or negligence of ureteral catheters can lead to serious complications. Although the majority of these complications can be managed by endo-urolgical procedures, prevention should be the only objective. In addition to patient compliance and the investment of the urologist, a reminder system can play an important role.

## References

1. Sen Volkan, Bozkurt Halil Ibrahim, Yonguc Tarık, Aydogdu Ozgu, Yarimoglu Serkan, Degirmenci Tansu et al. Forgotten and fragmented ureteral j stent with stone formation: combined endoscopic management. Int. braz j urol. 2015 June; 41(3):602-603.
2. Beiko DT, Knudsen BE, Watterson JD, Cadieux PA, Reid G, Denstedt JD. Urinary tract biomaterials. J Urol 2004;171:2438-44.
3. Ray RP, Mahapatra RS, Mondal PP, Pal DK. Long-term complications of JJ stent and its management: A 5 years review. Urol Ann. 2015 Jan-Mar;7(1):41-5.

4. Zisman A, Siegel YI, Siegmann A, et al. Spontaneous ureteral stent fragmentation. J Urol. 1995;153:718–721.
5. El-Faqih SR, Shamsuddin AB, Chakrabarti A, Atassi R, Kardar AH, Osman MK, Hussain I: Polyurethane internal ureteral stents in the treatment of stone patients: Morbidity related in indwelling times. J Urol 1991;146:1487.
6. Kumar M, Aron M, Agarwal AK, Gupta NP. Stenturia: An unusual manifestation of spontaneous ureteral stent fragmentation. Urol Int. 1999;62(2):114-6.
7. Mahmood SN, Toffeq HM, Hussen M, Karim A, Jamal C, Said AA, Aziz BO (2018) Endourologic management of a 15-year-old neglected, fragmented, and encrusted ureteral stent, Journal of Endourology Case Reports 4:1, 201–204.
8. Murthy Kusuma V. R., Reddy S. Jayaram, and al. Endourological Management of Forgotten Encrusted Ureteral Stents. Int. braz j urol. 2010 Aug; 36( 4 ): 420-429.