

Couvelaire uterus : a case report

Abstract

Couvelaire uterus is one of associated complication with retroplacental hematoma, due to extensive extravasation of blood into the uterine musculature reaching the serosa. Uterus shows signs of ecchymosis; we report a case of 34 years old women who was admitted to our hospital at 36 weeks of pregnancy in a typical clinical state of retroplacental hematoma complicated by intrauterine fetal death and the laparotomy showed a Couvelaire uterus.

Key words: couvelaire uterus, retroplacental hematoma,

Introduction

Couvelaire uterus or uteroplacental apoplexy is a rare nonfatal condition of severe forms of placental abruption or invasive malplacentaion (placenta accreta) [1] resulting from extravasation of blood into the uterine musculature, the infiltrations may reach the peritoneal cavity [2].

We report a case of couvelaire uterus caused by retroplacental hematoma at 36 weeks of pregnancy

Case presentations

A 34 years old, primiparous woman, with 36 weeks of amenorrhea and no significant medical or chirurgical past, was admitted to our hospital in a typical clinical state of retroplacental hematoma complicated by intrauterine fetal death. The time between the onset of her abdominal and the delivery of the baby was about 6 hours .

On clinical examination, the patient was pale with a heart rate of 100 bpm, a blood pressure 90 mmgh/50 mmgh, presence of albuminuria on the urine dipstick and a vaginal bleeding with uterine hypertonicity with no cervical dilatation. An obstetric ultrasound confirmed the fetal death in utero with presence of retroplacental echogenic image of 8 cm in diameter evoking a retroplacental hematoma.

A blood numeration showed anemia at 7g/dl. A cesarean section was indicated and revealed a dark purple patches with ecchymosis and indurations (Couvelaire uterus)(figure 1), the peritoneal cavity was normal . The hysterotomy revealed a retroplacental hematoma of 700g. The fetus was in a state of apparent death and weighed 2600 g. After pregnancy evacuation the uterus retracted correctly. The patient was transfused during the surgery. The postoperative was simple

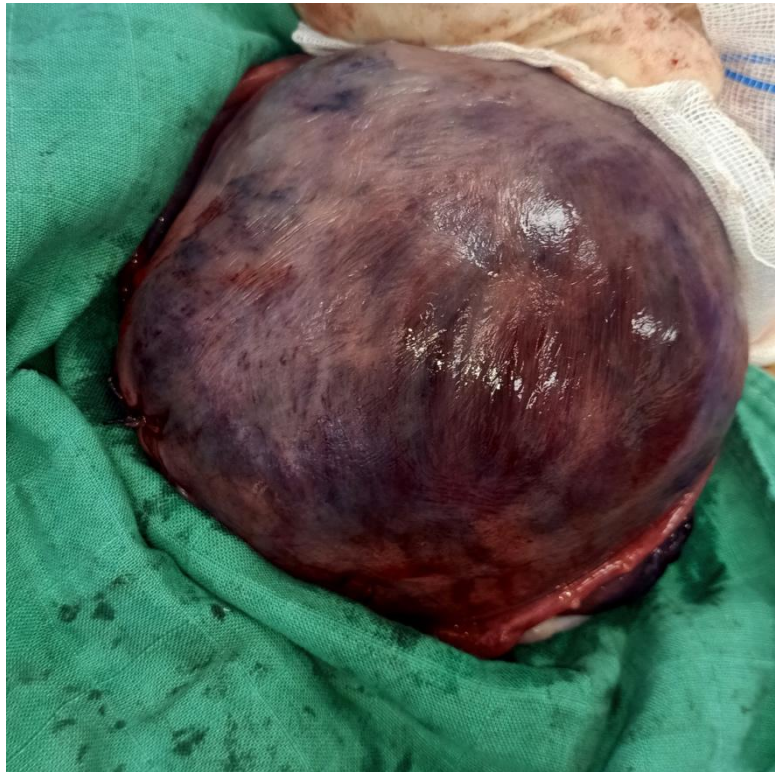


Figure 1: Couvelaire uterus

Discussion:

First description of couvelaire uterus was by Dr Alexandre Couvelaire in 1911. [3]

The incidence of couvelaire uterus is underestimated because it can be demonstrated only by laparotomy. It is estimated to 5% of placental abruption and it occurs during the third trimester in the 0.3% of pregnancies [4]

According to the New Jersey-Placental Abruption study, there is no specific clinical criterion for placental abruption [5] but the most frequent signs is association of vaginal bleeding with uterine hypertonicity as in our case.

Couvelaire uterus is diagnosed by direct visualization of the uterus or by the result of the biopsy: blood between muscle bundles and in the subserosa [4]. the extent of blood extravasation in the myometrium depends on the time of installation of placental abruption[2]. In our case, 6 hours elapsed between the start of the pain and the management of delivery.

The condition often resolves spontaneously, these myometrial bleeds seldom interfere with uterine contractions to cause post-partum hemorrhage, the uterus responds to oxytocin, therefore, couvelaire uterus should be managed conservatively[6-7].

Conclusion

Couvelaireuterus is a rare complication of placental abruption which can lead to maternal and fetal mortality. So it needs an early and adequate management of the underlying pathology.

References :

- 1- CPT Omici N. Uwagbai, MC USA; COL Arthur C. Wittich, MC USA .A 30-Year-Old Female Found to Have a Couvelaire Uterus With Placenta Accreta During Planned Cesarean Delivery MILITARY MEDICINE, 182, 3/4:e1877, 2017
- 2-Yi Jia Lee, Katrina Calvert and Kedar Jape. Couvelaire uterus resulting in haemoperitoneumournal of Surgical Case Reports, 2022;1, 1–3
- 3-Couvelaire A (1912) Deux nouvelles observations d'apoplexie utero-placentaire (hemorrhagies retro-placentaires avec infil- tration sanguine de la pavoï musculaire de l'uterus). Ann GynecolObst 9: 486
- 4-Habek D, Selthofer R, Kulas T. Uteroplacentalapoplexy (Couvelaire syndrome). Wien KlinWochenschr 2008;120:88.
- 5-Nath C, Smulian J, Shen-Schwarz S, Kaminsky L, Ananth C. Placental abruption is associated with histologic evidence of inflammation: the New Jersey-placental abruption study. Am J ObstetGynecol 2006;195:S88.
- 6-Hubbard JL, Hosmer SB. Couvelaire uterus. J Am Osteopath Assoc 1997;97:536–7.
- 7- Ram and Swetha: A case of couvelaire uterus with coagulation dysfunction saved successfullywith SR PPH Suctioncannula. Tropical Journal of Obstetrics and Gynaecology / Volume 37 / Issue 1 / January-April 2020