

Case report

Patent Vitello-intestinal Duct with Umbilical Abscess- A rare case presentation

ABSTRACT

Patent vitellointestinal duct (PVID) presenting with an umbilical abscess is a rare entity. PVID occurs as a result of the failure of regression of the omphalomesenteric duct by the ninth week of the gestational period. At birth, it may present as a bulky umbilical cord, umbilical swelling which may be associated with discharge. We present here a rare case of a three and half-year-old female child presenting with a complaint of large umbilical swelling associated with pain and discharge. On exploratory laparotomy, a completely patent tract joining umbilicus to ileum was found. The tract was excised, and appropriate closure was done. The patient recovered well over a period of two weeks without any complications.

Keywords: Patent vitellointestinal duct, Omphalomesenteric duct, Umbilical abscess, Umbilical discharge

1. INTRODUCTION

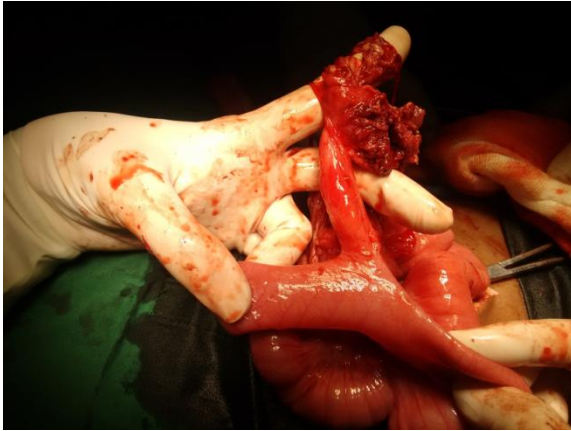
Anomalies like patent vitellointestinal duct, Meckel's diverticulum, vitelline sinus, intestinal fistula, umbilical cyst, or mass may develop due to failure of resorption of the vitellointestinal duct. These conditions may often remain silent or may present as an intra-abdominal complication requiring urgent surgical intervention [1]. A persistent vitellointestinal duct can lead to symptoms like umbilical discharge with sinus, bowel prolapse, obstruction, hemorrhage, fistula, or hernia that occurs in pediatric age groups. It should be noted that bulky umbilical cord in a neonate with or without discharge could be an early sign for the presence of PVID, and a thorough assessment of associated anomalies like exomphalos, gut malrotation, bowel atresia, etc. must be done.

Here we present a rare case of a three and half-year-old female child with a complaint of large umbilical swelling associated with pain and discharge who was diagnosed to have patent vitellointestinal duct with an umbilical abscess.

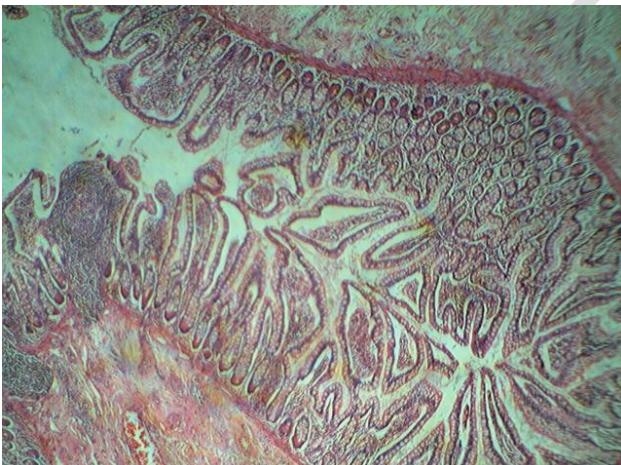
2. CASE REPORT

A three and half-year-old female child was brought to the out-patient clinic with the chief complaint of large abdominal swelling in the umbilical region associated with intermittent fever episodes, redness, and pain in the periumbilical region. Parents reported a history of occasional discharge from the umbilicus since birth. The symptoms aggravated over a period of three weeks when the swelling increased in size significantly for which the parents sought immediate attention and approached us. There was no history of vomiting. Bowel habits were normal. A provisional diagnosis of the patent vitellointestinal duct with umbilical abscess was established and the patient was admitted to the general surgery ward. On examination, a spherical swelling with round margins of size 10 x 7 cm approximately was noted in the umbilical region with tenderness, and increased temperature in the surrounding region. The patient also gave a history of intermittent seropurulent discharge from the umbilicus. The rest of the examination was within normal limits. On investigation,

Hemoglobin was 9.5 gm %, white blood cell counts 22,500/cu.mm, platelet count 1,31,000/uL, random blood sugar 90 mg, Blood Urea 19.10mg %, Creatinine 0.28 mg %, serum sodium 132.10 mEq/L, serum potassium 4.73 mEq/L. An abdominal ultrasound examination suggested the presence of a tubular communication between the umbilicus and intestinal loop below with the presence of collection in the anterior abdominal wall. The patient was posted for exploratory laparotomy under general anesthesia. An abscess collection was noted with a completely patent vitellointestinal duct from the umbilicus above to the antimesenteric border of the ileum below [Figure 1]. The duct was found adhered with the transverse colon and omentum near the umbilicus. The adhesions were separated, and the duct was carefully dissected. The patent vitellointestinal duct was around 10 cm in length, 1.5 cm in diameter with a broad base. Omphalectomy with wedge resection of the ileal end was done and closed transversely in two layers. The post-operative hospital stay was uneventful, and the patient was discharged on the 8th day after satisfactory recovery. Histopathology report confirmed Patent Vitellointestinal duct with an umbilical abscess [Figure 2].



[Figure 1: Completely patent Vitello-Intestinal Duct above attached to ileal loop below.]



[Figure 2: Histopathology of the specimen]

3. DISCUSSION

A vitellointestinal tract contains three structures: the vitelline duct, artery, and vein. The yolk sac is the chief source of nutrition in the early phase of intrauterine life. The vitellointestinal duct (omphalomesenteric duct) is a structure connecting the embryonal yolk sac to the midgut lumen of the developing fetus. With the progression of the gestational period, the duct gets narrow and becomes fibrous usually by the ninth week, obliterates, and gets separated from the intestine ultimately. A failure to regress leads to the patent vitello-intestinal duct at birth, which is commonly connected with the ileum [2].

Clinically it presents with a bulky umbilicus with the discharge of meconium or stools. Serious complications may include bowel prolapse, intestinal obstruction, volvulus, intussusception, or adhesions [3]. The incidence of a persistent duct is less than 2% in the general population. Meckel's diverticulum is the most commonly reported anomaly, whereas complete patency of the duct is rare [4,5]. A thorough physical examination, identification of central dimple, and probing with a catheter may aid the diagnosis of PVID [6]. Maternal hyperthyroidism and its management with antithyroid drugs like carbimazole have been found to be a risk factor for PVID [7]. Vitellointestinal duct as an abscess is a very rare presentation as reported previously in the study by Ali et al [8].

The clinical diagnosis of PVID has to be further established with the help of radiological investigations. Ultrasound of the abdomen performed by expert hands is the first-line diagnostic tool, however, its accuracy is doubtful in cases with associated urachal remnants. CT scan of the abdomen is definitive in such cases. A contrast study may also be useful in selected cases of PVID.

Abdominal exploration, wedge resection of the involved bowel segment with primary closure usually gives a good outcome however some studies have suggested segmental resection with primary anastomosis as the preferred approach due to chances of leftover ectopic mucosa on the native ileum [1]. Although open laparotomy is conventional and well accepted, laparoscopic surgery is currently preferred for uncomplicated persistent vitello-intestinal duct cases resulting in lower morbidity and lesser duration of hospital stay [9,10].

4. CONCLUSION

This case report concludes that timely attention by parents to the clinical signs such as umbilical swelling or discharge in infants and children is of paramount importance in the diagnosis and management of the underlying congenital anomalies like a patent vitellointestinal duct. Negligence at an early stage may lead to serious life-threatening intra-abdominal complications causing increased morbidity and mortality. Though very rare, the patent vitellointestinal duct may also present as an umbilical abscess and must be considered as a differential diagnosis.

CONSENT

All authors declare that 'written informed consent was obtained from the patient (or other approved parties) for publication of this case report and accompanying images.

ETHICAL APPROVAL

As per international standard guidelines, written ethical approval has been collected and preserved by the author(s).

REFERENCES

1. Kadian YS, Verma A, Rattan KN, Kajal P. Vitellointestinal Duct Anomalies in Infancy. J Neonatal Surg. 2016;5(3):30. Published 2016 Jul 3. doi:10.21699/jns.v5i3.351.
2. Sagar J, Kumar V, Shah DK. Meckel's diverticulum: a systematic review. J R Soc Med. 2006 Oct;99(10):501-5. doi: 10.1258/jrsm.99.10.501. Erratum in: J R Soc Med. 2007 Feb;100(2):69. PMID: 17021300; PMCID: PMC1592061.
3. Patel RV, Kumar H, Sinha CK, Patricolo M. Neonatal prolapsed patent vitellointestinal duct. BMJ Case Rep. 2013;2013:bcr2013010221. Published 2013 Jul 10. doi:10.1136/bcr-2013-010221.
4. Rao, P. L. N. G., Mitra, S. K., & Pathak, I. C. (1979). Patent vitello intestinal duct. The Indian Journal of Pediatrics, 46(6), 215-218. doi:10.1007/BF02898231.
5. Vane DW, West KW, Grosfeld JL. Vitelline duct anomalies. Experience with 217 childhood cases. Arch Surg. 1987 May;122(5):542-7. doi: 10.1001/archsurg.1987.01400170048007. PMID: 3495250.
6. Wong, H.Y., Ng, Y.K., Chan, K.W.E. and Lee, K.H. 2018. Patent Vitello-Intestinal Duct: A Misdiagnosis of Persistent Umbilical Granuloma. Journal of Neonatal Surgery. 7, 4 (Oct. 2018), 45. DOI:10.21699/jns.v7i4.779.

7. Kannan L, Mishra S, Agarwal R, Kartikeyan V, Gupta N, Kabra M. Carbimazole embryopathy-bilateral choanal atresia and patent vitello-intestinal duct: a case report and review of literature. *Birth Defects Res A Clin Mol Teratol*. 2008 Sep;82(9):649-51. doi: 10.1002/bdra.20483. PMID: 18671255.
8. Ali A, Jawale AR, Cama J. Vitello-intestinal duct fistula--a rare presentation of a patent vitello-intestinal duct: a case report. *Pac Health Dialog*. 2010 Sep;16(2):67-9. PMID: 21714338.
9. Lassen PM, Harris MJ, Kearse WS Jr, Argueso LR. Laparoscopic management of incidentally noted omphalomesenteric duct remnant. *J Endourol*. 1994 Feb;8(1):49-51. doi: 10.1089/end.1994.8.49. PMID: 8186784.
10. Annaberdyev S, Capizzani T, Plesec T, Moorman M. A rare case presentation of a symptomatic omphalomesenteric cyst in an adult, 24-year-old patient, treated with laparoscopic resection. *J Gastrointest Surg*. 2013 Aug;17(8):1503-6. doi: 10.1007/s11605-013-2207-4. Epub 2013 Apr 23. PMID: 23609141.