

Case report

Large Asymptomatic Mucocele of The Appendix – An Incidental Finding

ABSTRACT

Aim: Mucocele of the appendix is a rare condition. We present here such case of a young female patient who came for annual routine health checkup and was incidentally diagnosed with mucocele of appendix. Presence of mucocele was confirmed on CT scan and then the patient underwent surgery with histopathological examination confirming the simple mucocele of appendix. Patient was under regular post-operative follow-up. She recovered well and the postoperative follow-up period was uneventful.

Presentation of Case: A 36-year-old patient came to our wellness center for routine annual health check-up. She was asymptomatic and was incidentally diagnosed with mucocele of appendix on ultrasound which was confirmed on CT scan. She underwent conventional open appendicectomy for it. The base of appendix was free from any pathology and there was no evidence of lymph node involvement. The appendix was delivered intact and sent for histopathological examination which confirmed the diagnosis. The patient recovered well and post-operative follow-up was uneventful.

Discussion: Mucocele of the appendix is abnormal dilatation of the gland due to accumulation of large amount of mucus. Being a rare entity the mucocele of appendix is often diagnosed on routine appendicectomy specimen or radiological studies done for some other ailments. However, a correct pre-operative diagnosis and selection of appropriate surgery ranging from simple appendicectomy to right hemicolectomy depending on the size, location and lymph node status is vital. Based on histopathological examination they are classified into four different types which has different prognosis and standard follow-up guidelines.

Conclusion: The case report demonstrates the importance of routine annual health check-up and timely diagnosis of mucocele of appendix.

Keywords: Mucocele of appendix, mucinous cystadenoma, mucinous cystadenocarcinoma, incidental mucocele.

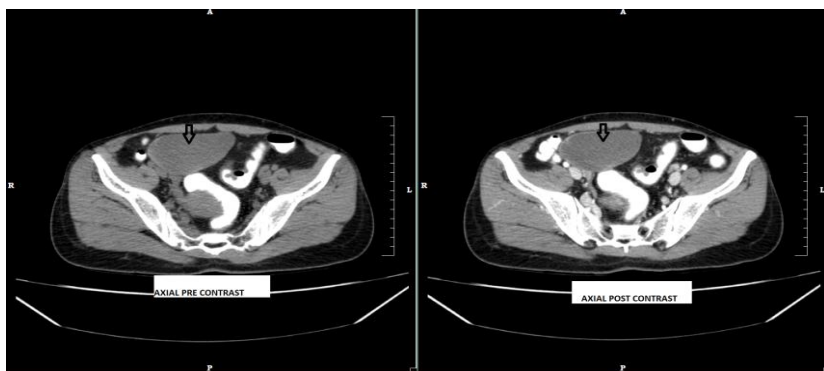
1. INTRODUCTION

Mucocele of the appendix is a rare disease that is characterized by distention of the appendiceal lumen regardless of the process [1]. There is a progressive retrograde dilatation of the vermiform appendix associated with intraluminal accumulation of the mucoid substance. The reported prevalence of mucocele in appendicectomy specimens is 0.2-0.3% [2].

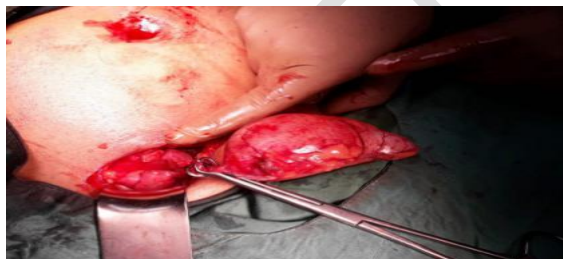They do not have a specific clinical presentation. They sometimes present with vague lower abdominal pain and might be mistaken for acute appendicitis hence they are commonly detected in the pathological specimen of an appendicectomy. Such appendiceal mucinous lesions are generally detected incidentally while evaluating an unrelated complaint [3-5]. An inadequate treatment causes the epithelial cells to escape into the peritoneal cavity developing pseudomyxoma peritonei with a high mortality rate [6].

2. PRESENTATION OF CASE

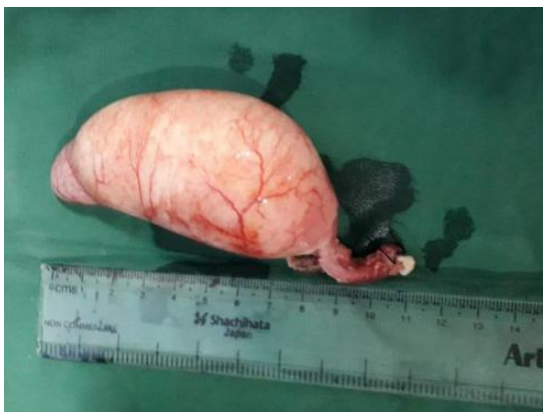A 36-year-old female patient came to the hospital wellness center for a routine annual health check-up. She had no history of abdominal pain, fever, nausea, or vomiting. There were no urinary or bowel complaints. Her ultrasound scan revealed a well-defined cystic lesion of size 9 cm X 5 cm with echogenic material with debris noted in the right iliac fossa suggestive of appendicular mucocoele or a mesenteric cyst and hence the patient was referred to the surgery OPD for further evaluation. Her abdominal examination on inspection and palpation was within normal limits. A contrast-enhanced CT scan of the abdomen and pelvis revealed a dilated appendix of size 5 cm filled with a low-density material suggestive of a mucocoele of the appendix (Figure 1). After thorough work-up and counselling, the patient was posted for an open appendicectomy. The appendix was large and swollen at its tip and body with an inflamed wall without any evidence of perforation (Figure 2). The appendicular dimensions were 9.1 x 4 x 4 cm approximately. The base appeared normal with approximately 2 cm of length free from any swelling (Figure 3). No collection was seen in the peritoneal cavity. There was no evidence of lymphadenopathy. Conventional appendicectomy was performed as the base of the appendix was free from any pathology and the specimen was delivered out intact without rupture. The histopathological examination confirmed the simple mucocoele of the vermiform appendix. The postoperative period was uneventful and the patient was discharged after three days and had been on regular follow-up.



(Figure 1: CT scan image)



(Figure 2: Mucocoele of the appendix as seen during surgery)



(Figure 3: Mucocoele of the appendix delivered out intact)

3. DISCUSSION

Mucocoele of the appendix is characterized by abnormal accumulation of a huge quantity of mucus in the lumen resulting in dilatation of the gland. The appendix is lined by epithelium which has more goblet cells. Thus, a majority of epithelial tumors start as mucocoeles [6]. The incidence of mucocoele of the appendix is only 0.2% to 0.7% hence making it a rare entity [7,8]. Most of these cases are identified on histopathological examination of appendectomy specimens or diagnosed incidentally on radiographical imaging. Pathologically it is classified into four types: a) simple or retention cyst, b) mucosal hyperplasia, c) mucinous cystadenoma which is a dilated appendix filled with mucin lined by atypical mucinous epithelium having minimal dysplastic features, and d) mucinous cystadenocarcinoma which is defined as mucin filled dilated appendix along with the presence of high-grade cell dysplasia and usually stromal invasion beyond the muscularis mucosa [9,10].

Most commonly the patients are asymptomatic and appendiceal mucocoele is an incidental finding during surgical intervention, imaging, or endoscopic procedures. It may also present sometimes as acute appendicitis. Other modes of presentation can be lower abdominal pain, abdominal mass, anemia, and weight loss [11-13]. There is a known association between mucocoele of the appendix and synchronous or metachronous colorectal tumors and ovarian mucinous tumors. So, colonoscopy and appropriate radiological in the pre or postoperative period is of paramount importance along with surgical exploration. Ultrasound examination shows a cystic mass with poor enhancement, with poorly defined wall and variable internal echogenicity depending on the composition of mucocoele. It shows a pathognomonic onion-skin appearance. The diameter of the appendix over 15 mm has been implicated as the threshold for diagnosis of appendiceal mucocoele. The outer diameter limit for the diagnosis of acute appendicitis has been established as 6 mm. The role of CT scan in diagnosing a mucocoele is related to the detection of appendicular lumen greater than 1.3 cm, the presence of cystic dilatation, and mural calcification [14-16]. The diagnostic finding of mucocoele on colonoscopy is the volcano sign in which the appendiceal orifice is in the center of a firm mound covered by normal mucosa or a yellow-colored lipoma like submucosal mass. Colonoscopy is also useful in identifying synchronous GI tumors in patients with abdominal pain [17].

Surgery is the mainstay of treatment. The extent of surgical intervention ranges from appendectomy to right hemicolectomy, which depends on various factors like the size of the tumor, location in the appendix, involvement of the cecum and ileum, if mucocoele is perforated or not, involvement of lymph nodes, presence of mucus collection, the safety margin and the final histology [6,13,14]. For the synchronous lesions, the extent of surgery should encompass the colonic pathology, regardless of the character of the mucocoele [18]. So, patients may require an appendectomy or up to a right hemicolectomy including cytoreductive surgery. Atraumatic removal of the appendix plays a crucial role in avoiding rupture and dissemination. Conversion into laparotomy should be considered if the lesion is traumatically grasped or there is an extension of the tumor beyond the appendix or signs of malignancy like peritoneal deposits are seen [19].

If a mucocoele is seen during laparoscopy, Dhage-Ivatury and Sugarbaker recommend converting the procedure to a laparotomy. The procedure is converted to a hemicolectomy in cases of suspected malignancy. Iatrogenic spillage can give rise to pseudomyxoma peritonei which requires intraperitoneal chemotherapy [6]. Right hemicolectomy and cytoreductive surgery (CRS) are combined with heated intraperitoneal chemotherapy (HIC) or early post-operative intraperitoneal chemotherapy (EPIC) in cases of perforation, appendiceal lymph nodes, or positive margins of excision [20]. A long-term follow-up is suggested for such patients.

In this case, mucocoele was an incidental finding on a routine annual health check-up. It was unperforated, located more than 2 cm away from the base of the appendix (negative margins of resection), and no regional lymphadenopathy was found. Hence appendectomy was performed which was adequate as per the standard algorithm. Histopathological examination confirmed it to be a simple mucocoele. The patient had an uneventful follow-up.

4. CONCLUSION

Though mucocoele of the appendix is a rare finding, it should be considered as a differential diagnosis of cystic lesions in the right lower quadrant of the abdomen. In our institute, we perform regular preventive health check-ups. In this particular case, we found an asymptomatic cystic mass in the abdomen which was diagnosed as a Mucocoele of the appendix and was surgically treated. Preventive health check-up plays a very vital role to identify such rare, asymptomatic, and treatable diseases. To conclude, we recommend all tertiary care institutions and health care organizations to take an initiative in conducting frequent preventive health check-ups and thereby help in the early diagnosis and treatment of such rare diseases.

CONSENT

All the authors declare that 'written informed consent was obtained from the patient (or other approved parties) for publication of this case report and accompanying images'.

ETHICAL APPROVAL

As per international standard guidelines, written ethical approval has been collected and preserved by the author(s).

REFERENCES

1. El Ajmi M, Rebai W, Ben Safta Z: [Mucocoele of the appendiceal stump—an atypical presentation and a diagnostic dilemma](#). Acta Chir Belg. 2009, 109:414-415. [10.1080/00015458.2009.11680451](#)
2. Fonseca LM, Lacerda-Filho A, Silva RG : [Pseudomyxoma peritonei syndrome 12 months after an intact resection of malignant mucocoele of the appendix: a case report](#). Clinics (Sao Paulo). 2010 Jun, 65(8):817-8. [10.1590/S1807-59322010000800014](#)
3. Hamilton DL, Stormont JM: [The volcano sign of appendiceal mucocoele](#). Gastrointest Endosc. 1989, 35:453. [10.1016/s0016-5107\(89\)72860-1](#)
4. Raijman I, Leong S, Hassaram S, et al.: [Appendiceal mucocoele: endoscopic appearance](#). Endoscopy. 1994 Mar, 26(3):326-8. [10.1055/s-2007-1008979](#)
5. Mizuma N, Kabemura T, Akahoshi K, et al.: [Endosonographic features of mucocoele of the appendix: report of a case](#) . Gastrointest Endosc. 1997, 46:549. [10.1016/s0016-5107\(97\)70013-0](#)
6. Sugarbaker PH, Bland KJ, Csendes A, et al.: [Appendiceal Epithelial Neoplasms and Pseudomyxoma Peritonei, a Distinct Clinical Entity with Distinct Treatments](#). General Surgery. Principles and International Practice. 2009, 885-893. [10.1007/978-1-84996-444-9_19](#)
7. García Lozano, Vazques Tarrago A, Castro Garcia C, et al.: [Mucocoele of the appendix: Presentation of 31 cases](#). Cirugia espanola. 2010, 87,2:108-12. [10.1016/j.ciresp.2009.07.020](#)
8. Shekhar R, Singh R, Hussain SN, et al.: [Management of appendiceal mucocoele diagnosed intraoperatively](#) . Int Surg J . 2019, 6:1000-2. [10.18203/2349-2902.isj20190839](#)
9. Pickhardt PJ, Levy AD, Rohrmann CA Jr, et al.: [Primary neoplasms of the appendix manifesting as acute appendicitis: CT findings with pathologic comparison](#) . Radiology. 2002, 224,3:775-81. [10.1148/radiol.2243011545](#)
10. Misdrayi J, Yantiss RK, Graeme-Cook FM, et al.: [Appendiceal mucinous neoplasms: a clinicopathologic analysis of 107 cases](#). Am J Surg Pathol . 2003, Aug, 27(8):1089-103. [10.1097/00000478-200308000-00006](#).
11. Stocchi L, Wolff BG, Larson DR, et al.: [Surgical treatment of appendiceal mucocoele](#). Arch Surg . 2003 Jun, 138(6):585-9. [10.1001/archsurg.138.6.585](#)
12. Hassan S, Dhebri A, Lin L, et al.: [Appendiceal mucocoele: a missed diagnosis](#). BMJ Case Reports. 2013, [10.1136/bcr-2012-007983](#)

13. Rabie ME, Al Shraim M, Al Skaini MS, et al.: [Mucus Containing Cystic Lesions “Mucocoele” of the Appendix: The Unresolved Issues](#). Int J Surg Oncol. 2015, [10.1155/2015/139461](#)
14. Karakaya K, Barut F, Emre U, et al.: [Appendiceal mucocoele: Case reports and review of current literature](#). World J Gastroenterol. 2008, 14(14):2280-2283. [10.3748/wjg.14.2280](#)
15. J. Rosai: [Tumours of the gastrointestinal tract appendix](#). Rosai and Ackerman's Surgical Pathology. Mosby, Philadelphia, Pa, USA; 2004. 9th edition:757-775.
16. Lien WC, Huang SP, Chi CL, et al.: [Appendiceal outer diameter as an indicator for differentiating appendiceal mucocoele from appendicitis](#). Am J Emerg Med. 2006, 24(7):801-805. [10.1016/j.ajem.2006.04.003](#)
17. Zanati SA, Martin JA, Baker JP, et al.: [Colonoscopic diagnosis of mucocoele of the appendix](#). Gastrointest Endosc. 2005, 62(3):452-6. [10.1016/j.gie.2005.04.018](#)
18. Kim-Fuchs C, Kuruvilla YC, Angst E, et al.: [Appendiceal Mucocoele in an Elderly Patient: How Much Surgery?](#). Case Rep Gastroenterol. 2011, 5(3):516-522. [10.1159/000331438](#)
19. Navarra G, Asopa V, Basaglia E, et al.: [Mucous cystadenoma of the appendix: is it safe to remove it by a laparoscopic approach?](#). Surg Endosc. 2003 May, 17(5):833-4. [10.1007/s00464-002-4266-6](#)
20. Palanivelu C, Rangarajan M, John SJ, et al.: [Laparoscopic right hemicolectomy for mucocoele due to a low-grade appendiceal mucinous neoplasm](#). JSLS. 2008, 12(2):194-197.

UNDER PEER REVIEW