

Original Research Article

Marginal Bone Level and Quality Evaluation Using CBCT After Functional Loading Around Dental Implant

ABSTRACT

Introduction: The importance of Cone Beam Computed Tomography (CBCT) in the field of Implant Planning is a rapidly emerging imaging modality for the purpose of implant planning. Having the obvious benefits over the conventional methods of radiography, CBCT by far is the most promising aid in the efficient implant-supported prosthetic field.

Aim: The present study aimed to evaluate the bone density and the height and width around dental implants and compare it to that of the edentulous space before placing the implant.

Materials and methods: A total of 20 subjects were selected with a single posterior edentulous space willing for implant-supported dental prosthesis. A pre-implant radiographic assessment was done with the help of CBCT, to evaluate the crestal height, crestal width and bone density, followed by surgical placement of the implant. After 6 months of implant placement, a post-operative radiographic assessment was done to evaluate the same parameters.

Results: It was observed that the mean crestal height, width and bone density was higher in the post-operative radiographic assessment compared to the pre-operative radiographic assessment and the difference was statistically significant.

Conclusion: From the given results, it can be concluded that alveolar bone width, height and bone density were significantly improved after implant placement and the osseointegration occurring after implant prosthesis greatly improves the periodontal status of the peri-implant tissues.

Keywords: Implant, marginal bone, CBCT, bone density, alveolar height, alveolar width

Comment [i-1]: Better to mention as bone quality

Comment [SJ2]: Changed it to bone quality

Comment [i-3]: Always better to mention the site of study and type of study

Comment [SJ4]: Site of study – Bhubaneswar Odisha
Type of study – Longitudinal study

Comment [i-5]: Why redundancy?

Comment [SJ6]: Redundancy removed

Comment [i-7]: Please mention about type of study, duration of study and ethical approval.

Comment [SJ8]: Type of study - Longitudinal study
Duration of study – 6 months
Ethical clearance taken

Comment [i-9]: It always better to present result in terms of numbers rather than plain language summary. Please mention in terms of numbers/ figures.

Comment [SJ10]: The values have been mentioned

Comment [i-11]: Better dental implant

Comment [SJ12]: Corrected

INTRODUCTION

There has recently been a surge in the field of dental prostheses and there is constantly a look-out for a better alternative to replace the conventional dentures. In this context, dental implants have really taken over the rest of the conventional methods. Not only do they provide a more efficient solution, but also give a long-term survival rate[1].

However, the success of dental implants depends largely upon a number of factors. The absence of any pathology around the implant and the efficiency with which osseointegration occurs, are very important factors in determining the success rate of a dental implant. For the same reason, it is pertinent to evaluate the implant stability, mobility, pain or any bone loss around the implant[2].

Radiographic assessment provides the clear picture of the different factors affecting the implant stability. Among all the radiographic modalities used, Cone Beam Computed Tomography (CBCT) has lately become the best opted modality. The use of CBCT has a number of benefits over the conventional radiographic techniques. Not only does it provide information on the peri-implant tissue and the degree of marginal bone loss, CBCT is efficient in determining the bone loss at different levels and help in early detection of bone loss around implants[3]. However, there is very little literature available comparing the alveolar bone quality pre- and post-implant placement. In the present study, we aim to evaluate the bone density and the height and width around dental implants and compare it to that of the edentulous space before placing the implant.

Comment [i-13]: Please use some other standard term, this is too layman.

Comment [SJ14]: Resolved

MATERIALS AND METHODS

An observational study for evaluating the pre- and post-implant bone density, bone height and width was done in Kalinga Institute of Dental Sciences, Bhubaneswar. The duration of this study was of 6 months (January 2021- August 2021). Institutional Ethical Committee clearance (IEC letter no. 172, dated 8/10/2020)

Comment [i-15]: Better to call it cross-sectional study

Comment [SJ16]: Corrected

was obtained for this study. For the present study, 20 individuals were selected from the departmental OPD of Oral Medicine and Radiology.

Comment [i-17]: Which sampling technique was used?

Comment [SJ18]: Sample size determination was done using G Power software (version 3.0) to achieve a power of 80% and a level of significance of 5%.

Sample size estimation:

Type: Empirical Data Used.

Comparisons of the MEAN DIFFERENCE between the different groups were taken into consideration

Level of significance = 5%, Power = 80%, Type of test = two-sided

Formula of calculating sample size is

$$n = \frac{[(r+1)(SD)^2 (Z_{\alpha/2} + Z_{\beta})^2]}{r d^2}$$

where

n = sample size required in each group,

r = Correlation coefficient between the groups = 0.3604 (data from previous studies)

d = Expected mean difference between the groups = 7.3 (data from previous studies)

SD = Standard deviation

$Z_{\alpha/2}$: This depends on level of significance, for 5% this is 1.96

Z_{β} : This depends on power, for 80% this is 0.84

Based on above formula the total sample size required was 20.

Inclusion and exclusion criteria:

Inclusion criteria included; patients within the age group of 18 to 45 years having single posterior edentulous space (molar or premolar region) with completely healed bone (at least 6 months after the loss/extraction of tooth) having a residual crestal bone height of 7 mm, and thickness of at least 6 mm, who were able to understand the study protocol and willing to give informed consent were included in the study.

Exclusion criteria included; patients with history of acute myocardial infarction, coagulation disorders, uncontrolled diabetes, psychological disorders (like Schizophrenia), aggressive periodontitis, head and neck radiotherapy in the past 2 years, immunocompromised patients (graft versus host disease). Patient on long-term non-steroidal anti-inflammatory drug therapy, individuals with history of past or present treatment using oral or intravenous bisphosphonate drugs. Chronic smokers, alcoholics, tobacco abusers or any other recreational drug abuser.

Comment [i-19]: Please cite the reference.

Comment [SJ20]: Resolved

Comment [i-21]: Please cite the reference.

Comment [SJ22]: Resolved

Comment [i-23]: No need of mentioning

Comment [SJ24]: Removed

Procedures involved including Materials / Armamentarium:

Informed consent of all patients was taken. A detailed case history of each patient was recorded.

Pre-operative radiographic assessment

Each patient was advised to undergo a radiographic assessment using CBCT before implant placement. MyRay Hyperion X9 CBCT machine was used for the present study. The software used for CBCT image acquisition was iRYS. The Field of View (FOV) selected for the present study was 11x8 mm. Cone beam computed images were evaluated using the classical orthogonal planes (axial, sagittal and coronal), Multiplanar Reformation (MPR) to provide panorama-like thin slice images and stacked sequential images and 3D volume rendering.

For each site, the crestal width and crestal height was measured (Figure 2). For maxillary arch, the crestal width was measured as the bucco-palatal extent of the alveolar crest in the coronal section, and the crestal height was measured as the distance between the alveolar crest and the floor of the maxillary sinus. Similarly, for mandibular arch, the crestal width was measured as the buccolingual extent of the alveolar crest in the coronal section, and the crestal height was measured as the distance between the alveolar crest and the superior border of the mandibular canal [5,6].

Bone density was determined by amount of mineral mass content in a certain volume of a structure, which is described in Hounsfield units (HU) and represents the relative density of a body tissue according to a calibrated gray-level scale based on HU units of air (-1000 HU), water (0 HU) and dense bone (+1000 HU) [6]. For standardization of the measurement, a virtual implant (using iRYS software) was placed in the selected edentulous space, simulating the actual implant planned for the same site[7]. For the pre-implant radiographic assessment, images representing 1 mm buccolingual slices immediately mesial or distal to the implants were selected for estimation of bone density. The region was traced (area ranging from 25-30 mm²) and the mean Hounsfield Unit was recorded [4]. (Figure 1&2)

Comment [i-[25]: Who was involved in measurements of radiographic parameters? How many people did the radiographic assessment? How was inter/intra-observer variation addressed? How many times were the measurements taken? Was the blinding done? What are the chances of investigator's bias in this study?

Comment [SJ26]: Resolved

Comment [i-[27]: Also mention the exposure parameters that were used.

Comment [SJ28]: 76 kVp, 5mA, 9.3 sec

Comment [i-[29]: Mention the version of the software.

Comment [SJ30]: Version 2.0

Comment [i-[31]: Roof

Comment [SJ32]: Resolved

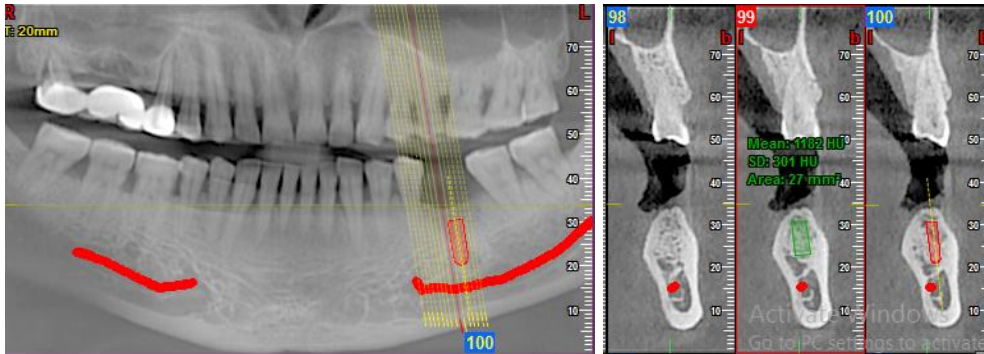


Figure 1: Pre-operative bone density assessment. Area marked in green represents the site of implant placement where bone density is measured. Area marked in red represents the simulated implant.

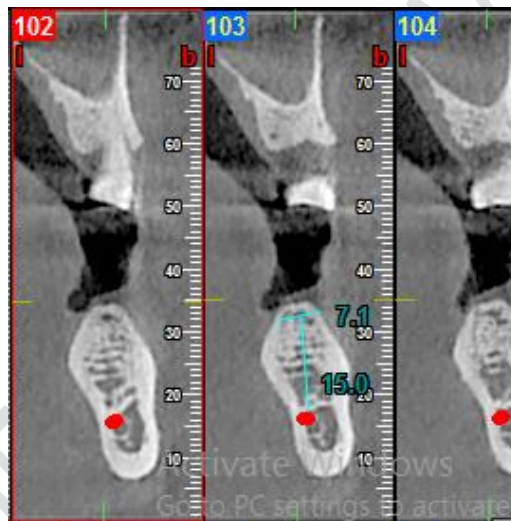


Figure 2: Pre-operative crestal height and width

Surgery

All patients received antibiotic prophylaxis (2g of amoxicillin 1 hour prior to surgery).

Local infiltration was given (2% lidocaine with 1:100000 adrenaline) and a crestal incision was made. Using a periosteal elevator, a vestibular full thickness flap was elevated. A full thickness lingual flap was elevated and the site was prepared for xenograft placement along with platelet rich fibrin for acceleration of osteoblastic activity for better bone formation.

Comment [i-33]: Is it actually needed? Rationale please..

Comment [SJ34]: Resolved

Following 1 month of graft placement implant placement was done. Osstem implant of size 5.5×10 mm dimension having corkscrew thread were placed at least 1.5 mm away from the adjoining teeth on either side and the was surrounded by at least 1 mm of bone on both lingual and buccal sides. Primary stability was achieved for all implants placed, with torque values above or equal to 25 Ncm.[9,10] . After 2 months of implant placement healing abutment was placed and after 4 months of implant placement delayed loading of prosthesis was done.

Post-operative radiographic assessment

After the placement of the implant prosthesis 6 months after the implant placement, the subjects were asked to undergo another radiographic assessment using Cone-beam computed tomography. The same parameters were kept in consideration as the pre-operative radiographic assessment and in the same manner the crestal height, crestal width and the bone density were evaluated and recorded[4] (Figure 3 & 4)

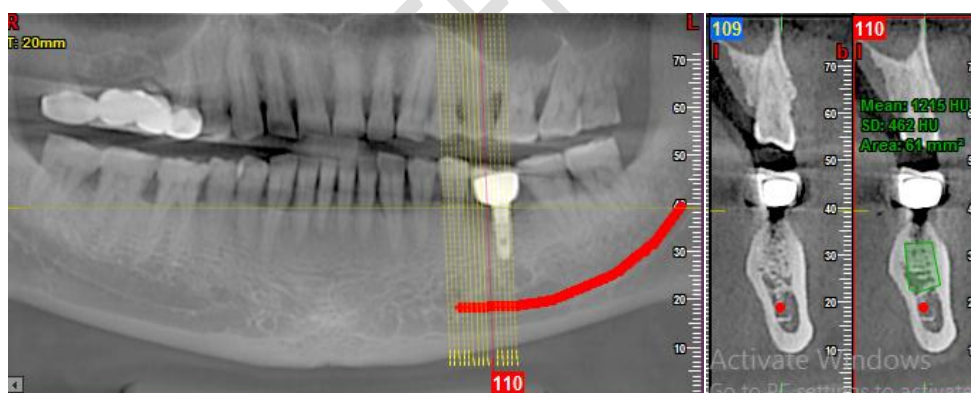


Figure 3: Post-operative bone density

Comment [i-[35]: How did you make sure that pre and post-operative measurements were done exactly at the same site?

Comment [SJ36]: Reference point has been explained

Comment [i-[37]: Was the patient asked to pay for post-operative CBCT? Is post-operative CBCT general protocol in implant placement? How ethical is it to ask the patient to go for CBCT just for the purpose of doing research? Please clarify.

Comment [SJ38]: The post-operative radiographic assessment after implant placement is a routine procedure for the evaluation of osseointegration and is done for each and every patient. The patients are not required to pay for the second CBCT. Also, the FOV is kept as small as possible to minimize patient exposure.

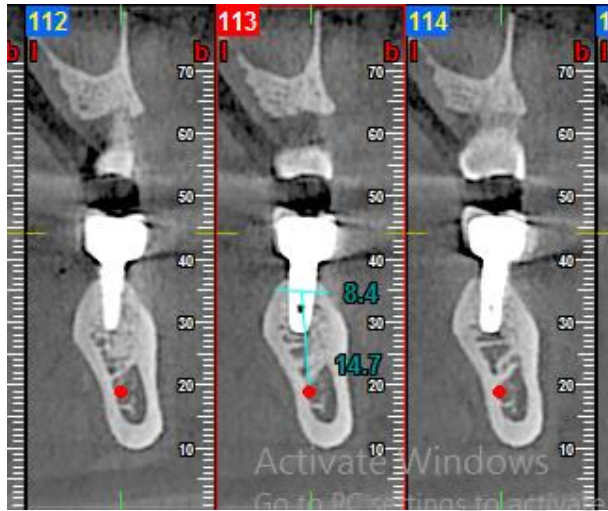


Figure 4: Post-operative crestal height and width

In the present study, for the post-implant radiographic assessment, images representing 1 mm buccolingual slices immediately mesial or distal to the implants were selected for estimation of bone density[4].

RESULTS

In the present study, a total of 20 patients were evaluated using CBCT, both pre- and post-implant placement. Out of the 20 subjects, 10 were male and 10 were female.

1. Distribution of the mean scores as compared pair wise

a. Distribution of the means scores of Crestal width as compared at different time intervals

Table 1: Distribution of the means scores of Crestal width as compared at different time intervals

Crestal Width	Mean	Std. Deviation	Std. Error Mean	Correlation**	P Value
Before Implant Placement	7.16 mm	0.765	0.171	0.918	<0.001*
After Implant Placement	7.73 mm	0.726	0.162		

*statistically significant

**Correlation value suggests the linear relationship of pre and post implant placement crestal bone width

Table 1 states that the mean score of crestal width for the entire population before the implant placement was 7.16±0.765 mm and after was 7.73±0.726 mm. A statistically significant correlation (suggests the linear relationship between pre and post implant placement crestal width) existed (p <0.0001; correlation coefficient = 0.918).

b. Distribution of the mean scores of crestal height as compared pair wise

Table 2: Distribution of the mean scores of crestal height as compared pair wise

Crestal Height	Mean	Std. Deviation	Std. Error Mean	Correlation**	P Value
Before	13.20 mm	1.088	0.243	0.992	<0.001*
After	13.77 mm	0.9614	0.215		

*statistically significant

**Correlation value suggests the linear relationship of pre and post implant placement crestal bone height

Table 2 states that the mean score of crestal height for the entire population before the implant placement was 13.20±1.088 mm and after was 13.77±0.9614 mm. A statistically significant correlation (suggests the linear relationship between pre and post implant placement crestal height) existed (p <0.0001; correlation coefficient = 0.992).

Comment [i-[39]: Not needed. Understood from the table.

Comment [SJ40]: Removed

Comment [i-[41]: Not needed. Understood from the table.

Comment [SJ42]: Removed

c. Mean Score distribution of the baseline and post-operative variables of bone density

Table 3: Mean Score distribution of the baseline and post-operative variables of bone density

Bone Density	Mean	Std. Deviation	Std. Error Mean	Correlation	P Value
Before	869.30 HU	148.346	33.171	0.977	<0.001*
After	927.50 HU	175.266	39.191		

*statistically significant

**Correlation value suggests the linear relationship of pre and post implant placement crestal bone density.

Table 3 states that the mean score of bone density for the entire population before the implant placement was 869.30±148.346 HU (Hounsfield unit) and after was 927.50±175.266 HU (Hounsfield unit). A statistically significant correlation existed (p <0.0001; correlation coefficient = 0.977).

The t- value for paired t- test have been presented in Table 4 and the mean in Table 4 represents the delta mean value for the pre and post operative bone level.

Table 4: t-test value for pre and post implant site bone

Variable	Paired Differences					t	df	Sig. (2-tailed)
	Mean	Std. Dev	Std. Error Mean	95% Confidence Interval of the Difference				
				Lower	Upper			
Pre-implant Crestal Width (mm) – Post-implant Crestal Width (mm)	0.57	0.30	0.068	0.71	-.42	-8.37	19	<0.0001*
Pre-implant Crestal Height (mm) – Post-implant Crestal Height (mm)	0.56	0.17	0.039	0.64	-.48	-14.14	19	<0.0001*
Pre-implant Bone density (HU) – Post-implant Bone density (HU)	58.20	43.87	9.811	78.73	-37.66	-5.93	19	<0.0001*

*statistically significant

Comment [i-43]: Not needed. Understood from the table.

Comment [SJ44]: Removed

DISCUSSION

Implant planning requires the precision and the exactness that can only be provided by a tri-dimensional radiographic technique. The proximity of the implant to vital structures such as the mandibular canal and the maxillary sinus makes it absolutely pertinent for clinicians to be undeniably sure of the correct position of these structures in relation to the implant. Also, the post-operative evaluation of the implant is equally necessary to ensure the success of the prosthesis and for that the assessment of the surrounding bone quality is required. Comparing the bone levels and the bone mineral density of the alveolar bone surrounding the implant to that of the edentulous space prior to the placement of the implant gives us a fair idea of the changes in the quality of the bone. And, for all these requirements CBCT has proven to be the appropriate technique capable of evaluating the peri-implant bone measurements [5,6,7,8].

According to the European Association for Osseointegration recommendations for the use of pre-operative cross-sectional imaging (including CBCT), all guided implant surgeries should be accompanied by computer assisted planning for placement of dental implants [10,11,12].

The subjects ranged between the age group of 18-45 years, the mean age being 40 years. On comparing the mean scores of the Crestal width pre- and post-implant, it was seen that a statistically significant correlation existed between the two time-intervals ($p < 0.0001^*$) in that the mean crestal height after implant placement was higher than the mean crestal height before implant placement. This finding was in accordance to the study conducted by Bergkvist et al (2010) [13] and contrary to the findings of the study conducted by Dwingadi et al (2019) [1] and by Youssef et al (2015) [2].

When the pre-implant Crestal height was compared to the Crestal height post-implant, it was seen that a statistically significant correlation (correlation between pre and post implant placement crestal height) existed between the two time-intervals ($p < 0.0001^*$) in that the mean crestal height after implant placement was higher than the mean crestal height before implant placement. This finding was in accordance to the study conducted by Bergkvist et al (2010) [13] and contrary to the findings of the study conducted by Dwingadi et al (2019) [1] where mesial bone loss of 1.08 mm and distal bone loss of 1.36mm was noted.

Comment [i-[45]: It's more like a literature review than discussion. The results are just compared with similar and dissimilar findings. Discussion actually is defending your results in terms of language using logics and reasons with the help of available literature. Why did happen, how did it happen and what are possible reasons for your findings needs to be explained.

Comment [SJ46]: Resolved

Comment [i-[47]: Height or width?

Comment [SJ48]: Width

Comment [i-[49]: Too long sentence

Comment [SJ50]: Resolved

Comment [i-[51]: Need not mention

Comment [SJ52]: Resolved

For the bone density evaluation, comparing the mean values of pre- and post-implant bone mineral density revealed that a statistically significant correlation existed between the two time-intervals ($p < 0.0001^*$; correlation coefficient = 0.977) in that the mean bone density before implant placement was higher than the mean bone density after implant placement. This finding was in accordance to the study conducted by Youssef et al (2015) [2] (mean bone density value was 827.96 ± 206.85 immediately post-operatively, then increased to 890.67 ± 138 & 1018.0 ± 149.79 on the 3rd and 6th months respectively after implant placement, there was a statistical significant increase in bone density) and contrary to the findings of the study conducted by Dwingadi et al (2019), and Bergkvist et al (2010)[13].

Limitation of study

The differences in the results obtained in the present study in comparison to the available literature may be owing to the difference in the study population, the ethnic diversity of the study groups, geographic distribution, the procedure followed in different studies, the type of implant placed and sample size.

CONCLUSION

After all the evaluation and the relative comparisons with other relevant studies, it can be concluded that alveolar bone width, height and bone density are fairly improved after implant placement and the osseointegration occurring after implant prosthesis and xenograft placement. CBCT is indeed one of the most vital imaging modalities that aids in implant planning and the evaluation of dental implants post-treatment. However, research in this sphere of work remains dishearteningly scarce and more emphasis should be given to conducting more such studies in the near future.

COMPETING INTERESTS DISCLAIMER:

Authors have declared that no competing interests exist. The products used for this research are commonly and predominantly used products in our area of research and country. There is absolutely no conflict of interest between the authors and producers of the products because we do not intend to use these products as an avenue for any litigation but for the advancement of knowledge. Also, the research was not funded by the producing company rather it was funded by personal efforts of the authors.

Comment [i-53]: These are rather not the limitations of the study.

Comment [SJ54]: Removed

Comment [i-55]: These are the possible limitations, please identify few more limitations and chances of bias in this study.

Comment [SJ56]: Resolved

Comment [i-57]: Conclusion cannot be written based on comparison with others studies. It is purely concluding your findings.

Comment [SJ58]: Resolved

Comment [i-59]: Can the outcome of study done in 20 people be generalized in this way? Please refine revise and rephrase the conclusion.

Comment [SJ60]: Resolved

REFERENCES

1. Dwingadi E, Soeroso Y, Lessang R, Priaminiarti M. Evaluation of Alveolar Bone on Dental Implant Treatment using Cone Beam Computed Tomography. *Pesqui Bras Odontopediatria Clín Integr.* 2019;19(4917):1–10.
2. Youssef M, Shaaban AM, Eldibany R. The Correlation between bone density and Implant stability. *Alexandria Dent J.* 2015;40(1):15–21.
3. Dave M, Davies J, Wilson R, Palmer R. A comparison of cone beam computed tomography and conventional periapical radiography at detecting peri-implant bone defects. *Clin Oral Implants Res.* 2012;00:1–8.
4. Venkatesh E, Elluru SV. Cone Beam Computed Tomography: Basics and Applications in Dentistry. *J Istanbul Univ Fac Dent.* 2017;51(3):102–21.
5. Jacobs R, Salmon B, Codari M, Hassan B, Bornstein MM. Cone beam computed tomography in implant dentistry : recommendations for clinical use. *BMC Oral Health.* 2018;18(88):1–16.
6. Campos MJ da S, De Souza TS, Luiz S, Fraga MR, Vitral RW. Bone mineral density in cone beam computed tomography: Only a few shades of gray. *World J Radiol.* 2014;6(8):607–12.
7. D'haese J, Ackhurst J, Wismeijer D, De Bruyn H, Tahmaseb A. Current state of the art of computer-guided implant surgery. *Periodontol 2000.* 2017;73(1):121–33.
8. Bornstein M, Buser D. Implant Dentistry - The Use of Cone Beam Computed Tomography (CBCT). 1–36 p.
9. Verardi S, Testori T, Stacchi C, Orsini M, Pulici A, Lombardi T, et al. Comparison between two different techniques for peri-implant soft tissue augmentation: Porcine dermal matrix graft versus tenting screw. *J Periodontol.* 2019;00(February 2020):1–7.
10. Roberto C, Paolo T, Giovanni C, Ugo C, Bruno B. Bone remodeling around implants placed after socket preservation : a 10-year retrospective radiological study. *Int J Implant Dent.* 2021;7(74):1–8.

Comment [i-[61]: Please make it completely uniform. The way of referencing book is different.

Comment [SJ62]: Resolved

11. Bornstein M, Horner K, Jacobs R. Use of cone beam computed tomography in implant dentistry : current concepts , indications and limitations for clinical practice and research. *Periodontol 2000*. 2017;73:51–72.
12. Morton D, Chen MSST, Martin WC, Levine MSRA, Buser FD. Consensus Statements and Recommended Clinical Procedures Regarding Optimizing Esthetic Outcomes in Implant Dentistry. *Gr 3 Consens statements*. 2014;29:216–20.
13. Bergkvist G, Koh K-J, Sahlholm S, Klintstrom E, Lindh C. Bone Density at Implant Sites and Its Relationship to Assessment of Bone Quality and Treatment Outcome. *Int J Oral Maxillofac Implants*. 2010;25(2):321–8.