

## Original Research Article

### LEFT OVARIAN TORSION A CASE REPORT

#### ABSTRACT:

Ovarian torsion accounts for more than 3% of gynecological emergencies with an incidence, among all ages of women, of 5.9 per 100,000 women. This affection can be simply defined as twisting of the ovary around its ligamentous support, often resulting in impedance of its blood supply which can lead to ovarian necrosis, infection and peritonitis. Ovarian torsion is mainly associated with presence of benign ovarian masses, as malignant tumors are less frequent and less prone to undergo ovarian torsion. This is why this complication needs to be diagnosed as early as possible to preserve the function of ovaries and fallopian tubes and to prevent necrosis. Some of the surgical procedures available to untwist the ovary are laparoscopy and laparotomy. If there is prolonged loss of blood flow to the ovary and surrounding tissue then the procedures like oophorectomy and salpingo-oophorectomy are suggested.

Keywords: Ovarian torsion, ovarian necrosis, laparoscopy, laparotomy. Oophorectomy, salpingo-oophorectomy.

#### INTRODUCTION:

Ovarian torsion occurs when the ovary twists around the ligaments that support the adnexa cutting off blood flow to the organ [1]. The fallopian tubes often twists along with the ovary, and is referred as adnexal torsion. If the blood flow becomes restricted for a long time, it can lead to necrosis of tissue. Some of the causes that may lead to ovarian torsion includes extra weight or mass on ovary, polycystic ovarian disease (PCOD), having long ovarian ligament that connects ovary to the uterus etc.,[3]. Most commonly ovarian torsion affects premenopausal women but up to 17% of torsion may also occur in prepubertal and post-menopausal females [6]. Even though ovarian torsion occurs in normal adnexa, most frequently it arises from one of many anatomic changes. Fewer than half of ovarian torsion cases in pediatric patients involve cysts, teratomas or other masses [7]. There are more than 80% of patients with ovarian torsion having ovarian mass of 5cm or larger. It is indicative that the primary risk in ovarian torsion is ovarian mass [8]. Ultrasound scan is one of the most useful techniques for diagnosing, but normal doppler examination does not exclude ovarian torsion [2]. It is known that, there are no significant differences in symptoms, investigations or signs except ultrasound finding of an enlarged ovary [5]. Sometimes diagnosis of ovarian torsion becomes challenging because the symptoms are very similar to kidney stones, appendicitis, Urinary tract infections (UTI), gastro enteritis and other conditions. In pediatric Age-group, ovarian torsion is a rare problem which should be included in differential diagnosis of any girl with abdominal pain or a pelvic or abdominal mass [2]. Torsions mostly involve both ovary and fallopian tubes and there are some cases of isolated torsion involving either one (one in 1.5 million women) [4]. Diagnosis of this torsion is relatively rare, affecting about 6 per 100,000 women per year. It is most commonly seen in reproductive age or it can occur at any age [9]. Treatment for ovarian torsion can be done either by untwisting

**Comment [H1]:** This is a good manuscript. However, it is marred with a lot of grammatical and punctuation errors. I suggest the author(s) contract an English-speaking person to read through this manuscript and make all the corrections.

and fixing the ovary in place or by removing it [9,10]. Right side of the ovary is most commonly affected by torsion due to increased length of the utero-ovarian ligament on the right and presence of the sigmoid colon on the left [12]. In severe cases, where blood flow is stopped for the ovary for extended period of time, ovary can be necrotized. In such cases ovary must be removed surgically [11].

#### CASE REPORT:

A 19-year-old female was admitted into the gynecological ward with the chief complaints of pain in left iliac fossa of one day duration on & off, non-radiating, 3 episodes of vomiting's. Patient has no similar complaints in the past and no history of white discharge, urinary tract infection symptoms, fever or any allergies. There is no previous surgical history in the past. The physical exam has showed tenderness in hypogastric region of right and left iliac fossa and slightly pallor. Lab investigations were performed which showed decreased Hb-7.6 gm/dl, increase in polymorphs- 78 % and reduction of lymphocytes-19 %, monocytes-2 % and Erythrocyte sedimentation rate was highly increased to 50 mm/hr. Ultrasound scan of abdomen showed minimally extended urinary bladder and minimal amount of free fluid noted in pelvis and polycystic ovarian disease. Right ovary is normal in size and the left ovary is enlarged and edematous with cystic lesion of 7x5x5.4 cm noted in left ovary with peripherally arranged follicles. Based on lab investigations and clinical data it was diagnosed that patient is suffering from "Left Ovarian Torsion". Patient has undergone surgery as advised by the physician. Laparoscopy was done to the patient which untwist the ovary. Pharmacological treatment was given to the patient after the surgery which includes antibiotics, analgesics and antifibrinolytics etc., and these medications should be continued as per the suggestions given by clinicians. Patient will recover quickly after the surgery if medications are used properly.

**Comment [H2]:** The author(s) should provide better picture, and not snap shots.

**Comment [km3]:**

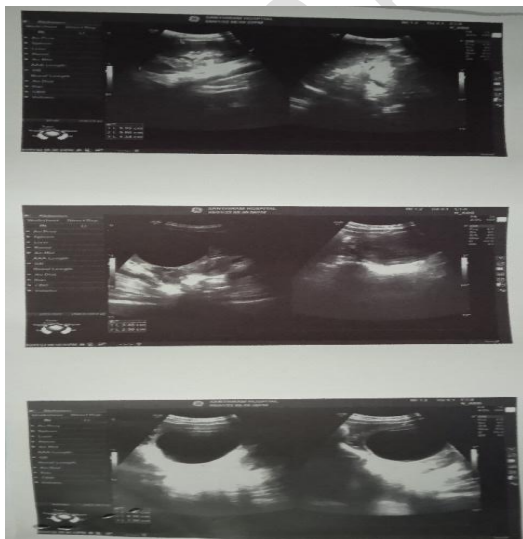


Fig.1 Ultrasound scan

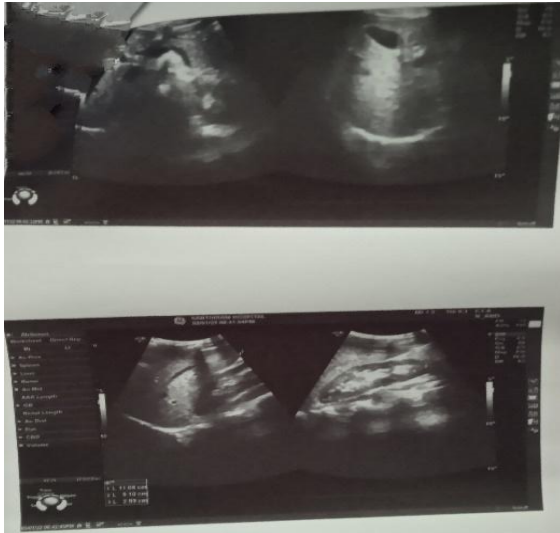

Fig.2 Ultrasound scan of abdomen

## DISCUSSION:

Ovarian torsion is also called as adnexal torsion. This occurs when the ovary becomes twisted around the tissue that supports it. In some case fallopian tubes may also become twisted. And this condition is considered as a medical emergency. Recognition of ovarian torsion early essential for preserving the ovary, particularly in patients with future fertility aspirations. Otherwise, it can lead to necrosis, loss of ovary and infertility if not identified promptly. Generally, ovary has the blood supply from both the ovarian arteries as well as uterine arteries. Due to twisting of ligaments, it can lead to venous congestion, edema, compression of arteries and eventually loss of blood supply to the ovary. We observe right side ovarian torsion more commonly than left sided torsion because of increased space in the right pelvis due to location of the sigmoid colon in the left. Some of the symptoms experienced by the patient will be lower abdominal pain or pelvic pain. Pain can be continuous, intermittent or sharp. Patient may also have nausea, vomiting along with abdominal and pelvic pain. Grey scale ultrasound findings are helpful in identifying enlarged ovary, ovarian mass, free fluid, follicles at the periphery of enlarged ovary and twisted pedicle. As the symptoms of ovarian torsion are more similar to appendicitis, diverticulitis or renal colic, computed tomography rather than ultrasound is first modality with which patients are imaged even after appropriate clinical evaluation. Furthermore, when ultrasound or computed tomography reveals the indeterminate gynecologic mass, magnetic resonance imaging will be the next step for further characterization. The better method for treating ovarian torsion in premenopausal women is

surgery with adnexal sparing. Ovaries are found functional in greater than 90% of patients who underwent detorsion and found fertile (young women). Pelvic pain also becomes reduced for the women who undergoes the surgery. Hence surgery with adnexal sparing is the management of choice. Recurrence of torsion in the same ovary or both is possible. Ovarian torsion is usually not a life-threatening condition but it is an organ threatening. In case of our patient the ultrasound scan was done and the results showed enlarged left ovary with peripherally arranged follicles and minimal amount of free fluid noted in pelvis and polycystic ovarian disease. Due to presence of some symptoms like vomiting along with abdominal pain and the results of ultrasound, it is confirmed that patient is suffering with left ovarian torsion.

#### **CONCLUSION:**

Ovarian torsion is a gynecological emergency which is rare and requires an early surgical intervention to prevent the ovary from necrosis and to restore proper blood flow. One of the challenging factors of ovarian torsion is its diagnosis because of its non-specific clinical presentation. Various etiologies are attributed to ovarian torsion. Even though there are no specific indications, diagnosis of ovarian torsion should be considered on finding a pelvic mass. One of the best managements preferred for ovarian torsion is laparoscopy. Because of high recurrence rate oophoropexy may be considered.

#### **REFERENCES:**

1. Shelby.L.Guile, Josephin.K.Mathai. Ovarian torsion.2020. treasure Island (FL): Stat pearl publishing.2022
2. Darrel L.cass, "Ovarian torsion", Seminars in pediatric surgery, 2005; vol 14, Issue 2, pages 86-92.
3. Corey Whelan. What is ovarian torsion. 2018
4. Ci Huang, Mun-Kun and Dah-ching Ding: A review of ovarian torsion. Tzu chi Med J.2017;29(3)3: 143-147.
5. Katherine Adams, Emma Ballard, Akwasi Amoako et.al: Ovarian presentation & duration of symptoms in ovarian torsion; Journal of obstetrics and gynecology.2021;1-5.
6. Sangeeta Bhasin, Neha Gupta et.al: Ovarian torsion; Obstetrics and Gynecological emergencies.2011;239.
7. Erik D Schraga, C Fleisher. Ovarian torsion.2017.
8. White M, Stella J et.al: Ovarian torsion: 10-year perspective. Emerg Med Australas.2005;17;231-7.
9. Robertson JJ, Long B, Koyfman A: Myths in the evaluation & management of ovarian torsion, The journal of emergency medicine;2017;52(4):449-456.
10. Adnexal torsion, Merck manuals professional edition. Retrieved 12 September 2018.
11. Crouch NS, Gyampoh B, Cutner As et.al: Ovarian torsion: to pex or not pex? Case report and review of literature. Journal of pediatric and Adolescent Gynecology.2003;16(6):381-4.
12. Lauren Evans, Christopher Fowler et.al: Ovarian torsion. 2019.