

Original Research Article

TIBIAL HEMIMELIA: CHALLENGES IN MANAGEMENT IN A RESOURCE CONSTRAINED REGION

ABSTRACTS

Background; Tibial Hemimelia is a rare congenital deformity which is associated with challenges in management even in developed countries. We document our experience and demonstrate the influence of socio-cultural beliefs in the management.

Patients and Method; The clinical information of all the patients were retrieved from the patient medical journal from 1st of November 2016 – 31st October 2020.

Results; Three patients with four cases of Tibial Hemimelia were managed during this period. One of the patients had bilateral deformities with upper limb involvement and there was associated bilateral clubfeet. This patient had positive family history. The mothers were all young with one of them being seropositive. They were all males. One was delivered via cesarean section. No positive maternal history of ingestion of over the counter drugs. All the cases were seen and counseled in our hospital regarding treatment options, outcomes and the need not to abscond from clinic. Two were lost to follow up despite initiation of treatment.

Conclusion; Tibial Hemimelia is a rare deformity worldwide with numerous treatment options with guided outcomes. There is need for support systems to be put in place, parental cooperation and societal empathy if we must succeed.

Keywords; Tibial Hemimelia, Congenital Deformity, Socio-cultural beliefs, Clubfoot, Radial club hand.

Comment [VS1]: Age needs valid numbers to discuss social constrains

Comment [VS2]: Seropositive for specific disease needs documentation

Comment [VS3]: These if scientific needs tom specify need to validate the reason why this discussion ?

INTRODUCTION

Tibial hemimelia (aka Tibial Deficiency) is a spectrum of disorders characterized by partial or complete absence of the tibia, an overgrown fibula, variable degrees of knee deformity and function, and an equinovarus foot.¹ In addition to these, the quadriceps may be normal, distally deficient or absent just as the patella may be normal, dysplastic or absent.² In some cases, the fibula may be dysplastic or double. The distal femur may be bifurcated as part of the disorder or in isolation.^{3,4} Tibial hemimelia is the common feature in these syndromes: CHARGE syndrome; a pattern of eye, ear, nose and limb anomalies. Weber; a syndrome complex comprising tibial hemimelia, **polysyndactyl** and triphalangeal thumb; tibial hemimelia diploma syndrome; tibial hemimelia split hand/ foot syndrome ; tibial hemimelia - trigonal brachycephaly syndrome.^(2, 4, 5) It is a rare congenital anomaly which affects 1:1000,000 live births.³⁻⁶ The condition may be unilateral or bilateral, being more common on the right side than on the left.⁷

There have been many attempts at classifying this condition: Jones in 1978 classified tibial hemimelia into 4 types: type I is absence of a visible tibia: subclass a; is a dysplastic distal femoral epiphysis and subclass b; well formed distal femoral epiphysis. Type II is an ossified proximal tibia and a distal tibial deficiency; type III is characterized by a distal ossified tibia and proximal tibial deficiency while type IV is a shortened tibia with distal tibiofibula diastasis. This classification is useful for planning treatment.^{2, 4, 8}

The Paley's classification² is useful for treatment planning purposes. It has 5 classes and 2 subclasses: type I, is a hypoplastic nondeficient tibia, genu valgum, an overgrown proximal fibula and presence of normal plafond. Type II is proximal and distal tibial epiphyses present with a dysplastic ankle; with subtype A: well formed distal tibial epiphysis separate from proximal tibial physis, dysplastic tibial plafond and a relatively overgrown proximal fibula, while. Subtype B is Delta tibia with proximal and distal epiphysis connected through a bracket physis, mal-oriented dysplastic ankle, mal-oriented knee and a hypoplastic plafond; subtype C, is delayed ossification (cartilaginous enlarge) of all or part of the tibia. Type III has proximal tibia and knee present, present medial malleolus, absent tibial plafond and tibiofibular diastasis; subtype 3A consists of absent tibial plafond, present medial and lateral malleolus, varus diaphysal bowed tibia, distal fibula with foot internally rotated around tibia, talus may be positioned between the tibia and fibula due to absence of the tibial plafond, relative fibula overgrowth; subtype 3B is the above plus a skin cleft separating the tibia and fibula and a foot oriented towards the tibia. Type IV is distal tibial aplasia; subtype 4A consist of a normal knee joint, complete absence of the distal tibia from the diaphysis, pointed bone end covered by a separate skin pouch, relative overgrowth of the fibula while subtype 4B is characterized by present epiphysis but absent proximal physis, knee joint present, delayed ossification of epiphysis, relative overgrowth of the fibula. Type 5 is complete tibia aplasia with subtype 5A consisting of complete absence of the tibia, present patellar, flexion contracture of the knee,

equinovirus contracture of a dislocated foot and ankle. Subtype 5B is complete tibial aplasia, absent patellar, knee contracture, auto centralized fibula, normal quadriceps, knee capsule present while subtype 5C is complete absence of the tibia, patella, quadriceps muscle, a dislocated fibula and knee contracture.²

Aetiology of tibial hemimelia is largely unknown¹⁰ and no definitive genetic pattern of inheritance has been elucidated. Both autosomal and recessive genetic types of inheritance have been reported. Most of this condition seen has been sporadic though familial type of inheritance has been reported.^{11, 12}

The treatment for tibial hemimelia by a large consensus is amputation or knee disarticulation.^{3, 4} Reconstructive surgery is considered in some patients with patella and tibial enlarge implying active quadriceps mechanism which can be established through an MRI. This reconstructive surgery is considered for Jones type I.² Inconsistent outcomes (as espoused by proponents of reconstructive surgery) have made it unpopular leaving ablative surgery as the popular option for all types of tibial hemimelia.

The social and economic factors (the socio-economic status indicators) such as education, income, occupation, family support systems and community safety with physical environmental factors affect the health status of an individual and the population at large.¹³ But in Nigeria other factors as religious beliefs, patronage of traditional African medicine and denial of reality affects the health seeking behavior of its citizens in general.¹⁴ This can reflect the value the country places on Health and Education.

We report 3cases of tibial hemimelia at our hospital over a three year period but all were seen in a year.

CASES

A 3 months old male child, delivered through spontaneous vertex delivery at term. No history of maternal febrile illness or ingestion of unprescribed drugs, exposure to radiation or any other adverse event during pregnancy. There was a history of limb deformity in elder brother but no positive history in both maternal and paternal family. Clinical examination revealed limb length discrepancy between both lower limbs. The right lower limb had hypoplastic thigh, absent knee with a flexion contracture of 70 degrees. The knee could be passively extended to -15 degrees. The leg had an anterior curvature, with a very prominent lateral malleolus and absent medial malleolus. The foot was in a rigid equino-varus. The left lower limb had similar features as right, except that the equinus was more severe. The upper limbs have radially curved hands with two extra little digits each. There was normal arm region of both upper limbs. There was no asymmetry, no defects, no tufts of hair on the back, head and neck region were normal. The father is a fisherman and the mother a peasant farmer both living in a remote village with no amenities.

X-ray showed absent distal femoral epiphysis, absent patella, a larger than normal centrally placed fibula. Fibulae were curved anteriorly.

A diagnosis of Bilateral tibial hemimelia, Jones type Ia with bilateral polydactyl and Radial club hand was made

Plan was to educate parents on child's condition, as it bothers on progression, treatment and treatment outcomes; Parents were offered ablative surgery and prosthetic fittings for both lower limbs as best treatment option. The radial club hand was to be managed with serial manipulation and casting for the time being.

Comment [VS4]: Reference to the pictures and the labelling should be as per AJOR guidelines for authors.

Comment [VS5]: These therapy options are not validates and need to strengthen the reason for offering these with regards to Evidence based practice guidelines.

CASE 2

An 11months old male infant delivered through **Caesarian section to a seropositive** mother who is compliant with antiretroviral medications. Pregnancy and antenatal care were uneventful; brother is normal and no positive maternal and paternal family history of limb deformity. Examination reveals smaller right lower limb compared to the left, thigh was shorter, knee supple, leg was anteriorly curved with tenting of the skin at mid leg region. The foot was hypoplastic and in **equinus**, the big toe and medial malleolus was absent. The chest, abdomen, upper limbs and genitalia were normal.

A radiograph of the lower limbs showed a well formed femur, distal femoral epiphysis, fibula and a proximal tibial tapering into a sharp end.

A diagnosis of tibial hemimelia, Jones type 2 was made. Parents were counseled on the problem and offered options of limb reconstruction or ablative surgery when child turns one year old. Serial manipulation and casting were commenced. Child was lost to follow up.

Comment [VS6]: Scientific language recommended

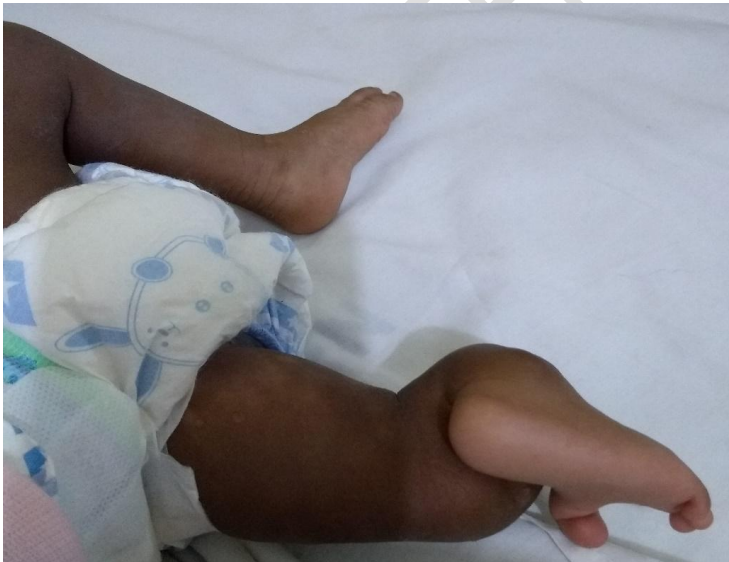

Fig. 1 Gross picture of the deformity

CASE 3

A 15days old neonate delivered at term to a 30years old mother of 3 children devoid of limb deformity. No history of ingestion of over the counter drugs. Antenatal period was uneventful. No positive family history of maternal or paternal deformity of the limbs. On Examination the left lower limb has an hypoplastic thigh, absent knee, anteriorly bowed leg, a cleft on the skin at mid leg level, a prominent lateral malleolus, absent medial malleolus and an equino-varus foot. The right lower limb was 3cm longer than the left with anteriorly bowed leg. The head and neck, abdomen and both upper limbs were normal. The parents are petty traders with secondary level education and live in town.

Radiograph of both limbs showed a normal femur and a slightly curved tibia on the right. A normal femur, knee and absent tibia were the findings on the left. A diagnosis of tibial hemimelia Jones type IA was made.

Parents were counseled for reconstructive surgery or ablative surgery depending on their compliance with finance. Two years after the management is for ablative surgery.

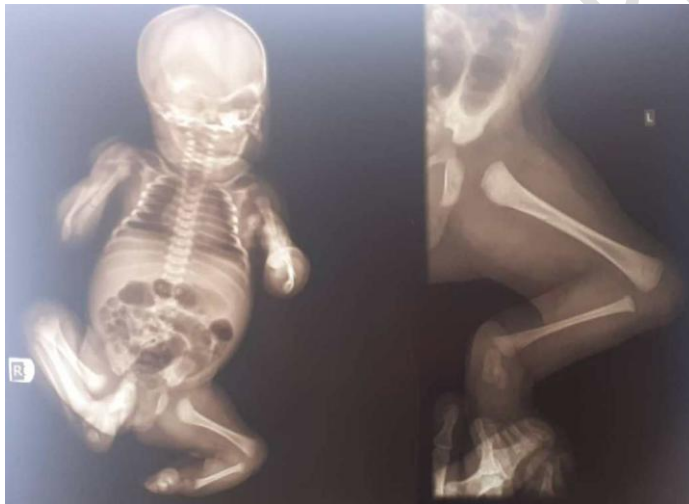

Fig. 2 Babygram showing the deformity on the left

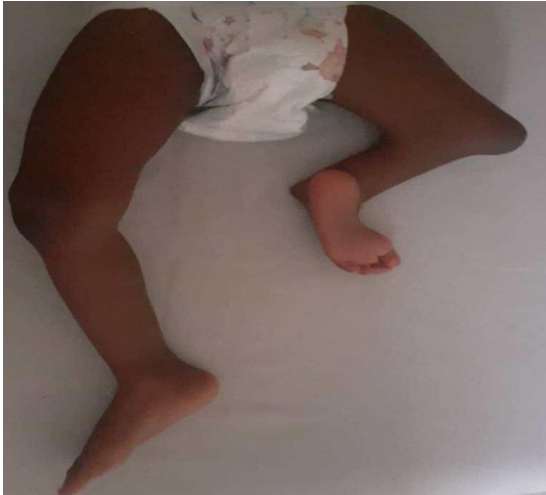

Fig. 3 Showing progression of deformity after 2years




Fig. 4 Showing Callosity on the distal femur as child ambulates on deformity

DISCUSSION

Tibial Hemimelia is a rare condition as seen in our series over the study period where we saw 3 cases even though they all presented in a year. This is similar to that reported by other series.^{3,4} This may be due to under reporting or poor health awareness which is still a problem in Nigeria coupled with poor sociocultural beliefs, poverty and socioeconomic status, which have been shown to influence outcomes of other disease conditions.¹⁵

Two of the patients in our series had no family history of limb deformities. A greater percentage of Tibial hemimelia occurs sporadically.² One of the patients had an older siblings with similar deformity. The existences of the deformity in multiple siblings have been reported.^{2, 16} No specific inheritance pattern but some researchers reported familial type of inheritance.^{11, 12} The first case has bilateral deformity. There is a 30% incidence of bilateral pathology.² Our first case had bilateral tibial hemimelia with bilateral radial club hand and polydactyl of both hands while the second case had absent right big toe. These are complex affectations associated with tibial hemimelia, which is known to occur with other congenital anomalies.^{2, 5} There was male preponderance in our series but other literature was not very clear on the sex predilection. There was equal affectation of both right and left lower limbs. Most authors report 72% involvement of the right lower limb.² This finding may be due to the small number of cases seen. The second and third patients had limb length discrepancy. Tibial hemimelia is a major cause of limb length inequality and this has great bearing on management planning.³

The first patient presented a peculiar management challenge due to not only the bilateral involvement, but also the absent knees and hypoplastic quadriceps muscle — features which ruled out the options of a Brown procedure. Ablative surgery and prosthetic fittings were advised as best options but parents offered to seek a second opinion. The radial club hand were to be addressed with serial manipulation and casting for the time being. The second patient with Jones type 2 and third patient with type IV were offered reconstructive surgery when they turn one. Two of the patients never returned to clinic, we hope they show up sometime. The last case that returned did so due to cosmetic reasons.

The Brown procedure — which included a centralization of the fibula and Syme's amputation at one year for Jones type I offered hope to parents and patients with tibial hemimelia as it aims for limb salvage but the presence of a normal quadricep muscle is central to its success. Brown found most of the poor outcomes in patients with hypoplastic or absent quadricep muscles.^{10–12} Those patients with poor outcome were eventually offered ablative surgery as a salvage procedure.^{2, 17} The procedure has a high failure rate therefore careful patient selection is key.

Paley had attempted more complex reconstructive surgeries for all classes of tibial hemimelia using the presence of the patellar as a guide with variable results.² Ablative surgeries, disarticulation of the knee for Jones type I and below knee amputation for Jone's types II, and

Comment [VS7]: Autosomal dominant and recessive patterns have been reported (Richieri-Costa; 1987)

Comment [VS8]: Congenital maldevelopments are not scientifically labelled as affections.

Syme's amputation for type IV, are by a large consensus the popular treatment modalities for tibial hemimelia.^{3, 5, 10, 17}

Access to health care in Nigeria is largely on out of pocket expenditure, the health Insurance coverage is still very low, restricted to mostly those on government payroll or organized private sector like banking industries and multinational companies amongst others. In this study, the parents were of low socioeconomic status and can be influenced by the factors that affect the health seeking behavior of rural dwellers. Although some were literate but can still be influenced by religious and other sociocultural believes.

UNDER PEER REVIEW

CONCLUSION

Tibial Hemimelia is a rare deformity worldwide with numerous treatment options with guided outcomes. Poverty, religious beliefs, denial of reality and poor socioeconomic status are some of the challenges affecting the management of these conditions. There is need for a change in Government policies regarding budgetary provision for health and Education with the improvement in the poverty index of the country.

UNDER PEER REVIEW

REFERENCES

1. Litretta J, Young M, Birch JG, Oetergen M. Congenital tibial deficiency. *Journal of American Academy of Orthopaedics Surgeons* March 2019; 27 (6); 268 – 279
2. Dror Paley. Tibial Hemimelia: New Classification and Reconstructive Techniques. *J Child Orthop* Dec 2016; 10(6): 529 – 555
3. Orimolade EA, Ikem IC, Ogini LM, Odunsi AO. Femoral bifurcation with Ipsilateral tibial hemimelia: Early outcome of ablation and prosthetic fitting. *Niger J clin pract* 2011; 14(4): 492 – 494
4. Fernandez-Pallazzi F, Bendahan J, Rivas S. Congenital Deficiency of tibia. *Journal of Paediatric Orthopaedics B*. Oct 1998; 7(4): 298–302
5. Courvoisier A, Salhan F, Thevenin-Lemoine C, Vialle R, Damsin JP. Congenital Tibial Deficiencies Treatment using Illizarrovs Frame. *Orthop Traumatol Surg Res*. Oct 2009; 96(6): 431 – 6
6. Ondari J, Kinyanju J, Maru M. Femoral Bifurcation and bilateral tibial hemimelia: A case report. *Pan African Medical Journal*. 2018; 30: 99
7. Spiegel DA, Loder RC, Crandal RC. Congenital longitudinal deficiency of the tibia. *Orthop* 2003; 27(6): 338 – 342
8. Jones D, Barnes J, Lloyd-Roberts GC. Congenital aplasia and dysplasia of tibia with intact fibula: Classification and management. *J Bone Joint Surg Br* 1978; 60(1): 31 – 39
9. Parley D, Herzenberg JE, Gillespie R. Limb deficiency. In Stageli LT, editor *pediatric orthopedic secrets 2*. Philadelphia: Hanley and Belfus 2003; 406 – 416
10. Epps Ch jr, Troons RE, Edholm CD, Kruger LM, Bryant DD 3rd. Failure of centralization of fibula for congenital longitudinal tibial deficiency. *J Bone Joint Surg Am* Jul 1991; 73(6): 858 – 867
11. Brown FW. The Brown operation for total hemimelia tibia: In Aitken GT (ed) *Selected lower limb anomalies*. National Academy of Sciences, Washington DC 1971; 20 – 28
12. Jayakumar SS, Eilet RE. Fibula transfer for congenital absence of the tibia. *Clin Orthop Relat Res* 1979; 139: 97 – 101
13. Geoffrey. R Swain. How does economic and social disadvantage affect Health? *Focus Newsletter* Vol. 33, No. 1, Fall/Winter 2016–17
14. Ojua TA, Ishor DG, Ndom PJ. African Cultural Practices and Health implications for Nigeria Rural Development. *Int Rev of Management and Business Research* Mar 2013; 2(1): 176 – 83
15. Asuquo JE, Abang IE, Okokon EO, Anisi CO, Lasebikan OA, Asuquo BJ et al. Does Weather Conditions Influence the Epidemiology of Paediatric Orthopedic Trauma in Southern Nigeria? *AJORR* 2020; 3(2): 22 – 29

16. Salinas-Torres BS, Barajas-Barajas LO, Perez-Garcia N, Perez-Garcia G. Bilateral tibial hemimelia type 1 (1a and 1b) with T9 and T10 hemivertebra: a novel association. Sao Paulo Med J 2013; 131(4): 275 – 278
17. Fujii H, Doi K, Baliarsing AS. Transtibial Amputation with plantar flap for congenital tibial deficiency. Clinic Orthop Relat Res Oct 2002; 403: 186 – 190

UNDER PEER REVIEW