

Case report

“A Case report on Key to Gastric Outlet Obstruction”

ABSTRACT

BACKGROUND: This case report discusses our experience of managing a rare case of metal key ingestion with incidental finding of gastric outlet obstruction by trial of endoscopy followed by surgery.

PRESENTATION OF CASE: A 21 years old male prisoner presented with history of ingestion of metallic key and vomiting for 2 days with no history of abdominal distension. Clinical examination was unremarkable. Serial radiographs were taken and monitored for the movement of foreign body and patient was posted for endoscopic retrieval of foreign body. Key was not found; pyloric stenosis was noted and procedure was hence abandoned. Repeat radiographs were taken and it appeared to be in the small intestine in the pelvis. After CECT abdomen and pelvis, it was found that the foreign body was in stomach which was over distended reaching till the pelvis due to gastric outlet obstruction. Patient had undergone gastrotomy with key retrieval with gastrojejunostomy with truncal vagotomy with feeding jejunostomy. Patient had an uneventful recovery and was discharged on post operative day 25.

DISCUSSION: Acute inflammation of pylorus can lead to gastric outlet obstruction manifested by early satiety, anorexia, weight loss, nausea, vomiting. In chronic inflammation, stomach can become massively dilated and lose its muscular tone. 12% of patients with peptic ulcer presented with gastric outlet obstruction as a direct consequence of a pyloric canal ulcer with associated pylorospasm.

CONCLUSION: Asymptomatic presentation of gastric outlet obstruction is rare, and hence, should be kept in mind in such situations of retained foreign body where it can cause acute inflammation and exacerbate gastric outlet obstruction.

Key words: key, endoscopy, gastric outlet obstruction, gastrojejunostomy.

INTRODUCTION:

Foreign body ingestion in adults is relatively uncommon. Unintentional ingestions are usually those of meat or fish bones. Intentional ingestion is mostly observed in people who are intellectually impaired, have psychiatric illness, prisoners or edentulous. Gastric outlet obstruction can be due to extrinsic and intrinsic factors. Rarely, a retained foreign body can cause acute inflammation and exacerbate gastric outlet obstruction³. According to American Society for Gastrointestinal Endoscopy guideline for management of ingested foreign bodies, 80%-90% of foreign bodies reaching the gastrointestinal tract will pass spontaneously, 10%-20% require endoscopic intervention and 1% require a surgical procedure. We present you a case of foreign body ingestion with incidental finding of gastric outlet obstruction in a prison inmate^{1,2}.

PRESENTATION OF CASE:

History: A 25 years old male prisoner with a history of two days old intentional ingestion of metallic key presented to emergency department with complaints of multiple episodes of vomiting containing undigested food particles, with no history of abdominal distension.

Clinical examination: Unremarkable.

Commented [A1]: Kindly mention what is rare in this case.??? Foreign body ingestion is very common

Commented [A2]: Why it was incidental finding?

Commented [A3]: Can the author know the exact age of the patient?

Commented [A4]: Specify percentage and give reference

Commented [A5]: Kindly clarify the age of the patients. It is written 21 years in the abstract.

Investigations: Radiological investigations were done to confirm the foreign body. Serial radiographs were taken at 6 hours for the first 2 days and 12 hours interval thereafter to confirm its position in the gastro intestinal tract. Gastric outlet obstruction was diagnosed during the attempt of endoscopic retrieval and procedure was abandoned.

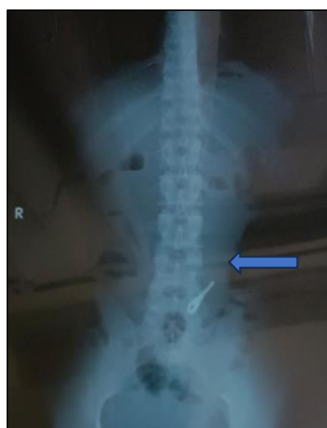

Fig 1: Erect X Ray abdomen showing foreign body in stomach.

Contrast enhanced CT scanning of abdomen and pelvis was done for confirmation of site in the stomach which was distended reaching till the pelvis.

MANAGEMENT: A decision is made to remove the foreign body via endoscopic method under sedation. Food stasis was noted in stomach with pinpoint pylorus, scope couldn't be negotiated beyond pylorus, key couldn't be visualised-PARTIAL GASTRIC OUTLET OBSTRUCTION WITH RETAINED FOREIGN BODY.

After this failed attempt, patient had undergone gastrotomy with retrieval of key with gastrojejunostomy with truncal vagotomy with feeding jejunostomy. Recovery was uneventful with drain removal on post op day 7, feeding jejunostomy on post op day 21 and discharged on post op day 25.

Commented [A6]: Why endoscopic retrieval was not attempted within first 24 hrs ?

Commented [A7]: Can the author provide details
1. Why CT scan not done before the endoscopic attempt?
2. Reason for endoscopic retrieval abandoned?

Commented [A8]: Kindly provide representative images of CT Abdomen .

Commented [A9]: Kindly provide endoscopic images supporting your findings .

Commented [A10]: Kindly give the reason
1. What was the reason for gastrotomy?
2. Why adequate stomach wash with a nasogastric tube and a second attempt of endoscopic retrieval was not done? Which may prevented major surgery.
3. What was the reason for gastric outlet obstruction in your patient? Because primary pathology was never addressed in your patient, as you have not taken an endoscopic biopsy and did not mention a histopathology report.
4. In your patient gastrotomy with removal of foreign body and gastrojejunostomy was done, without histopathology diagnosis of gastric outlet obstruction. What if turns out to be a malignant lesion?
5. It is not clearly mentioned if surgery was emergency or elective.
6. Kindly mention why feeding jejunostomy was performed after gastrojejunostomy. Any specific reason??

Commented [A11]: Why patient was admitted to 21 post-op days in the hospital?

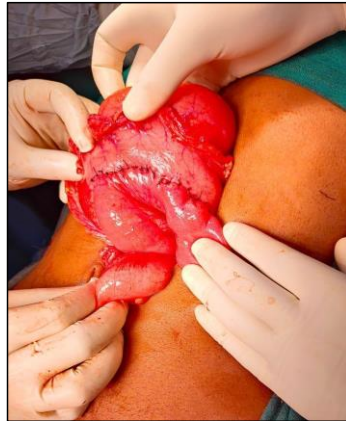
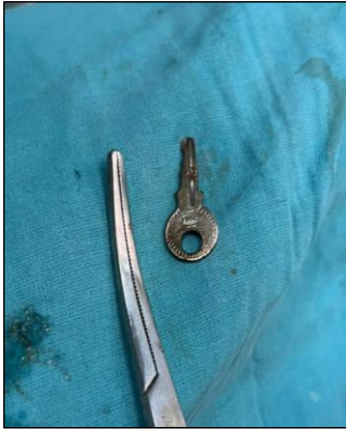
Fig 2 and 3: Image showing retrieved foreign body(key) and gastrojejunostomy post retrieval.

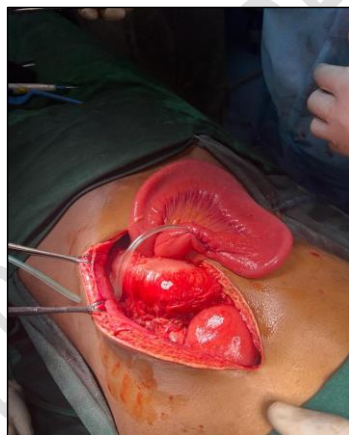


Fig 4: Image showing feeding jejunostomy

DISCUSSION:

Management of foreign body ingestion is influenced by the patient's age and clinical condition, size, shape and classification of the ingested material, the anatomic location in which the object is lodged and the technical abilities of the endoscopist⁵. There are 3 sites where an object may fail to pass once it has negotiated-cricopharynx, the upper oesophageal sphincter is the narrowest part of the upper GI tract, the pylorus in the stomach, the ileocecal valve.

Commented [A12]: 1.The discussion is very vague. No scientific information is provided by the author in the discussion.

2.Need major revision

Acute inflammation of the pylorus can lead to gastric outlet obstruction manifested by early satiety, anorexia, weight loss, nausea, vomiting. In chronic inflammation stomach can become massively dilated and lose its muscular tone³. 12% of patients with a peptic ulcer presented with gastric outlet obstruction as a direct consequence of a pyloric canal ulcer with associated pylorospasm⁴.

CONCLUSION:

Gastric outlet obstruction due to foreign body itself is a rare presentation as in most cases it traverses the gastrointestinal tract without symptoms. Once identified through imaging studies, prompt investigation should take place with EGD. We report a case of foreign body gastric outlet obstruction that was successfully treated with endoscopic/surgical procedure.

Commented [A13]: This is not rare.
Do you have any references to called this a rare

Commented [A14]: I think your patient already had gastric outlet obstruction which was asymptomatic or partial or not investigated prior.
Recent history of foreign body ingestion is another thing, it just merely brought our attention to first condition.

Commented [A15]: Kindly correct spelling mistakes

REFERENCES:

1. American Society for Gastrointestinal Endoscopy. Guideline for the management of ingested foreign bodies. *Gastrointestinal Endoscopy* 1995; 42:622-5.
2. Kirk AD, Bowers BA, Moylan JA, et al. Toothbrush swallowing. *Arch Surg* 1988; 123:382-4.
3. Wahbeh G, Wyllie R, Kay M. Foreign body ingestion in infants and children: location, location, location. *Clin Pediatr (Phila)* 2002; 41:633-40.
4. Eisen GM, Baron TH, Dominitz JA, et al. Guideline for the management of ingested foreign bodies. *Gastrointestinal Endoscopy* 2002; 55:802-6.
5. Trivarna Dey, Manjunath B.D and Niyaz Ahmed et al. A Case Report on Challenges in Retrieving an Ingested Mobile Phone *AJCRS* 120553, 2024; vol. 7 (2):378-82.

Commented [A16]: Kindly give recent and relevant references