

Non-Invasive Management of Penile Strangulation: A Novel Surgical Approach Without Cutting Tools

Abstract

Penile strangulation is an unusual clinical condition that was first reported in 1755 by Gauthier. It is a type of a compartment syndrome, which requires urgent treatment to maintain vascularity of the corporal bodies. Metallic or non-metallic objects are the most common cause of penile strangulation.

Penile strangulation is a rare clinical entity which may lead to serious complications if not treated promptly and judiciously. The reasons for applying foreign bodies to the external genitals are varied and depend on the patient's age group. In middle-aged and elderly men, the leading cause of application of foreign bodies is to increase sexual performance or because of autoerotic intentions, while masturbation and sexual curiosity are the leading causes in male adolescents. In infants and children, the foreign body is usually a string, thread, rubber band, or hair tied around the penis. In some patients, different concomitant psychiatric abnormalities were registered.

These objects constrict the penis, obstructing blood and lymphatic flow, leading to strangulation. Early removal of the constricting object and restoration of blood supply is critical, as delays can cause irreversible damage, gangrene, sepsis, or even death.

Herein, we present a rare case of penile strangulation caused by a metal pipe. The metal pipe was successfully removed with a novel surgical procedure without cutting metal pipe, allowing the patient to regain normal penile function, including erection.

Key words

Foreign body, incarceration, Penile strangulation, String method

Introduction

Penile strangulation, or incarceration is a rare medical emergency that requires prompt intervention to relieve pressure and restore normal blood flow to the penis. The objects causing strangulation can be metallic or non-metallic and are often used in attempts to enhance sexual performance or prolong erection. When the penis becomes trapped by a constricting object, it leads to swelling in the area beyond the obstruction due to the initial blockage of venous return and impaired blood supply. [1,2,4]

If left untreated for several hours, penile strangulation can cause severe complications such as penile oedema, ischemia, tissue necrosis, and even gangrene. The encircling object prevents proper venous drainage, which can result in significant enlargement of the penis due to lymphedema. Over time, the lack of oxygen caused by venous stasis can lead to tissue death. In addition, patients may develop skin and urethral injuries, constriction of the corpora spongiosum and corpora cavernosa, urethral fistulas, and loss of sensation in the distal penis, potentially progressing to gangrene. [3,4,5]

Case Report

A 37-year-old married man presented to our centre on December 12, 2021, with penile strangulation. The patient broke the handmade sleeping bed. The patient had inserted his penis into

a metal pipe during the night, in an attempt at self-sexual stimulation. He inserted his penis into a metal pipe that was attached to the bed frame. However, after placing the metallic pipe around his penis, he was unable to remove it from the swollen penile shaft. After six hours, the penile oedema worsened, causing severe pain and an inability to pass urine. Despite his best efforts, the patient could not remove the metal pipe. The patient was referred to our hospital at 7 a.m. for removal of the metal object.

Upon admission, the patient was immediately taken to the emergency operating theatre. He was hemodynamically stable but visibly anxious and fearful. On examination, a metal pipe encircled the proximal shaft of the penis, measuring 2 inches in length, 2 inches in diameter, and 0.3 cm thick. There was significant oedema and congestion of the penile shaft and prepuce distal to the metal pipe. His penile size had increased by an additional 1.5 inches, so it was unable to remove the strangulated penis.

We arranged for an electrical metal-cutting drill from outside the hospital, but I was determined to remove the object without cutting the pipe. Using a novel surgical approach under spinal anaesthesia, we proceeded without cutting the metal. In the first step, multiple needle punctures were made on the oedematous penile skin using 16–18-gauge needles to reduce the swelling. In the second step, two needles were inserted into the corpora spongiosum and corpora cavernosa to drain blood from the erectile tissue. In the third step, gentle pressure was applied to the penis with both hands. Sero-sanguineous fluid was drained through the punctures, leading to the complete decompression of the swollen penile shaft and glans. After reducing the penile size, we applied xylocaine jelly to the shaft of penis and successfully removed the metal pipe without cutting it, completing the procedure within 30 minutes.

Following the removal, there were minor abrasions and ecchymosis on the shaft of the penis. The patient was able to pass urine normally, and there were no signs of internal injury, urethral damage, or urethrocutaneous fistula. He was discharged on postoperative day 3 with advice for regular dressing, oral anti-inflammatory medication, and antibiotics.

At the 4-week follow-up, the wound had healed well, and the patient reported no urinary symptoms, erectile dysfunction, or priapism. (Fig 1-6)

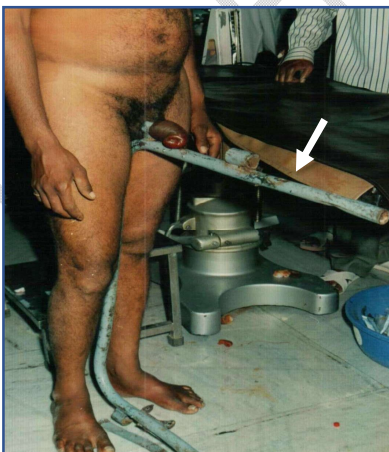

Fig-1 Photograph showing Penile strangulation in the metal pipe

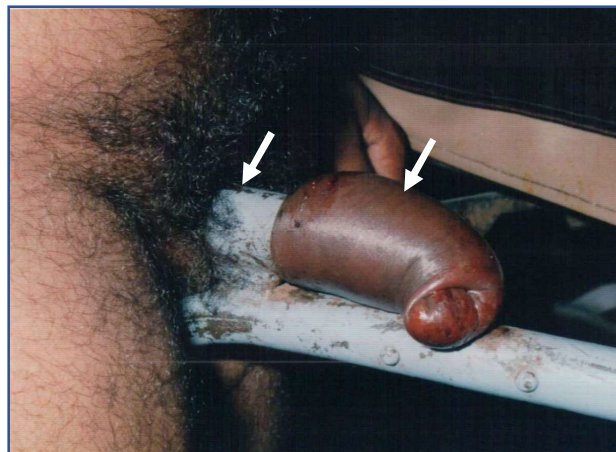

Fig-2 Photograph showing strangulated distal edematous penis and prepuce

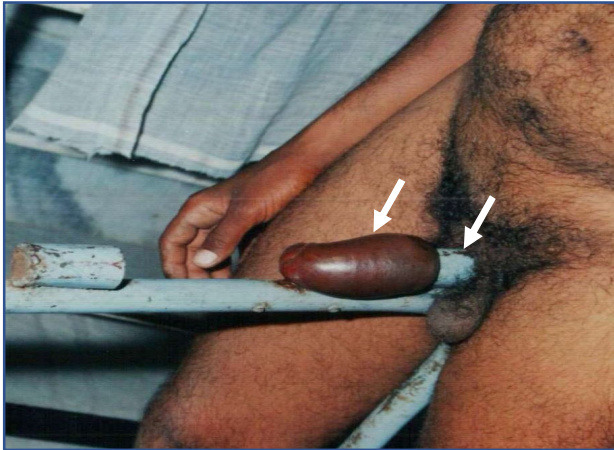

Fig-3 Photograph showing strangulated engorged penis distal to metal pipe

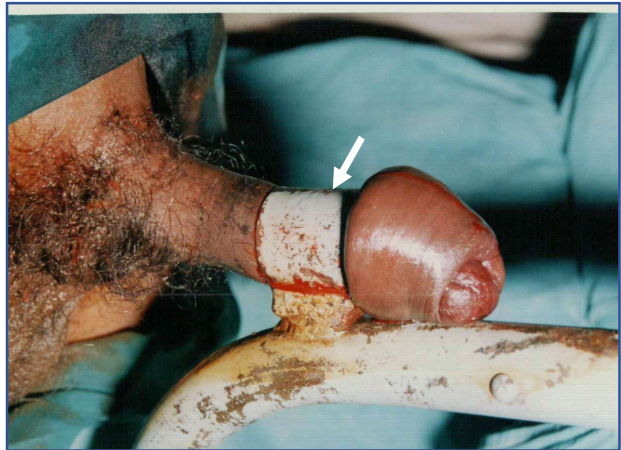


Fig-4 Photograph showing after reduction of penile size

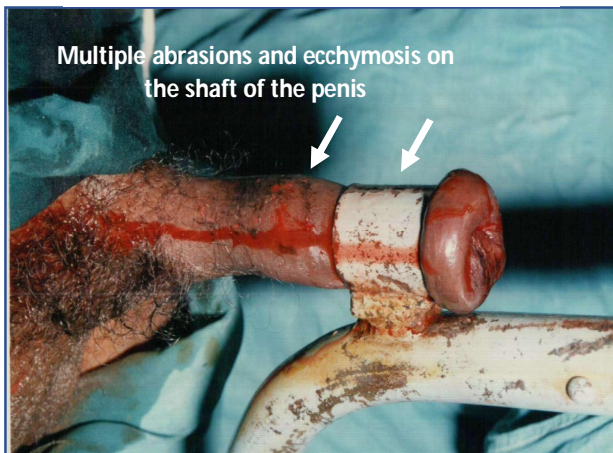


Fig-5 Photograph showing removal of metallic pipe after reduction of oedema

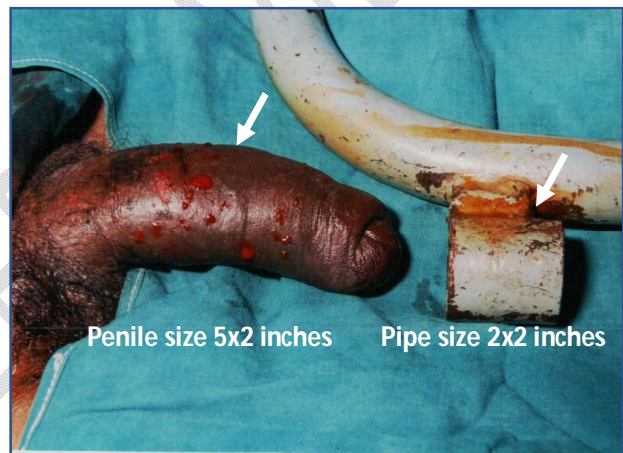


Fig-6 Photograph showing successful removal of metal pipe

Discussion

Fewer than 100 cases of penile strangulation have been reported in the literature. The primary goal of management is the early and safe removal of the foreign object, along with the treatment of any associated injuries. [1,2,7]

Pathophysiology

When objects are applied to a flaccid penis, they can obstruct venous and lymphatic outflow, leading to penile enlargement. As the penis swells and the shaft increases in girth, removing the object becomes difficult, despite it being easy to place initially. The increased pressure caused by lymphatic obstruction and venous congestion creates a continuous constrictive force, leading to a compartment-like syndrome. This eventually obstructs arterial blood flow to the distal part of the penis, causing strangulation. If the object is not removed in a timely manner, strangulation can result in soft tissue ischemia, necrosis, local infection, and gangrene. [1,2,6]

In 1991, Bhat et al. classified these penile injuries based on severity:

- **Grade I:** Oedema of the distal penis with no skin ulceration or urethral injury.
- **Grade II:** Injury to the skin and constriction of the corpora spongiosum, but no urethral injury or loss of distal penile sensation.
- **Grade III:** Injury to the skin and urethra, but no urethral fistula; loss of distal penile sensation.
- **Grade IV:** Complete division of the corpus spongiosum, resulting in a urethral fistula.
- **Grade V:** Gangrene, necrosis, or auto-amputation of the distal penis. [2,3,7]

Local assessment should include recording the skin temperature, colour, penile sensation, and pulsation distal to the site of strangulation. The penis should be examined for any urethral injury or signs of urinary leakage from the ventral aspect, which could indicate the development of a urethrocutaneous fistula. Ultrasound with colour Doppler can be used to assess vascularity and blood flow. [2,5,9]

Key Highlights:

1. Penile strangulation requires emergency intervention to preserve organ function.
2. Each case must be managed individually, based on clinical findings and the operative setting.
3. Treatment depends on the type and size of the constricting object, the time elapsed since incarceration, the degree or grade of injury, the available instruments, and the surgeon's experience.
4. Different methods and tools may be needed depending on the circumstances and unique aspects of each case.

Early removal of the constricting object and restoration of venous, lymphatic, and arterial flow is critical to prevent ischemic damage to the penis and urethra. Treatment methods are generally categorized into four groups: [1,2,3,4]

1. **String or thread Method:** This involves using a silk thread or latex strip to compress the swollen area, allowing the ring to slide off. Aspiration of blood and oedema fluid may also be used. This technique is effective for grade I, II, and III injuries, achieving decompression without tissue damage.
2. **Aspiration Method:** Needles are used to aspirate blood from the glans and corpus cavernosa or to perform subcutaneous punctures with 16–18-gauge needles to drain lymph and serosanguineous fluid. This reduces penile oedema and aids in decompression.
3. **Ring Cutting:** Various cutting tools, both manual and electric, can be used, including orthopaedic equipment, ring cutters, metal shears, hammers, chisels, or drills. When using an electric drill, cold water irrigation is necessary to prevent heat-related injury to the skin and tissue.
4. **Decompression Surgery:** Recommended for grade V injuries, this method involves cutting Buck's fascia and using skin grafts. In severe cases, degloving of the penis may be required to remove the constricting object, followed by skin grafting. [6,7,8,11]

Penile strangulation requires urgent treatment to avoid complications. The goal is to remove the constricting object and restore blood flow and urethral continuity. Psychiatric counselling may also help prevent future incidents. [1,2,5]

Conclusion

Penile strangulation is a rare but serious urological emergency that requires immediate medical attention. Timely removal of the constricting object is crucial to prevent irreversible damage to the penis and urethra.

The primary goal of management is the early and safe removal of the foreign object, along with the treatment of any associated injuries. Treatment strategies depend on the type and size of the object, the duration of incarceration, the degree of injury, available instruments, and the surgeon's expertise.

Disclaimer (Artificial intelligence)

Option 1:

Author(s) hereby declare that NO generative AI technologies such as Large Language Models (ChatGPT, COPILOT, etc.) and text-to-image generators have been used during the writing or editing of this manuscript.

Option 2:

Author(s) hereby declare that generative AI technologies such as Large Language Models, etc. have been used during the writing or editing of manuscripts. This explanation will include the name, version, model, and source of the generative AI technology and as well as all input prompts provided to the generative AI technology

Details of the AI usage are given below:

- 1.
- 2.
- 3.

References

1. Sarkar D, Gupta S, Maiti K, Jain P, Pal DK. Penile strangulation by different objects and its removal by the modified string method: Management of four cases with review of literature. Urol Ann. 2019 Jan-Mar;11(1):1-5. doi: 10.4103/UA.UA_178_17. PMID: 30787563; PMCID: PMC6362780.
2. Bambang SasongkoNoegroho, Safendra Siregar, Rizky Ramdhani, Bernard Partogu, Akhmad Mustafa, Penile strangulation injury by metallic ring: A study of 4 cases, International Journal of Surgery Case Reports, <https://doi.org/10.1016/j.ijscr.2021.01.103>.
3. Mandal RK, Ghosh SK, Sarkar S. Penile strangulation: A case report of a potentially serious emergency condition in a young male. Indian J Sex Transm Dis AIDS. 2020 Jan-Jun;41(1):127-128. doi: 10.4103/ijstd.IJSTD_87_16. Epub 2020 Jun 18. PMID: 33063002; PMCID: PMC7529160

4. Rohith G, Dutta S, G. S. S (October 05, 2020) A Rare Case of Penile Strangulation by a Hard Plastic Bottleneck. *Cureus* 12(10): e10814. doi:10.7759/cureus.10814
5. Agrawal, M., Gite, V.A. & Sankapal, P. Two cases of penile strangulation: varied presentations and vastly different outcomes. *Afr J Urol* 26, 46 (2020). <https://doi.org/10.1186/s12301-020-00057-2>
6. Gazzah, Wael MD; Mzoughi, Mahdy MD; Lahouar, Rayen MD; Najjai, Yassine MD; Naouar, Sahbi MD; Salem, Braiek MD. Innovative techniques in the treatment of penile strangulation: a case report. *Annals of Medicine & Surgery* 86(6):p 3748-3752, June 2024. | DOI: 10.1097/MS9.000000000000210
7. Hamza Ichaoui, Sataa Sallami, Ahmed Samet, Zied Bokai, and Hassan Touinsi, Strangulation of the Penis by a Metallic Ring: Prevention Is Better Than Cure, *Hindawi Case Reports in Urology* Volume 2018, Article ID 1725752, 4 pages <https://doi.org/10.1155/2018/1725752>
8. Mani, Utsav Anand & Tripathi, Pranjal & Sarangan, Vikram & Abbas, Haider & Mule, Sanjay & Kumar, Mukesh & Alam, Sharique & Krishan, Uday & Goyal, Devansh & Alam, Mohd & Raza, Syed & Saalim, Mohd. (2024). Penile Strangulation. 10.5005/njem-11015-0023.
9. Acharya GB, Baral S, Poudel A, Neupane A, Kandel K. Penile strangulation, a study of two cases. *Int J Surg Case Rep.* 2022 May;94:107100. doi: 10.1016/j.ijscr.2022.107100. Epub 2022 Apr 21. PMID: 35468381; PMCID: PMC9052140.
10. Kevin J. Campbell, Elizabeth P. Kwenda, Shahab Bozorgmehri, Russell S. Terry, Lawrence L. Yeung, Penile Strangulation: Analysis of Postextrication Follow-Up, Sequelae, and a Review of Literature, *American Journal of Men's Health*, 10.1177/15579883231223366, 18, 1, (2024).
11. Kumar P, Lavania P (2019) Penile Strangulation due to a Metallic Foreign Body: A Case Report. *Surgery Curr Res* 8: 325. doi: 10.4172/2161-1076.100032
12. Young Gon Kim, Yu Seob Shin, Jae Hyung You, Penile Strangulation: A Novel Surgical Procedure without Cutting Equipment, *Urogenit Tract Infect* 2020 Apr;15(1):10-
<https://doi.org/10.14777/uti.2020.15.1.10>