

Original Research Article

Toxicity of Two Therapeutants Hydrogen Peroxide and Formalin in Nile tilapia (*Oreochromis niloticus*)

Abstract:

The FDA has granted approval for the chemical's hydrogen peroxide and formalin for use in aquaculture. The toxicity of these two compounds was evaluated in the current study for freshwater Nile tilapia (*Oreochromis niloticus*) weighing 75 ± 2.5 g. For 96 hours, ten fish each were subjected in triplicate to concentrations of hydrogen peroxide at 0 ppm, 150 ppm, 250 ppm, 350 ppm, 450 ppm, and 600 ppm. Similarly, for 96 hours, 10 fish each were subjected in triplicate to the following concentrations of formalin: 0 ppm, 50 ppm, 100 ppm, 150 ppm, 200 ppm, 250 ppm, 300 ppm, 350 ppm, 400 ppm, and 450 ppm. Every day, the mortality rate was noted. Each chemical's LD50 was determined using the non-linear regression approach. Hematological parameters, such as white blood cells, red blood cell, hemoglobin, and thrombocyte number as well as serum parameters, such as ALT, AST, creatinine, and BUN, and enzymes that inhibit free radicals, such as SOD, CAT, and GSH, were determined after blood and liver tissue was drawn. The liver, muscle, gills, and heart histopathology were completed after the fish were put to death. The LC50 values for formalin and hydrogen peroxide were found to be 231.2 µg/ml and 314.6 µg/ml, respectively. Sublethal concentrations of hydrogen peroxide significantly increased hematological parameters such as total WBC, RBC, hemoglobin, and thrombocyte count, and serum parameters such as ALT, AST, creatinine, and BUN, while antioxidant enzymes such as SOD, CAT, and GSH significantly decreased. Fish exposed to formalin had significantly higher levels of ALT, AST, creatinine, and BUN, and significantly lower levels of antioxidant enzymes. Histology of the tissue of muscles of fish that were exposed to sublethal concentrations of two chemicals showed hyperplasia, lamellar fusion of the gills, infiltration of hemocytes and muscular atypia in the heart, and separation of muscle fiber bundles in the liver.

Keywords: Therapeutant, Nile tilapia, Hydrogen Peroxide, Formalin

• Introduction

Aquaculture is defined as "the organized cultivation of aquatic creatures, such as finfish, crustaceans, molluscs, and aquatic plants, in freshwater, seawater, brackish water, and inland saline water" (FAO, 2006). As of 2020, the industry is regarded as one of the world's fastest-growing food production systems, accounting for around 52% of worldwide fish and invertebrate production and 97% of total seaweed production. Globally, aquaculture has expanded and intensified at an incredible rate, much exceeding the annual growth rate of terrestrial livestock and dairy production, which reached an all-time

high in 2018 (FAO, 2020).

Infectious diseases present a major constraint on aquaculture production, causing high mortality levels and impaired growth due to infection. Antimicrobials (natural or synthetic origin) that are sufficiently non-toxic to the host are generally used as chemotherapeutic agents for the treatment of infectious diseases and as prophylactic agents in aquaculture (Baticados and Paclibare, 1992; Kumar and Roy, 2017). Additionally, antibiotics are utilized in aquaculture as preventative or therapeutic interventions (Subasinghe et al., 2005). Since antibiotics can be highly costly and accumulate in the tissues of aquatic animals, their use in aquaculture creates public health issues due to the spread of antimicrobial resistance.

In order to control the external infections of farmed fish, there is only one FDA approved therapeutic chemical (Formalin) and three Low Regulatory Priority substances (sodium chloride, hydrogen peroxide, and acetic acid) (Singh and Singh, 2018). External bacteria and parasites may be successfully controlled by hydrogen peroxide (Speare & Arsenault, 1997, Arndt and Wagner, 1997; Lumsden *et al.*, 1998; Avendaño-Herrera *et al.*, 2006; Bowker et al., 2012). Hydrogen peroxide has been considered as a 'green' therapeutant which do not contribute residues to the environment (Lieke et al., 2020). Formaldehyde hydrate (Formalin), which has an electrophilic nature, may react with the functional groups of many biological macromolecules, including proteins, DNA and RNA, polysaccharides, and glycoproteins (Kiernan, 2000; BMA, 2015). Formalin is one of the most applied chemical therapeutant in intensive aquaculture (Francis-Floyd, 1996; Boyd & McNevin 2015). It may be used as a prophylactic measure or with therapeutic purposes and is extremely effective against most protozoan parasites (*Ichthyophthirius* spp., *Costia* spp., *Epistylis* spp., *Chilodonella* spp., *Scyphidia* sp., *Trichodina* spp.) and monogenetic trematodes (*Cleidodiscus* spp., *Gyrodactylus* spp. and *Dactylogyrus* spp. (FDA 1995; Francis-Floyd, 1996; Shao, 2001).

- **Materials and Methods:**

- **Experimental animals:**

In total, 480 disease-free, healthy fish (*O. niloticus* of size 84.51 ± 22.59 gm) were used in the experimental investigation. These fish were obtained from Perumbavoor, Ernakulam, Kerala, during the second week of August 2022. According to the requirements set forth by CPCSEA for Experimentation on Fishes, 2021, the entire study was conducted in an environment with sufficient management, operation, care, and maintenance facilities (No. 1174/ac/08/CPCSEA). The experiment was carried out in the wet lab of the Kerala University of Fisheries and Ocean Studies (KUFOS), Panangad, Kochi, Faculty of Fisheries Science, Department of Aquatic Animal Health Management.

- **Determination of 96hr LD₅₀**

LC₅₀ of H₂O₂ and formalin for 96 hr were determined as per test no. 203 of OECD guidelines with some modifications (OECD, 2019). Ten fish were kept in 100L water in triplicate for treatments and control. The concentrations of H₂O₂ used were 0 ppm, 150 ppm, 250 ppm, 350 ppm, 450 ppm and 600 ppm. The quarantined and acclimatized fish were kept in respective tanks for 48 hours before starting the experiment. After adding respective dose of H₂O₂, water quality parameters were recorded. The water quality parameters were maintained optimum by continuous aeration and 50% water exchange. The respective dose of H₂O₂ was added daily. H₂O₂ was provided by Merck life science private limited, Mumbai. No feeding was done. Mortality in each tank was recorded daily.

In the case of formalin, the concentrations used were 0 ppm, 50 ppm, 100 ppm, 150 ppm, 200 ppm, 250 ppm, 300 ppm, 350 ppm, 400 ppm and 450 ppm. Feeding was not done. The water quality parameters were maintained optimum by continuous aeration and 50% water was exchanged and added appropriate dose daily. Formalin was provided by Emplura Merck life science private limited, Mumbai. Mortality in each tank was recorded daily.

- **Blood sampling**

After 96 hours of experiment, fishes that survived were anaesthetized by using clove oil (Eugenol) 0.5mL/L. Blood samples were collected using sterile syringes (2.5ml, 24 gauge) from caudal vein. The blood sample were collected with the addition of anticoagulant EDTA (Himedia) (1g EDTA in 10ml of distilled water, pH 8), in plastic K3 EDTA tubes (Microsidd, India) for haematological analysis and without anticoagulant in 1.5ml Eppendorf tubes for serum analysis.

- **Haematological parameters**

The haematological parameter like WBC (white blood corpuscles count), RBC (red blood corpuscles count), HGB (Haemoglobin), PLT (thrombocytes count) were analysed, using haematology analyser (Benesphera, India).

- **Serum Analysis**

The blood sample for serum analysis were allowed to coagulate at room temperature. Subsequently, the samples were centrifuged for 20 min at 3000 rpm. Blood serum was collected and stored at -20°C and used for further analysis. Blood serum concentration of alanine transaminase (ALT), aspartate transaminase (AST), creatinine (CRE) and, blood urea nitrogen (BUN) were measured using Serum Analyzer (Fuji, Japan) making use of the respective slides supplied for use in the equipment.

- **Antioxidant Enzyme Assay**

Antioxidant enzyme activity such as superoxidase dismutase, SOD (Madhesh and Balasubramanian, (1998)), catalase CAT (Sinha, 1972), Reduced glutathione (GSH) (Sedlak and Lindsay, 1968) in liver

of Nile tilapia were analysed.

- **Histology**

The muscle, liver, gill and heart tissue of Nile tilapia exposed to different concentrations of H₂O₂ and formalin were aseptically and carefully removed and fixed in 10% Neutral Formalin Buffer (NBF). The tissues were processed, sections were made and haematoxylin - eosin staining was done (Roberts,2012). The slides were observed under trinocular microscope (ZEISS, Carl Zeiss India) with camera attached (Leica, Germany) using 100X and 200X magnifications.

- **Statistical analysis**

All the data are expressed as mean \pm standard deviation (Mean \pm SD). The data were compared using a one-way analysis of variance (ANOVA). The significance level was set at P<0.05. Statistical analysis was performed with the software package SPSS 26. Post hoc tests for comparison of means were also done using the same software.

- **Results**

- **Water quality parameters in the acute toxicity test with H₂O₂**

Water quality parameters were tested after the addition of respective doses of H₂O₂ in the treatment tanks. The range of water quality parameters in were optimum and are presented in table 1.

Table 1. Water quality parameters in the acute toxicity test with H₂O₂

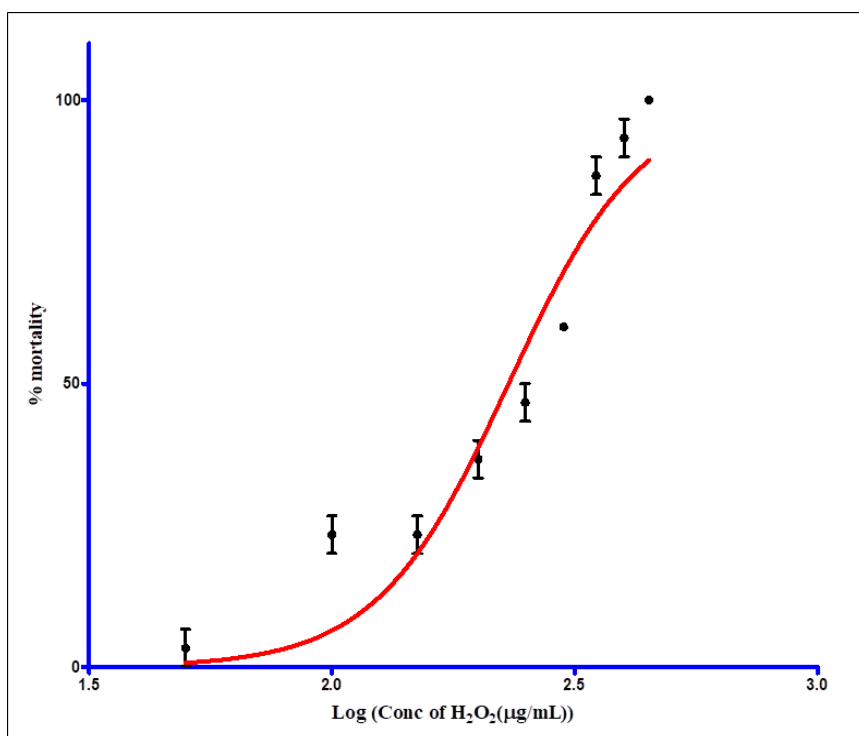
Water Quality Parameter	Control	Treatment
pH	7-7.5	7-8
Alkalinity	122-128 ppm of CaCO ₃	122-130 ppm of CaCO ₃
Hardness	160-178 ppm of CaCO ₃	157-178 ppm of CaCO ₃
Dissolved oxygen	6-9 ppm	22-28.2 ppm
Temperature	25-29°C	25-29°C
Ammonia	0.01-0.05	0.01-0.05

- **3.2. Determination of 96hr LC₅₀ of H₂O₂ in Nile tilapia**

The mean mortality rate obtained for 96 hr acute toxicity tests at various concentrations of H₂O₂ are given in table 2. The results when analysed by non-linear regression model, the log logEC₅₀ was found to be 2.498 and LC₅₀ was found to be 314.6 ppm of H₂O₂ (Figure 1).

Table 2. The mortality rates of Nile tilapia treated with different concentrations of H₂O₂.

Concentration	Mean Mortality Rate
0 ppm	0%
150 ppm	6.7%
250 ppm	26.7%
350 ppm	60%
450 ppm	83%
600 ppm	100%



- **Haematological, serological and antioxidant enzyme activity analysis of Nile tilapia exposed to H₂O₂.**

The haematological parameters such as RBC, WBC, HGB and PLT of fish from control and treatment groups are presented in table 3. The results obtained in the present study revealed that there is significant ($P \leq 0.05$) difference in hematological parameters due to lethal (≥ 250 ppm) and sublethal dosage of H₂O₂ (≤ 150 ppm). It can be observed that all the parameters increased at a dosage of 150 ppm and as the concentration of H₂O₂ increased, there is considerable reduction in all the parameters measured.

The serum parameters of *O. niloticus* when exposed to different concentrations of H₂O₂ are given in table 3. All the parameters significantly increased at a concentration of 250 ppm and beyond, compared to control. The ALT, AST, CRE and BUN of fish from control and treatment groups are presented in table 3. The results obtained in the present study revealed that there is significant ($P \leq 0.05$) difference in serological parameters due to lethal and sublethal dosage of H₂O₂. It can be observed that upto 150 ppm of H₂O₂ there is no significant increase in these parameters, but at 250 ppm and above, all the parameters significantly increased.

Activity of antioxidant enzymes such as SOD, CAT and GSH in liver of Nile tilapia exposed to different concentrations of H₂O₂ were measured. All The values are given in figure 2. SOD and GSH are given in primary axis and CAT values are given in secondary axis. GSH reduced significantly at 150 ppm and below. Catalase level at 150 ppm was similar to that of control, but increased significantly above that concentration. The SOD activity significantly reduced at 450 ppm of H₂O₂.

Table 3. Haematological and serological parameters of Nile tilapia exposed H₂O₂

Parameters	Control	150 ppm	250 ppm	350 ppm	450 ppm	F value	Sig. value
RBC ($\times 10^6/\mu\text{l}$)	1.65 \pm 0.28 ^a	1.87 \pm 0.23 ^b	1.26 \pm 0.27 ^c	1.33 \pm 0.13 ^c	1.23 \pm 0.11 ^c	4.858	0.019
WBC($\times 10^3/\mu\text{l}$)	164.3 \pm 10.42 ^a	173.33 \pm 5.13 ^a	165.5 \pm 8.08 ^a	131.9 \pm 9.05 ^b	120.7 \pm 12.2 ^b	18.813	< 0.001
HGB (g/dl)	8.56 \pm 1.15 ^a	10.76 \pm 1.24 ^a	7.23 \pm 0.64 ^b	7.36 \pm 0.75 ^b	7.53 \pm 0.80 ^b	18.813	0.005
PLT($\times 10^3/\mu\text{l}$)	58.66 \pm 4.04 ^a	64 \pm 5.46 ^a	62.66 \pm 5.8 ^a	43.33 \pm 3.05 ^b	39.66 \pm 2.51 ^b	19.863	< 0.001
AST (u/l)	157 \pm 13.45 ^a	141 \pm 19.6 ^a	224 \pm 23.64 ^b	246.3 \pm 22.0 ^b	250.3 \pm 24.3 ^b	17.637	< 0.001

ALT (u/l)	8±1.73 ^a	9.2±2.1 ^a	11.66±0.57 ^b	24±1.58 ^b	26.3±1.73 ^b	37.754	< 0.001
CRE (mg/dl)	0.16±0.03 ^a	0.16±0.04 ^a	0.23±0.03 ^b	0.26±0.01 ^b	0.34±0.03 ^b	16.179	< 0.001
BUN (mg/dl)	1.01±0.02 ^a	1.03±0.15 ^a	1.66±0.05 ^b	1.72±0.04 ^b	1.68±0.2 ^b	29.322	< 0.001

Fig. 2. Activity of antioxidant enzymes of Nile tilapia exposed H₂O₂

- Water quality parameters in the acute toxicity test of formalin in Nile tilapia**

The results of the physiochemical characteristics of the rearing water from treatment tanks with different concentrations of formalin are presented in table 4. Although addition of formalin results in reduction of oxygen content and hardness, all the values were within optimum range.

Table 4. Water quality parameters in acute toxicity test with formalin

Water Quality Parameter	Control	Treatment
pH	7-7.5	7-8
Alkalinity	122-128 ppm of CaCO ₃	100-128 ppm of CaCO ₃
Hardness	178 ppm of CaCO ₃	115-140 ppm of CaCO ₃
Dissolved oxygen	6-9 ppm	5.2 – 5.6 ppm
Temperature	25-29°C	25-29°C
Ammonia	0.01-0.05	0.01-0.05

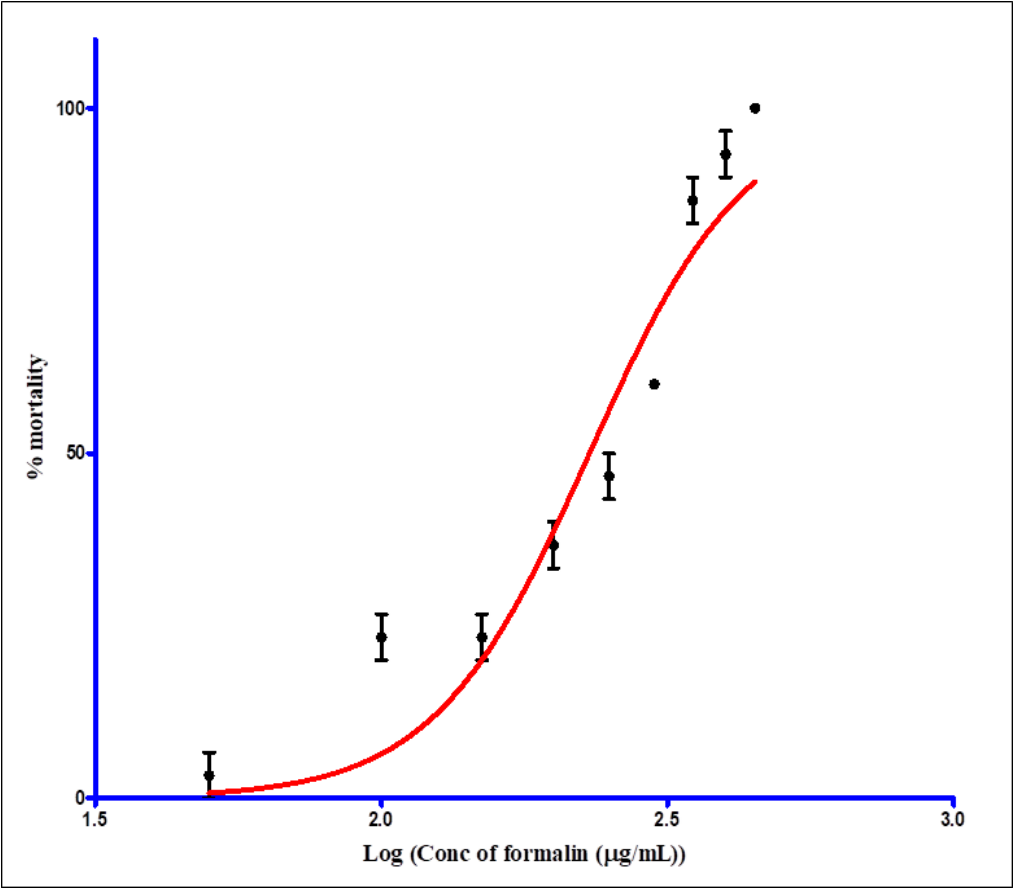
- Determination of LC₅₀ of formalin in Nile Tilapia**

The mean mortality rate obtained for acute toxicity tests at various concentrations of formalin are given in table 5. The results when analysed by non-linear regression model, the log LC₅₀ was found to be 2.364 and LC₅₀ value of formalin in Nile tilapia was found to be 231.2 ppm (Fig.3).

Table 5. The mortality rate of Nile tilapia treated with different concentrations of formalin.

Concentration of formalin	Mean of Mortality Rate
0 ppm	0%

250 ppm	46%
300 ppm	60%
350 ppm	86%
400 ppm	93%
450 ppm	100%



- **Haematological, serological and antioxidant enzyme activity of Nile tilapia exposed to formalin**

The haematological and serum parameters of *O. niloticus* when exposed to different concentrations such as 0 ppm, 50 ppm, 150 ppm and 250 ppm of formalin are given in table 6. All the parameters increased at 150 ppm and then significantly reduced ($P<0.05$) at 250 ppm. The serum parameters studied such as AST, ALT, creatinine, and BUN showed significant difference between the treatments. All the parameters are significantly increased at concentrations ≥ 150 ppm of formalin.

Activity of antioxidant enzymes such as SOD, CAT, and GSH are given in figure 4. SOD and GSH are given in primary axis and CAT values are given in secondary axis. SOD, CAT and GSH significantly reduced with increasing concentration of **formalin**.

Fig. 4. Antioxidant enzyme activity in Nile tilapia exposed to formalin

Parameters	0 ppm	50 ppm	150 ppm	250 ppm	F value	Sig. value
RBC($\times 10^6/\mu\text{l}$)	1.36 \pm 0.10 ^a	1.38 \pm 0.10 ^a	1.63 \pm 0.52 ^b	1.24 \pm 0.22 ^c	0.922	0.003
WBC($\times 10^3/\mu\text{l}$)	140.4 \pm 2.9 ^a	156.1 \pm 10.8 ^b	202.36 \pm 2.3 ^c	133.13 \pm 14.5 ^d	33.692	< 0.001
HGB (g/dl)	8.4 \pm 0.65 ^a	8.5 \pm 0.26 ^a	9.3 \pm 0.5 ^a	7.7 \pm 0.5 ^b	5.584	0.023
PLT ($\times 10^3/\mu\text{l}$)	29.66 \pm 3.2 ^a	36.66 \pm 2.08 ^a	63.33 \pm 5.7 ^b	43.66 \pm 3.2 ^c	43.291	< 0.001
AST (u/l)	128.6 \pm 16.9 ^a	138.33 \pm 8.5 ^a	159.33 \pm 17.38 ^b	178.6 \pm 32.57 ^c	3.470	< 0.001
ALT (u/l)	10.66 \pm 1.15 ^a	12.66 \pm 2.08 ^{ab}	15.66 \pm 3 ^b	21.66 \pm 1.52 ^d	16.220	< 0.001
CRE (mg/l)	1.83 \pm 0.23 ^a	1.8 \pm 0.3 ^a	2.9 \pm 0.2 ^b	3.16 \pm 0.35 ^b	19.779	< 0.001
BUN (mg/l)	0.256 \pm 0.03 ^a	0.33 \pm 0.02 ^a	0.563 \pm 0.06 ^b	0.583 \pm 0.03 ^b	48.531	< 0.001

Table 6. Hematological and Serological parameters of Nile tilapia exposed to formalin

- **Histopathology of Nile tilapia treated with H₂O₂ and Formalin**

The results obtained after haematoxylin and eosin staining of muscle tissue sections at different concentrations of H₂O₂ and formalin are given in figure 5. Figure 5A and 5B are the muscle tissues of control showing normal structure. At 150 ppm of H₂O₂, there was a marked reduction in the interfascicular space between the muscle bundles and there were focal areas of necrosis (Fig. 5C). At the lethal concentration of 350 ppm (Fig. 5D), muscle fibres were completely disorganized with increased endomycial distance and vacuolations. At 50 ppm formalin (Fig. 5E), there was marked reduction in the interfascicular space with infiltration of blood cells. At 250 ppm formalin (Fig. 5F), the muscle fibre bundles were completely disorganized and there was loss of architecture and vacuolation.

The H&E-stained liver sections are given in figure 6. The control sections reveal the presence of

melanomacrophage centres associated with liver tissue and pancreatic tubules seen distributed in hepatic tissue (Fig. 6A&B). In the liver tissue exposed to 350 ppm of H_2O_2 , (Fig. 6C), the melanomacrophage centres are almost absent and the hepatocytes are vacuolated, necrotic with karyorrhexis and pyknosis. Hyperplasia of hepatocytes is also evident. The section of liver of the fish exposed to lethal concentration of formalin (250 ppm) (Fig. 6D) shows that the cells are disoriented, hyperplastic, vacuolated, the margins of hepatocytes are not distinct and there are necrotic areas with syncytial cells.

The histological section of the gills of the healthy fish (Fig. 7A) shows well-formed secondary lamellae with erythrocytes in the centre. The filament cartilage of the primary lamellae is also well formed (Fig. 7B). In the case of fish exposed to 350 ppm of H_2O_2 (Fig. 7C), the secondary lamellae was shrunken with very few blood cells. There was sloughing of secondary lamellae from the tip of the filament. The filament cartilage was degenerated. The gills of fish exposed to 250 ppm of formalin (Fig. 7D) shows extensive infiltration of blood cells and degenerated filament cartilage.

In the control fish, the heart muscle fibres were found highly organized having blood cells (Fig. 8A&B). But in the heart tissue of the fish exposed to 150 ppm H_2O_2 , the muscle fibres were shrunk (Fig. 8C). At 350 ppm, the heart muscle cells were highly disorganized and there was heavy infiltration of blood cells into the interstitial spaces. Haemorrhage and congestion were noted. In the case of fish exposed to 250 ppm formalin, there was vacuolation, infiltration of blood cells and pericarditis (Fig. 8D).

AutoSave Off histology result Search

File Home Insert Draw Design Layout References Mailings Review View Zotero Help Comments Editing Share

3 2 1 1 2 3 4 5 6 7 8 9 10 11 12 13 14 15 16 17

A B

C D

E F

Page 1 of 1 12 words English (India) Accessibility: Investigate Focus ENG US 18:43 04-04-2023

30°C Partly sunny Search

A & B: Control; C: At 150 ppm of H₂O₂ showing necrosis (N) and decreased space between muscle fibres (arrow); D: At 350 ppm of H₂O₂ splitting of muscle fibres (S) and vacuolation (V); E: At 50 ppm formalin showing infiltration of haemocytes (H); F: At 250 ppm of formalin showing disoriented muscle fibres (O).

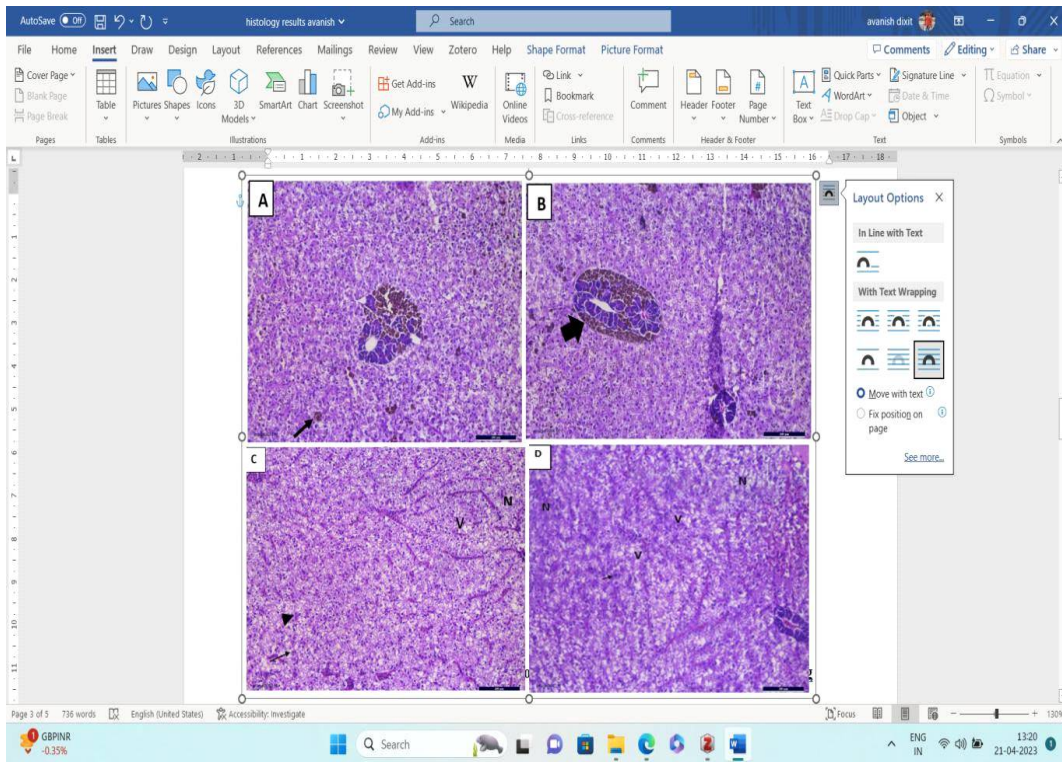


Fig. 6. Liver tissue section of Nile tilapia exposed to different concentration of H₂O₂ and formalin after exposure for 96 hrs (200X)

A&B: Control with melanomacrophage centers (MMC) (thin arrow) and pancreatic tubules (thick arrow).
C: At 350 ppm H₂O₂, there is absence of MMC, hepatocytes vacuolated (V), areas of necrosis (N),

karyorrhexis (arrowhead) and pyknosis (arrow). D: At 250 ppm of formalin, the hepatocytes are disorganized, cell membrane indistinct, syncytial cells (arrow), vacuole formation (V) and necrosis (N).

A. Bulbus arteriosus; B. Atrium; C. Heart tissue of Nile tilapia exposed to 350 ppm H₂O₂ with disorganised muscle fibers (arrow); D. Shrinking of muscle fibers exposed to 150 ppm H₂O₂; E. Heart tissue of Nile Tilapia exposed to 250 ppm formalin showing vacuolation (V) and pericarditis (arrow); F. thickening of pericardium/Pericarditis (P).

- **Discussion:**

Acute toxicity of H₂O₂ to several fish species has been determined in various studies and the LC₅₀ it was found to vary between 50 to 2010 mg/L (Clayton and Summerfelt 1996; Arndt and Wagner 1997; Rach *et al.*, 1997). Hydrogen peroxide can be toxic to fish, resulting in morbidity due to gill damage or mortality depending on the size of the fish, fish species, water temperature, concentration of the chemical, and exposure duration (Russo and Yanong, 2007). Hematological parameters of like RBC, HGB and HCT have been used as parameters of physiological stress by toxic chemicals in fish (Kawatsu, 1980; Chandrasekar and Jayabalan, 1993; Sampath *et al.*, 2003). At 250 ppm and higher concentrations all the hematological parameters significantly reduced on exposure to H₂O₂. This may be due to chemical oxidative stress to the treated fish (Soivio and Oikari 1976; Soivio and Nikinmaa 1981). Higher antioxidant enzyme gene expression after short exposure to sublethal concentrations of hydrogen peroxide have been reported in Atlantic Salmon (Vera and Miguad, 2016). Decrease of antioxidant enzymes due to H₂O₂ toxicity via intraperitoneal injection has been reported in *O. niloticus* by Jia *et al.*, (2019). The present study reveals that, at a concentration of 150 ppm of H₂O₂, the antioxidant enzyme status is increased, but at toxic levels, there is a marked reduction in the enzymes which may be due to decrease in production of these enzymes due to liver damage or due to excessive production of free radicals due to high stress, which are being scavenged by these enzymes. The damage in liver and gills may be due to the

excessive production of free radicals *via* Fenton reaction as suggested by Ayadi *et al.*, (2015).

Acute toxicity (LC₅₀—96 h) to formalin vary widely among fish species (0.1–640.0 mg/L) depending on various factors, as many fish species are sensitive to concentrations near those required for controlling and treating parasites (Tavares-Dias, 2021). According to certain protocols, formalin should be used in brief baths (lasting up to one hour) at concentrations between 150 and 250 ml/m³ or in long baths (lasting 24 hours) at concentrations between 10 and 15 ml/m³ (Thoney and Hargis 1991; Martins 2004). Increase in HGB, hematocrit and immature erythrocytes as a result of formalin exposure have been reported in carp *C. carpio* and rainbow trout *Oncorhynchus mykiss* (Smith and Piper 1972; Williams and Wootton 1981; Yamamoto 1991; Kakuta *et al.*, 1991). In the present study various serum parameters of fish such as AST, ALT, CRE and BUN were increased significantly at and above 150 ppm of formalin compared to control and 50 ppm. Increased AST and ALT activity were seen in the blood and liver tissues of fish subjected to various doses of carbaryl, monocrotophos, deltamethrin, diazinon, and malathion for varying lengths of time (Banaee *et al.*, 2011; Karmakar *et al.*, 2021). Decreased SOD activity may be a response of increased oxidative stress. The effect of Formalin on lipid peroxidation which results in the decrease in activity of antioxidant enzymes have been reported (Xu and Chang, 2007). Rainbow trout treated to formalin at various doses showed significant decreases in CAT activity throughout their entire body (Ćospir *et al.*, 2017). hyperplasia of gill lamellae and fatty degeneration in the liver were observed in silver barb (Chinabut *et al.*, 1988). Kakuta *et al.*, (1991) observed hypertrophy, hydropic degeneration and separation on the epithelial cells of gill lamella after exposed to 280 mg L⁻¹ of formalin for 2 h. These histopathological changes in the gill tissue observed in the present study were qualitatively like those reported for formalin-treated rainbow trout and chinook salmon (Wedemeyer 1971; Smith and Piper, 1972; Wedemeyer and Yasutake, 1974). Mert *et al.*, (2015) has observed secondary lamellar fusion after Formalin exposure along with hyperaemia of gill lamellae, telangiectasis on secondary lamellae branchitis at a temperature in *O. niloticus*. In the present experiment also, gills were found to be severely affected with shrinking, sloughing, and hyperaemia.

- Conclusion

To reduce the use of antibiotics and other chemicals harmful for environment and consumers, there is a need to standardise protocols with FDA approved chemicals like H₂O₂ and formalin, to treat fish diseases and as preventive measures, which is cheap on a farmer's perspective and equally effective. However, the standardisation should be done for each species, because toxicity differs in different taxa and also with the life stages. The result of the current study concluded that the therapeutic application of H₂O₂ and formalin with recommended dose 150 ppm and 50 ppm respectively is safe to treat adult *O. niloticus* for parasitic, fungal, and bacterial infections.

References:

- Arndt RE, Wagner EJ. The toxicity of hydrogen peroxide to rainbow trout *Oncorhynchus mykiss* and cutthroat trout *Oncorhynchus clarki* fry and fingerlings. *Journal of the World Aquaculture Society*. 1997 Jun;28(2):150-7.
- Avendaño-Herrera R, Magariños B, Irgang R, Toranzo AE. Use of hydrogen peroxide against the fish pathogen *Tenacibaculum maritimum* and its effect on infected turbot (*Scophthalmus maximus*). *Aquaculture*. 2006 Jun 30;257(1-4):104-10.
- Ayadi I, Monteiro SM, Regaya I, Coimbra A, Fernandes F, Oliveira MM, Peixoto F, Mnif W. Biochemical and histological changes in the liver and gills of Nile tilapia *Oreochromis niloticus* exposed to Red 195 dye. *RSC advances*. 2015;5(106):87168-78.
- Banaee M, Sureda A, Mirvaghefi AR, Ahmadi K. Biochemical and histological changes in the liver tissue of rainbow trout (*Oncorhynchus mykiss*) exposed to sub-lethal concentrations of diazinon. *Fish physiology and biochemistry*. 2013 Jun;39:489-501.
- Bartley DM. *World Aquaculture 2020—A brief overview*.
- Baticados, M.C.L. and Paclibare, J.O., 1992. The use of chemotherapeutic agents in aquaculture in the Philippines. In *Diseases in Asian Aquaculture I. Proceedings of the First Symposium on Diseases in Asian Aquaculture*, 26-29 November 1990, Bali, Indonesia (pp. 531-546). Asian Fisheries Society, Fish Health Section.
- Bowker JD, Carty D, Dotson MM. Efficacy of 35% PEROX-AID (hydrogen peroxide) in reducing an infestation of *Gyrodactylus salmonis* in freshwater-reared rainbow trout. *North American Journal of Aquaculture*. 2012 Apr 1;74(2):154-9.
- Boyd C, McNevin A. *Aquaculture, resource use, and the environment*. John Wiley & Sons; 2015 Feb 23.
- Canton H. Food and agriculture organization of the United Nations—FAO. In *The Europa directory of international organizations 2021* 2021 Jul 28 (pp. 297-305). Routledge.
- CHANDRASEKHAR S, Jayabalan N. Haematological responses of the common carp, *Cyprinus carpio* L. exposed to the pesticide endosulfan.
- Chinabut S, Limsuwan C, Tonguthai K, Pungkachonboon T. Toxic and sublethal effect of formalin on freshwater fishes. *Network of Aquaculture Centres in Asia-Pacific (NACA) WP8873*, Bangkok-Thailand-NACA. 1988.
- Clayton RR, Summerfelt RC. Toxicity of hydrogen peroxide to fingerling walleyes. *Journal of Applied Aquaculture*. 1996 Sep 17;6(3):39-49.
- Fisheries FA. *The state of world fisheries and aquaculture*. 2006
- Fisheries FA. *The state of world fisheries and aquaculture*. 2020.
- Francis-Floyd R. Use of formalin to control fish parasites. University of Florida Cooperative Extension Service, Institute of Food and Agriculture Sciences, EDIS; 1996 Apr.

- Jia R, Gu Z, He Q, Du J, Cao L, Jeney G, Xu P, Yin G. Anti-oxidative, anti-inflammatory and hepatoprotective effects of Radix Bupleuri extract against oxidative damage in tilapia (*Oreochromis niloticus*) via Nrf2 and TLRs signaling pathway. *Fish & shellfish immunology*. 2019 Oct 1;93:395-405.
- Kakuta I, Namba K, Uematsu K, Murachi S. Physiological response of the fish, *Cyprinus carpio*, to formalin exposure--I. Effects of formalin on urine flow, heart rate, respiration. *Comparative Biochemistry and physiology. C, Comparative Pharmacology and Toxicology*. 1991 Jan 1;100(3):405-11.
- Karmakar S, Patra K, Jana S, Mandal DP, Bhattacharjee S. Exposure to environmentally relevant concentrations of malathion induces significant cellular, biochemical and histological alterations in *Labeo rohita*. *Pesticide biochemistry and physiology*. 2016 Jan 1;126:49-57.
- Kawatsu H. Hematological characteristics of molinate anemia in common carp [*Cyprinus carpio*]. *Bulletin of the Japanese Society of Scientific Fisheries (Japan)*. 1980;46(9).
- Kiernan JA. Formaldehyde, formalin, paraformaldehyde and glutaraldehyde: what they are and what they do. *Microscopy today*. 2000 Jan;8(1):8-13.
- Kirici M, Yonar ME, Yonar SM. Response of antioxidant system to formalin in the whole body of rainbow trout, *Oncorhynchus mykiss*. *Cellular and Molecular Biology*. 2017 Jan 30;63(1):13-6.
- Kumar V, Roy S. Aquaculture drugs: sources, active ingredients, pharmaceutic preparations and methods of administration. *J Aquac Res Dev*. 2017;8(9):510.
- Lieke T, Meinelt T, Hoseinifar SH, Pan B, Straus DL, Steinberg CE. Sustainable aquaculture requires environmental-friendly treatment strategies for fish diseases. *Reviews in Aquaculture*. 2020 May;12(2):943-65.
- Lumsden JS, Ostland VE, Ferguson HW. Use of hydrogen peroxide to treat experimentally induced bacterial gill disease in rainbow trout. *Journal of Aquatic Animal Health*. 1998 Sep 1;10(3):230-40.
- Martins ML, De Souza VN, Moraes JR, De Moraes FR. Gill infection of *Leporinus macrocephalus* Garavello & Britski, 1988 (Osteichthyes: Anostomidae) by *Henneguya leporinicola* n. sp. (Myxozoa: Myxobolidae). Description, histopathology and treatment. *Revista Brasileira de Biologia*. 1999;59:527-34.
- Mert R, Karasu Benli AÇ, Arslan G. Determination of histological and genotoxic effects of formalin on Nile tilapia (*O. reochromis niloticus* L.). *Aquaculture research*. 2015 Nov;46(11):2798-807.
- No OT. 203: Fish, acute toxicity test. OECD guidelines for the testing of chemicals, Section. 1992;2:1-24.

- Rach JJ, Howe GE, Schreier TM. Safety of formalin treatments on warm-and coolwater fish eggs. *Aquaculture*. 1997 Mar 31;149(3-4):183-91.
- Rastiannasab A, Afsharmanesh S, Rahimi R, Sharifian I. Alternations in the liver enzymatic activity of Common carp, *Cyprinus carpio* in response to parasites, *Dactylogyrus* spp. and *Gyrodactylus* spp. *Journal of Parasitic Diseases*. 2016 Dec;40:1146-9.
- Russo R, Curtis EW, Yanong RP. Preliminary investigations of hydrogen peroxide treatment of selected ornamental fishes and efficacy against external bacteria and parasites in green swordtails. *Journal of Aquatic Animal Health*. 2007 Jun 1;19(2):121-7.
- Sampath K, James R, Velammal S. Effect of methyl parathion on blood parameters and its recovery in a catfish, *Mystus keletius*. *Indian journal of fisheries*. 2003 Apr;50(2):191-7.
- Shao ZJ. Aquaculture pharmaceuticals and biologicals: current perspectives and future possibilities. *Advanced drug delivery reviews*. 2001 Sep 1;50(3):229-43.
- Shepherd CJ, Bromage NR, editors. *Intensive Fish Farming*. 1988.
- Singh M, Singh P. Drugs and chemicals applied in aquaculture industry: A review of commercial availability, recommended dosage and mode of application. *J Entomol Zool Stud*. 2018;6(6):903-7.
- Skoet J, Stamoulis KG. The state of food insecurity in the world 2006: Eradicating world hunger-taking stock ten years after the world food summit. Food & Agriculture Org.; 2006.
- Smith CE, Piper RG. Pathological effects in formalin-treated rainbow trout (*Salmo gairdneri*). *Journal of the Fisheries Board of Canada*. 1972 Mar 1;29(3):328-9.
- Soivio A, Nikinmaa M. Swelling of erythrocytes in relation to the oxygen affinity of the blood of the rainbow trout, *Salmo gairdneri* Richardson. *Stress and fish*. 1981;1981.
- Soivio A, Oikari A. Haematological effects of stress on a teleost, *Esox lucius* L. *Journal of fish biology*. 1976 May;8(5):397-411.
- Speare DJ, Arsenault G, MacNair N, Powell MD. Branchial lesions associated with intermittent formalin bath treatment of Atlantic salmon, *Salmo salar* L., and rainbow trout, *Oncorhynchus mykiss* (Walbaum). *Journal of Fish Diseases*. 1997 Jan;20(1):27-33.
- Subasinghe R. Disease control in aquaculture and the responsible use of veterinary drugs and vaccines: the issues, prospects and challenges. *Options Méditerranéennes*. 2009;86:5-11.
- Tavares□Dias M. Toxicity, physiological, histopathological and antiparasitic effects of the formalin, a chemotherapeutic of fish aquaculture. *Aquaculture Research*. 2021 May;52(5):1803-23.
- Thoney DA, Hargis Jr WJ. Monogenea (Platyhelminthes) as hazards for fish in confinement. *Annual Review of Fish Diseases*. 1991 Jan 1;1:133-53.
- Vera LM, Migaud H. Hydrogen peroxide treatment in Atlantic salmon induces stress and

- detoxification response in a daily manner. *Chronobiology International*. 2016 May 27;33(5):530-42.
- Wedemeyer G, Yasutake WT. Stress of formalin treatment in juvenile spring chinook salmon (*Oncorhynchus tshawytscha*) and steelhead trout (*Salmo gairdneri*). *Journal of the Fisheries Board of Canada*. 1974 Feb
 - Williams HA, Wootten R. Some effects of therapeutic levels of formalin and copper sulphate on blood parameters in rainbow trout. *Aquaculture*. 1981 Jan 1;24:341-53.
 - X Xu BJ, Chang SK. A comparative study on phenolic profiles and antioxidant activities of legumes as affected by extraction solvents. *Journal of food science*. 2007 Mar;72(2):S159-66.
 - Yamamoto KI. Effects of formalin on gas exchange in the gills of carp *Cyprinus carpio*. *Comparative Biochemistry and Physiology Part C: Comparative Pharmacology*. 1991 Jan 1;98(2-3):463-5.