

# ASSESSMENT OF PROTECTIVE ROLES OF AQUEOUS SEED EXTRACT OF SOUR-SOP (*Annona muricata*) IN CEREBELLUM FOLLOWING CADMIUM-INDUCED NEUROTOXICITY OF ADULT WISTAR RATS

## ABSTRACT

Cadmium, a deleterious heavy metal that pervades the environment, has the potential to accumulate in the body and cause health complications. In the domain of traditional medicine, medicinal plants have been employed to combat the toxicity of heavy metals and treating of many diseases in traditional medicine.

**AIM:** To access the protective impact of *Annona muricata* seed extract on cadmium-triggered neurotoxicity in the cerebellum of albino wistar rat.

**PLACE OF STUDY:** Department of Anatomy, Faculty of Basic Medical Sciences Olabisi Onabanjo University, Ogun State between June 2022 and June 2023

**METHODOLOGY:** After a period of 14 days of acclimatization, 40 healthy male wistar rats were randomly allocated to four groups, group1(2ml/kg of distilled water), group2 cadmium only(2g/kg SC), group3 (2g/kg cadmium + 100mg/kg extract of *Annona muricata*) and group4(2g/kg cadmium + 200mg/kg extract of *Annona muricata*) The rats were subjected to cadmium subcutaneously followed by the oral administration of aqueous seed extract of *Annona Muricata* for fifteen consecutive days.

**RESULT:**The impact of the extract on antioxidant enzymes activities of the cerebellum, cerebellar weight, as well as the histology of the cerebellum were scrutinized. The data revealed that the aqueous seed extract of *Annona muricata*, in a dose-dependent manner, augmented the levels of superoxide dismutase (SOD) ( $P=0.005$ ) and catalase (CAT) ( $P=0.027$ ) in contrast to the cadmium-only group. The relative weight of the cerebellum exhibited a significant increase in the treated groups compared to the cadmium-only group.

The histology of the cerebellum delineated pathological changes arising from the exposure to cadmium, while *Annona muricata* brought about regenerative changes.

**CONCLUSION:** In summary, the study posits that owing to the presence of phytochemicals in *Annona muricata* aqueous seed extract, it was efficacious in mitigating the neurotoxicity induced by cadmium in the cerebellum of male rats.

Keywords: Neurotoxicity, Cerebellum, *Annona muricata*, Cadmium,

## INTRODUCTION

Cadmium, denoted by the symbol Cd, is a lustrous, pliable, and ductile metallic element that belongs to the d-block series of the periodic table, thereby qualifying as a transition metal. The element occurs naturally in trace amounts in the earth's crust and is present in several minerals such as greenockite, otavite, and cadmium oxide. The industrial significance of cadmium is evident from its widespread applications, including its use in batteries, pigments, coatings, and plastics. However, it is imperative to note that cadmium and its compounds are highly toxic, as demonstrated by an extensive body of literature (Genchi *et al.*, 2020), and are associated with a gamut of health issues. The atomic number and weight of cadmium are 48 and 112.411, respectively. The element exhibits a melting point of 321 °C and a boiling point of 767 °C, with a density of 8.65 g/cm<sup>3</sup>. Cadmium has the potential to form several compounds, among which cadmium oxide (CdO), cadmium sulfide (CdS), and cadmium chloride (CdCl<sub>2</sub>) are noteworthy examples. Cadmium oxide, a brownish-black powder, finds its usage as a pigment and in the production of batteries. In contrast, cadmium sulfide, a yellow-orange compound, is utilized in pigments, solar cells, and as a semiconductor. Cadmium chloride, a white crystalline solid, serves as a catalyst in chemical reactions (Fang *et al.*, 2014). The toxic nature of cadmium, a highly toxic metal, can result in a range of health issues, including cancer, kidney damage, and bone damage. The toxicity of cadmium is attributed to its capacity to bind to proteins, enzymes, and other biological molecules, thereby disrupting

their normal functions (Bernhoft *et al.*, 2013). Cadmium exposure can occur through inhalation of cadmium fumes or dust, ingestion of contaminated food or water, or through skin contact with cadmium-containing materials. The primary sources of cadmium exposure include tobacco smoke, industrial emissions, and contaminated food and water (Rahimzadeh *et al.*, 2017).

The primary adverse impacts of cadmium are attributed to its capability to attach to sulfhydryl (-SH) groups in proteins and enzymes, thereby inhibiting enzyme activity.

Medicinal plants have been employed for their therapeutic properties for centuries. These botanicals have been utilized to treat a plethora of maladies, ranging from minor discomforts to grave illnesses. The scope of medicative flora is all-encompassing, spanning any plant that has been employed for medicinal purposes. These plants can be utilized in their innate form or processed into herbal remedies. Notable examples of frequently utilized medicative flora include chamomile, ginger, garlic, *Annona muricata* and ginkgo biloba (Hosseinzadeh *et al.*, 2015). The historical record has documented the customary usage of medicinal plants in diverse

*Annona muricata*, commonly known as soursop, is a tropical fruit indigenous to Central and South America. It belongs to the Annonaceae family and shares a close botanical relationship with the cherimoya and custard apple. The *Annona muricata* tree is an evergreen, small-sized plant that can grow up to a height of 10 meters. Its broad-spreading canopy is adorned with shiny, dark green leaves. Its fruit is oval-shaped and has a green exterior covered with spines. It has a sweet and sour flavor, and its interior is made up of white, creamy flesh and large, black seeds (Patel and Patel, 2016).

*Annona muricata* can commonly be found in tropical and subtropical regions worldwide, including Africa, Central and South America, and Southeast Asia. This particular species exhibits a preference for moist, well-drained soil and is capable of withstanding both drought and flooding. Following maturation, the fruit of *Annona muricata* can be harvested and consumed in either its fresh form or processed into various products, such as juices, jams, and other related items (Thang *et al.*, 2013). It boasts a rich history of traditional medicinal usage and is reputed to possess anti-inflammatory, anti-cancer, and antioxidant

properties. In traditional medicine, the fruit is utilized to manage a broad range of conditions, such as fever, colds, and digestive problems. Additionally, it is believed to be beneficial in treating skin conditions such as psoriasis and eczema (Coria-Téllez *et al.*, 2018).

The cerebellum, situated in the posterior aspect of the skull beneath the cerebral hemispheres, constitutes approximately 10% of the total brain volume. The cerebellum's convoluted surface greatly increases its surface area. Its primary functions include movement coordination, balance and posture regulation. Anatomically, the cerebellum consists of three parts: the flocculonodular lobe, the vermis, and the lateral hemispheres. The flocculonodular lobe, the most ancient part of the cerebellum, governs eye movements and balance. The midline vermis coordinates movements of the trunk and limbs. The lateral hemispheres, the cerebellum's largest component, coordinate limb movements. The cerebellum, a vital component of the brain, is interconnected to the brainstem via three pairs of cerebellar peduncles: the superior, middle, and inferior cerebellar peduncles. Specifically, the superior cerebellar peduncles establish connections between the cerebellum and the midbrain, whereas the middle cerebellar peduncles facilitate connections between the cerebellum and the pons. Lastly, the inferior cerebellar peduncles mediate connectivity between the cerebellum and the medulla oblongata (Marzban *et al.*, 2015; Guell and Schmähmann, 2020). The cerebellum plays a crucial role in movement coordination and timing. It receives inputs from a wide range of sensory systems, including the visual, vestibular, and somatosensory systems, as well as the cerebral cortex. Subsequently, the cerebellum processes these inputs and transmits output signals to the motor cortex and brainstem, leading to the adjustment of movements and the maintenance of balance and posture (Roostaei *et al.*, 2014; D'Angelo, 2018). Damage or dysfunction of the cerebellum may lead to an array of motor and balance issues. Ataxia, a term utilized to denote the absence of coordination of movements that may emanate from cerebellar damage, may be evident among patients.

The exposure of humans to cadmium, a toxic heavy metal, has become an increasing environmental concern. Cadmium has the potential to induce ataxia, tremors, and impairments in balance and coordination, as well as impairments in cognitive function, attention, and memory (Wang and Du, 2013).

Its entry into the food chain through soil contamination, industrial emissions, and cigarette smoke can cause its accumulation in various tissues of the body, including the brain. The cerebellum, a crucial component of the brain responsible for movement and balance, is particularly vulnerable to the toxic effects of cadmium (Genchi *et al.*, 2020). *Annona muricata*, also known as soursop, is a tropical fruit with medicinal properties that have been shown to have neuroprotective effects. It is believed that the phytochemicals in soursop have antioxidant properties that can protect against oxidative stress, which is known to contribute to the toxic effects of cadmium in the brain (Moghadamtousi *et al.*, 2015).

## **Materials and Methods**

### **Methods**

#### **Ethical concerns in animal study**

All animal experiments and protocols adhered to the guidelines and regulations set forth by the National Research Council in regards to laboratory animal care and utilization (2011). Following the conclusion of experiments, animal carcasses were buried, no less than two feet beneath the natural surface, and covered with lime, disinfectant, and soil.

#### **Animal management**

Forty (40) healthy adult male wistar rats weighing from  $200 \pm 50$ g were procured from Pharmacy department of Olabisi Onabanjo University, Sagamu, Ogun state. The rats were subjected to a standard acclimatization period of two weeks under controlled conditions of 12-hour light/12-hour darkness, with a temperature range of  $25 \pm 3^\circ\text{C}$  and a mean relative humidity of  $50 \pm 5\%$ . Before the commencement of the treatment.

#### **Animal grouping and care**

After acclimatization, the rats were divided into 4 groups (10 rats per group):

Group i control (2ml/kg of distilled water)

Group ii cadmium only (2g/kg SC)

Group iii (2g/kg cadmium + 100mg/kg *Annona muricata* extract) and

Group iv (2g/kg cadmium + 200mg/kg of *Annona muricata* extract)

The animals were provided with standard grower feeds that were purchased from Joyful Feeds Sagamu, Ogun State. Additionally, water was provided for drinking throughout both the acclimatization period and experimental procedures. The animals were housed in appropriately ventilated cages that were equipped with feeding troughs and water plastics. It is important to note that this study adhered to established guidelines for the care and use of laboratory animals in biomedical research and teachings that were approved by the Institute of Laboratory Animal Resources, National Research Council (2010).

**Table 1. Animal grouping and treatment**

DURATION	GROUP A	GROUP B	GROUP C	GROUP D
WEEKS	Normal control (n=10)	Cadmium only (n=10)	Treatment 1 (n=10)	Treatment 2 (n=10)
0-4	Feed & Water	2mg/kg of cadmium (SC) once weekly	2mg/kg of cadmium (SC) once weekly	2mg/kg of cadmium (SC) once weekly
4-6	Feed & Water	Feed & Water	100mg/kg extract of <i>annona-muricata</i> daily (P.O)	200mg/kg extract of <i>annona-</i> <i>muricata</i> daily (P.O)

**S.C: subcutaneous, P.O: oral route of administration**

#### **Preparation of the aqueous seed extract of *Annona muricata***

The *Annona Muricata* fruit was procured from Ikenne market, located in the Ikenne local government area of Ogun state, Nigeria and then authenticated at the Botany department of Olabisi Onabanjo University. The fruit underwent a peeling process to expose the seed, after which the *Annona muricata*

seed was washed with clean water and subsequently air-dried at room temperature. The seed was then milled into a fine powder, whereupon 500g of the powder was macerated in one litre of distilled water for a duration of 24 hours. Following this, the mixture underwent filtration, and the filtrate was then concentrated using a rotary evaporator at a temperature of 60 °C. The resultant concentrated filtrate was collected in a bottle and stored at room temperature until required for usage. The concentrate was reconstituted in distilled water to obtain the desired concentrations of 100 mg/kg and 200 mg/kg of *Annona muricata*, which were utilized in the current study.

#### **Preparation of cadmium**

One milligram of Cadmium chloride was suspended in 5 ml of 0.9% NaCl.

#### **Administration of treatment**

The administration of cadmium was done according to the method described by Gaurav et al., (2010). Cadmium and *Annona muricata* aqueous seed extract was administered concomitantly for 15 consecutive days.

#### **Qualitative analysis of Phytochemical Constituent of the Aqueous Seed Extract of *Annona muricata***

The qualitative phytochemical constituents of the plant extracts were carried out to determine the presence of bioactive compounds such as saponins, alkaloids, flavonoids, steroids, tannins, phlobatannins, terpenoid, cardiacglycosides, phenols and reducing sugar in the plants following the standard methods described by (chukwuma *et.al.*, 2012)

#### **Animal sacrifice and determination of organ weight**

The animals were subjected to cervical dislocation six hours subsequent to the expiration of research. The cerebellum was meticulously extracted and the weight of the organ was ascertained per 100 grams of body weight utilizing a kerroBL20001 weighing scale.

#### **Studies on oxidative stress**

The study determined the effect of various doses of *Annona Muricata* on oxidative stress in the cerebellum of cadmium-induced neurotoxicity.

#### **Determination of superoxide dismutase (SOD) activity**

The rats' SOD activity was evaluated using the method developed by Misra and Fridovich in 1972. The principle behind this method lies in the capacity of superoxide dismutase to hinder the auto-oxidation of epinephrine at pH 10.2, which serves as the foundation for a straightforward assay of this enzyme. The introduction of increasing concentrations of epinephrine resulted in the oxidation of epinephrine to adrenochrome produced per superoxide anion introduced, which was generated by xanthine oxidase reaction. These findings propose that the auto-oxidation of epinephrine progresses through at least two distinct pathways, with only one of them being a free radical chain reaction that involves superoxide radical and, consequently, can be inhibited by superoxide dismutase.

#### **Determination of catalase activity**

The determination of catalase activity in tissue and serum was carried out using the method developed by Sinha (1972). The underlying principle of this method is based on the reduction of dichromate in acetic acid to chromic acetate upon heating in the presence of  $H_2O_2$ , resulting in the formation of an unstable intermediate known as perchromic acid. The chromic acetate produced is then quantified colorimetrically at a wavelength of 570 - 610 nm. As dichromate exhibits no absorbance in this region, its presence in the assay mixture does not interfere with the colorimetric determination of chromic acetate in any way. The catalase preparation is allowed to cleave  $H_2O_2$  for varying durations of time. The reaction is halted at a specific time by introducing a dichromate acetic acid mixture, and the residual  $H_2O_2$  is determined by measuring chromic acetate colorimetrically following reaction heating.

#### **Morphological studies for Haematoxylin and eosin staining method**

The rats were weighed in grams using a weighing scale, before the start of the experiment and before their sacrifice.



After careful removal of the tissue, they were trimmed of fats, weighed and immediately fixed in 10% formal saline. After fixing, the tissues were put into ascending grades of alcohol and then cleared in xylene. They were embedded in paraffin and serial sections of 3-5 $\mu$ m were obtained. Sections were stained with hematoxylin and eosin for histomorphological analysis and cresyl violet stain for neurons

### **Photomicrography**

Image acquisition and analysis: A bright light microscope (10 - 40x magnification objective) used. Digital camera - OMAX Toup view 3.7 attached to P.C - HP used. Java Application Software (image J Software) used.

### **Statistical analysis**

The descriptive statistic of mean, standard deviation and inferential statistics were used for this study, the data was subjected to statistical test and analysis with the aid of Statistical Packages for Social Sciences (SPSS) version 21 and Microsoft excel 2021 for windows using T-test method of data analysis. 0.05 was alpha level of significance ( $P < 0.05$ ).

## RESULTS

### Qualitative Phytochemical Constituent of the Aqueous Seed Extract of *Annona muricata*

Table 2 presents the qualitative phytochemical constituents of the aqueous seed extract of *Annona muricata*. The tabular representation effectively itemizes the various phytochemicals and their presence or absence in the sample. The symbols employed in the table denotes the presence (+) or absence (-) of particular phytochemicals. From the data, it can be seen that the aqueous seed extract of *Annona muricata* comprises a variety of phytochemicals, namely alkaloids, saponins, tannins, phlobatannins, steroids, cardiac glycosides, phenols, flavonoids, and terpenoids. These bioactive compounds are extensively utilized in traditional medicine and are commonly found in several medicinal plants.

**Table 2. Qualitative Phytochemical Constituent of the Aqueous Seed Extract of *Annona muricata***

Phytochemical	Sample
Alkaloid	+
Saponins	+
Tannins	+
Phlobatannin	-
Steroids	+
Cardiac Glycosides	+
Phenols	+
Flavonoids	+

<b>Reducing Sugar</b>	-
<b>Terpernoid</b>	+

Present; +; absent -.

### **Effect of the oral administration of the aqueous seed extract of *Annona muricata* against oxidative stress induced by Cadmium in the brain of adult male wistar rats**

The table shows the effect of the oral administration of the aqueous seed extract of *Annona muricata* against oxidative stress induced by cadmium in the brain of adult male wistar rats. The rats were divided into four groups (A, B, C&D) and treated with distilled water only (group A), 2 mg/kg of cadmium (S.C) (group B), 2 mg/kg of cadmium (S.C) and 100 mg/kg body weight of *Annona muricata* (P.O) (group C), 2 mg/kg of cadmium (S.C) and 200 mg/kg body weight of *Annona muricata* (P.O) (group D). The table presents the levels of superoxide dismutase (SOD) and catalase (CAT) in each group. SOD and CAT are both antioxidant enzymes that protect cells from oxidative stress. The values for SOD and CAT are expressed in  $\mu\text{mol/ml/min/mg/protein}$ . The mean and standard error of the mean (SEM) are also provided. The results show that the administration of cadmium significantly reduced the levels of SOD and CAT in the brain of rats in group B compared to group A (the control group). However, the administration of *Annona muricata* extract at different doses (groups C and D) significantly increased the levels of SOD and CAT compared to group B, indicating a protective effect against oxidative stress induced by cadmium. The letter codes (A, B, C, D) indicate statistical significance. A value with a letter code is significantly different from the corresponding value in the group with the letter code indicated. For example, in the SOD column, the value in group B has the letter code A, indicating that it is significantly different from the corresponding value in group A (the control group). The value in group C has the letter code A as well, indicating that it is significantly different from the value in group B. The value in group D has the letter codes B and C, indicating that it is significantly different from the values in groups B and C.

**Table 3. Effect of the oral administration of the aqueous seed extract of *Annona muricata* against oxidative stress induced by Cadmium in the brain of adult male wistar rats**

Groups	A	B	C	D
Treatment	Distilled water only	2 mg/kg of cadmium (S.C)	2 mg/kg of cadmium (S.C) and 100 mg/kg body weight of <i>Annona muricata</i> (P.O)	2 mg/kg of cadmium (S.C) and 200 mg/kg body weight of <i>Annona muricata</i> (P.O)
SOD ( $\mu\text{mol/ml/min/mg/pro}$ )	27.16 $\pm$ 0.13	3.77 $\pm$ 0.33 <sup>A</sup>	25.43 $\pm$ 0.81 <sup>A</sup>	29.35 $\pm$ 0.91 <sup>B, C</sup>
CAT ( $\mu\text{mol/ml/min/mg/pro}$ )	26.68 $\pm$ 0.76	1.85 $\pm$ 0.23 <sup>A</sup>	18.31 $\pm$ 0.88 <sup>A, B</sup>	17.56 $\pm$ 3.44 <sup>A, B, C</sup>

Each value is an expression of mean  $\pm$  SEM. ( $P < 0.05$ )

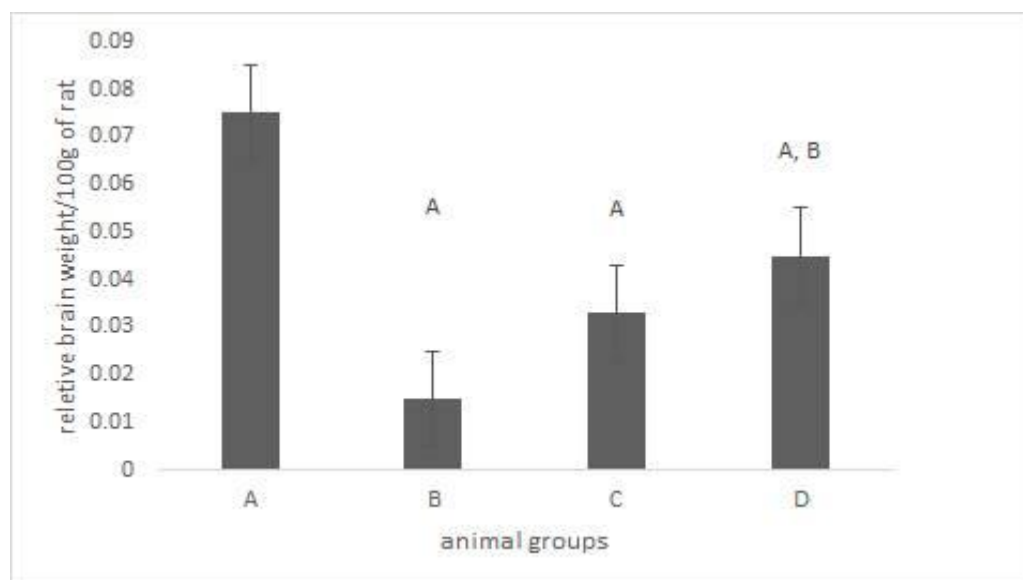
<sup>A</sup> indicates that value was significant when compared to A

<sup>B</sup> indicates that value was significant when compared to B

<sup>C</sup> indicates that value was significant when compared to C

#### **Effect of the oral administration of the aqueous seed extract of *Annona muricata* on the relative weight of the brain in Cadmium induced toxicity in the cerebellum of adult male wistar rats**

The graph shows the effect of *Annona muricata* extract on the relative weight of the BRAIN in adult male Wistar rats exposed to cadmium-induced toxicity. Group A received only distilled water, group B received cadmium, while groups C and D received cadmium and different doses of the extract. The results showed that cadmium exposure significantly decreased the relative weight of the brain in group B compared to group A. However, treatment with the extract at doses of 100 and 200 mg/kg body weight (groups C and D) significantly increased the relative weight of the BRAIN compared to group B. Overall, the study suggests that *Annona muricata* extract has potential as a protective agent against cadmium-induced BRAIN toxicity, especially at doses of 100 and 200 mg/kg body weight.



**Figure 1.**Effect of the oral administration of the aqueous seed extract of *Annona muricata* on the relative weight of the BRAIN in Cadmium induced toxicity in the cerebellum of adult male wistar rats. Each bar is an expression of mean  $\pm$  SEM. ( $P < 0.05$ ) <sup>a</sup> - Values were significant when compared to group A, <sup>b</sup>-Values were significant when compared to group B, <sup>c</sup> -Values were significant at  $P 0.04$  when compared to group c

### **Effect of the oral administration of the aqueous seed extract of *Annona muricata* on weight changes in Cadmium induced toxicity in the cerebellum of adult male wistar rats**

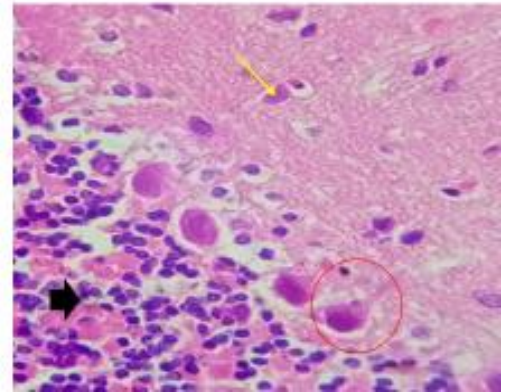
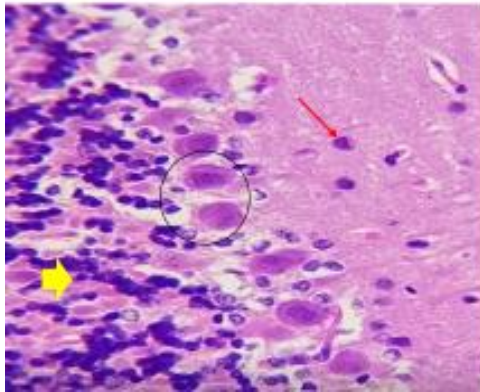
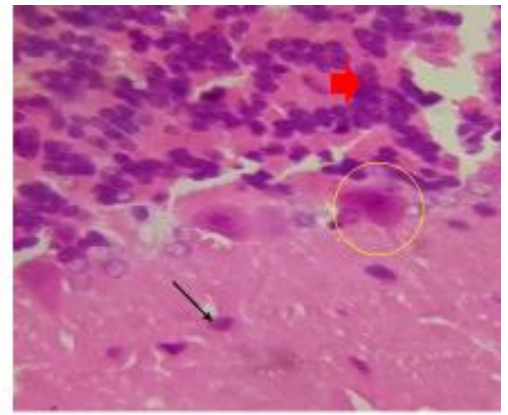
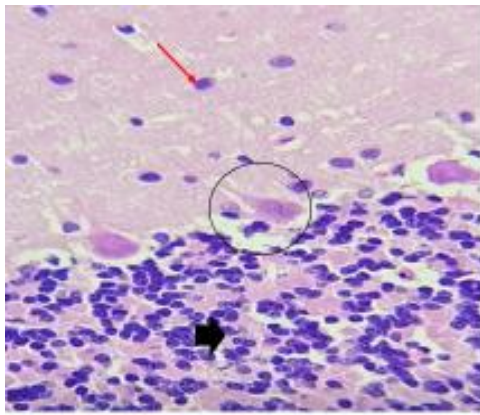
The table shows the effect of administering different doses of *Annona muricata* extract on weight changes in male rats with cadmium-induced toxicity. The groups were categorized based on the treatment they received. The initial weight and final weight of each group were measured and the values are expressed as mean  $\pm$  SEM. The significance level is indicated by letters. The results showed that the group treated with cadmium only (group B) had a significant decrease in weight compared to the control group (group A). However, treatment with the extract resulted in an increase in weight in all treated groups, with the highest dose of the extract (group D) showing the most significant increase. The results suggest that *Annona muricata* extract may have a protective effect against cadmium-induced weight loss in male rats.

**Table 4. Effect of the oral administration of the aqueous seed extract of *Annona muricata* on weight changes in Cadmium induced toxicity in the cerebellum of adult male wistar rats**

Groups A	B	C	D
Treatment Distilled water only	2 mg/kg of cadmium (S.C)	2 mg/kg of cadmium (S.C) and 100 mg/kg body weight of <i>Annona</i> <i>muricata</i> (P.O)	2 mg/kg of cadmium (S.C) and 200 mg/kg body weight of <i>Annona</i> <i>muricata</i> (P.O)
Initial weight (g) 117±3.06	214.67±34.43 A	139±21 B	135.14±14.7 A. B
Final weight (g) 135.33±12.86	178.67±18.58 A	143.33±23.09	139.33±17.9 B

Each value is an expression of mean  $\pm$  SEM. ( $P < 0.05$ )

<sup>A</sup> - Values were significant when compared to group A, <sup>B</sup> - Values were significant when compared to group B, <sup>C</sup> - Values were significant when compared to group C, <sup>D</sup> Values were significant when compared to group D,



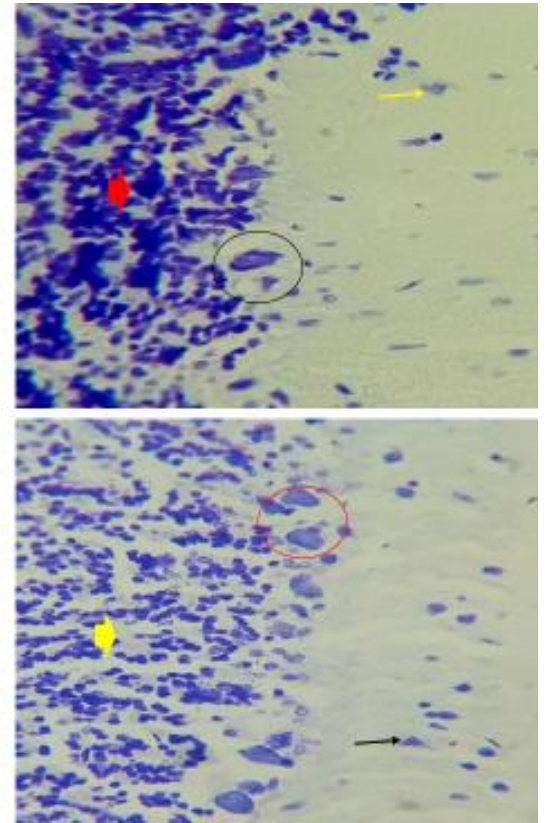
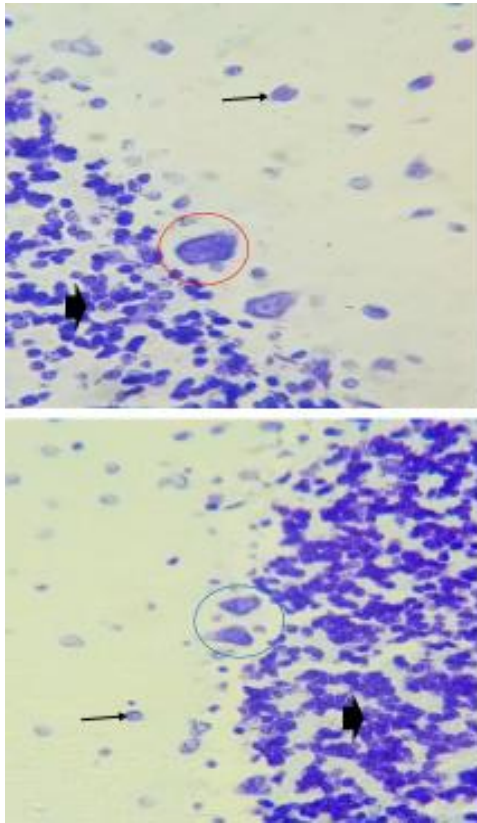
**PLATE 1: H & E photomicrograph of the Cerebellum(Magnification at x400)**

Control group showing well differentiated and normal cerebellum histomorphology. The glia cells on the granular layer with (black thick arrow), molecular layers(red thin arrow) and purkinje layer containing the pyramidal cells(black circle)

Cadmium-induced group shows severe necrotic degeneration and degradation of the purkinje layer with shrunken pyramidal cells(yellow circle), hyperchromatic glia cells and distortion of the granular layer(red thick arrow) and the molecular layer (black thin arrow).

Induced and treated with 100mg/kg aqueous seed extract of *Annona Muricata* shows regenerative pyramidal cells of the purkinje layer (black circle), granular layer (yellow thick arrow) and the molecular layer with neuroglia cells(red thin arrow).

Induced and treated with 200mg/kg of aqueous seed extract of *Annona Muricata* extract shows restorative changes of the pyramidal cells on the purkinje layer (red circle) with slight hemorrhagic changes on the granular layer (black thick arrow ) without any loss of function



**PLATE 2: The photomicrograph of the cerebellum with cresyl violet stain. (Magnification at x400)**

Control group showing well differentiated glia cells on the granular layer(black thick arrow), well differentiated pyramidal cells on the purkinje layer(red circle) and the neuroglia cell on the molecular layer(black thin arrow)

Cadmium induced group shows severe degeneration with hyperplastic glia cells on the granular layer(red thick arrow), atrophic poikilocytic pyramidal cells (black circle) and the molecular layer(yellow thin arrow)

Induced and treated with aqueous extract of 100mg/kg of Annona Muricata extract shows restorative pyramidal cells on the purkinje layer(blue circle), well distributed glia cells(black thick arrow) and neuroglia cells (black thin arrow) on the effect of the molecular layer

Induced and treated with 200mg/kg of Annona Muricata extract shows regenerated purkinje cells(red circle), granular layer (yellow thick arrow), and the molecular layer (black thin arrow)



## Discussion

Cadmium, a heavy metal, possesses toxic properties and has been implicated in causing oxidative stress in several tissues, including the cerebellum. The mechanism of cadmium-induced oxidative stress is multifaceted and involves the accumulation of reactive oxygen species (ROS) leading to oxidative damage to cellular components. The generation of ROS, such as superoxide anion ( $O_2^-$ ), hydrogen peroxide ( $H_2O_2$ ), and hydroxyl radicals ( $OH^\cdot$ ), represents a primary mechanism of cadmium-induced oxidative stress (Fang, Zhou, and Dionysiou, 2013; Ozcan and Ogun, 2015). Cadmium's ability to stimulate the production of ROS stems from its capacity to induce the expression of enzymes such as NADPH oxidase, xanthine oxidase, and nitric oxide synthase, which operate in different cellular compartments, including the cytoplasm, mitochondria, and endoplasmic reticulum (Angeli, Pereira, de Oliveira Faria, Stefanon, Padilha, and Vassallo, 2013). Cadmium has the ability to impede the function of enzymes that are involved in the antioxidant defense system, notably superoxide dismutase (SOD) and catalase (CAT). The former converts  $O_2^-$  into  $H_2O_2$ , which is then further neutralized by the latter. The inhibition of these enzymes can occur either directly or indirectly, with the latter being due to a decrease in the levels of antioxidant molecules within the cell, ultimately leading to oxidative stress (Nikolić *et al.*, 2016).

This study investigates the potential protective effects of the aqueous seed extract of *Annona muricata* (a medicinal plant) against oxidative stress, brain weight, body weight and histoarchitecture of the cerebellum following cadmium exposure in adult male wistar rats.

One of the pathways through which medicinal plants mitigate oxidative stress is via the augmentation of endogenous antioxidants. For instance, plant-based compounds, including flavonoids, carotenoids, and phenolic acids, have demonstrated the ability to upregulate the operation of antioxidant enzymes, such as superoxide dismutase (SOD) and catalase (CAT). These enzymes are responsible for the conversion of harmful ROS into less injurious molecules, thereby diminishing oxidative stress (Palipoch, 2013). In addition, medicinal plants function by directly scavenging free radicals. Polyphenolic compounds

discovered in diverse medicinal plants have demonstrated the capability to counteract free radicals through the act of donating electrons or hydrogen atoms, as evidenced by Shebis and colleagues in 2013. In addition, Gavamukulya and colleagues in 2014 have previously demonstrated that the examination of the seed extract of *Annona muricata* uncovered the existence of certain chemical substances notably, alkaloids, flavonoids, terpenoids, coumarins and lactones, anthraquinones, tannins, cardiac glycosides, phenols, phytosterols, and saponins.

Our study showed that the administration of cadmium significantly reduced superoxide dismutase (SOD) and catalase (CAT) levels in the brain, indicative of oxidative stress. However, oral administration of *Annona muricata* extract at doses of 100 and 200 mg/kg restored SOD and CAT levels, demonstrating a protective effect against cadmium-induced oxidative stress. These findings align with previous research indicating the antioxidant potential of *Annona muricata* (Gavamukulya et al., 2014; Agu et al., 2017).

Furthermore, cadmium exposure led to a significant decrease in the relative weight of the brain, emphasizing its neurotoxic effects. In contrast, treatment with *Annona muricata* extract resulted in a significant increase in brain weight in treated groups, with the highest dose showing the most significant improvement (group D). This aligns with studies suggesting the neuroprotective effects of *Annona muricata* against various insults (Keskin et al., 2022; Oladele et al., 2020).

Cadmium-induced toxicity caused a significant decrease in cerebellar weight, while *Annona muricata* extract administration mitigated this effect. This aligns with studies illustrating the neuroprotective potential of *Annona muricata* against toxin-induced damage in specific brain regions (Keskin, 2022; Wu et al., 2020).

The histological examination of the cerebellum in response to cadmium-induced neurotoxicity and the potential protective effects of *Annona muricata* seed extract provides crucial insights into the structural alterations associated with oxidative stress and the regenerative effects of the natural extract. In the control group using H and E stain, normal cerebellar histomorphology was observed, with well-differentiated layers and cells. Cadmium-induced neurotoxicity resulted in severe necrotic degeneration,

particularly in the purkinje layer, leading to shrunken pyramidal cells and hyperchromatic glial nuclei. These observations align with studies indicating the detrimental impact of cadmium on neuronal structures (Zhao et al., 2006; Marini et al., 2018).

Upon administration of *Annona muricata* extract at 100mg/kg, regenerative alterations were evident, particularly in the pyramidal cells of the purkinje layer and the granular layer. This aligns with studies demonstrating the neuroprotective and regenerative effects of *Annona muricata* on neuronal tissues (Keskin et al., 2022; Oladele et al., 2020).

At a higher dosage of 200mg/kg, the histological examination revealed restorative changes in the purkinje layer, with mild hyperplastic changes in the granular layer. Similar findings have been reported in studies investigating the dose-dependent effects of natural extracts on neuronal regeneration (Keskin, 2022; Wu et al., 2020).

Cresyl violet staining further substantiated these findings. Cadmium-induced neurotoxicity led to severe degeneration, hyperplastic granular cells, and purkilocytic pyramidal cells. Treatment with *Annona muricata* extract at both 100mg/kg and 200mg/kg demonstrated a restorative effect on the molecular layer, purkinje cells, and the granular layer. These results compliment studies highlighting the neuroprotective and regenerative potential of *Annona muricata* (Wu et al., 2020, Oladele et al., 2020)

The observed restoration of antioxidant enzymes, prevention of weight loss in the brain and cerebellum and restorative changes in the cerebellum by *Annona muricata* extract suggests its potential as a protective agent against cadmium-induced neurotoxicity. These findings support the growing body of literature emphasizing the neuroprotective and antioxidant properties of *Annona muricata*. The phytochemical constituents of *Annona muricata*, such as flavonoids and alkaloids, are known for their antioxidative and neuroprotective effects (Oladele et al., 2020; Mutakin et al., 2022).

The observed histological changes in the cerebellum provide compelling evidence for the protective and regenerative effects of *Annona muricata* seed extract against cadmium-induced neurotoxicity. The

restoration of normal cellular architecture in the treated groups suggests a potential therapeutic avenue for mitigating heavy metal-induced neuronal damage. The regenerative alterations observed in the purkinje layer and granular layer further support the notion that *Annona muricata* may have a positive impact on neuronal recovery. These histological findings complement the biochemical results, reinforcing the comprehensive protective effects of *Annona muricata* against cadmium-induced neurotoxicity.

The study's dose-dependent response emphasizes the importance of dosage in achieving optimal neuroprotective effects. Similar dose-dependent responses have been reported in studies exploring the neuroprotective effects of medicinal plants (Keskin, 2022; Wu et al., 2020).

## **Conclusion**

In conclusion, *Annona muricata* extract shows promise in mitigating cadmium-induced neurotoxicity, offering a potential avenue for therapeutic intervention.

## **Recommendation**

Further research should explore the underlying molecular mechanisms and clinical applicability of *Annona muricata* in addressing heavy metal-induced neurotoxicity. Also, there is needed to explore the extract's long-term effects, optimum dosage and potential side effects.

## **REFERENCES**

- Bernhoft, R. A. (2013). Cadmium toxicity and treatment. *The Scientific World Journal*, 2013.
- Coria-Téllez, A. V., Montalvo-González, E., Yahia, E. M., & Obledo-Vázquez, E. N. (2018). *Annona muricata*: A comprehensive review on its traditional medicinal uses, phytochemicals, pharmacological activities, mechanisms of action and toxicity. *Arabian Journal of chemistry*, 11(5), 662-691.
- Coria-Téllez, A. V., Montalvo-González, E., Yahia, E. M., & Obledo-Vázquez, E. N. (2018). *Annona muricata*: A comprehensive review on its traditional medicinal uses, phytochemicals, pharmacological activities, mechanisms of action and toxicity. *Arabian Journal of Chemistry*, 11(5), 662-691.
- D'Angelo, E. (2018). Physiology of the cerebellum. *Handbook of clinical neurology*, 154, 85-108.

- D'Angelo, E., Solinas, S., Mapelli, J., Gandolfi, D., Mapelli, L., & Prestori, F. (2013). The cerebellar Golgi cell and spatiotemporal organization of granular layer activity. *Frontiers in neural circuits*, 7, 93.
- Fang, Y., Sun, X., Yang, W., Ma, N., Xin, Z., Fu, J., ... & Hu, Q. (2014). Concentrations and health risks of lead, cadmium, arsenic, and mercury in rice and edible mushrooms in China. *Food chemistry*, 147, 147-151.
- Ganguly, K., Levänen, B., Palmberg, L., Åkesson, A., & Lindén, A. (2018). Cadmium in tobacco smokers: a neglected link to lung disease?. *European Respiratory Review*, 27(147).
- Gavamukulya, Y., Abou-Elella, F., Wamunyokoli, F., & AEI-Shemy, H. (2014). Phytochemical screening, anti-oxidant activity and in vitro anticancer potential of ethanolic and water leaves extracts of *Annona muricata* (Graviola). *Asian Pacific journal of tropical medicine*, 7, S355-S363.
- Gavamukulya, Y., Wamunyokoli, F., & ElShemy, H. A. (2017). *Annona muricata*: Is the natural therapy to most disease conditions including cancer growing in our backyard? A systematic review of its research history and future prospects. *Asian Pacific journal of tropical medicine*, 10(9), 835-848.
- Genchi, G., Sinicropi, M. S., Lauria, G., Carocci, A., & Catalano, A. (2020). The effects of cadmium toxicity. *International journal of environmental research and public health*, 17(11), 3782.
- Hosseinzadeh, S., Jafarikukhdan, A., Hosseini, A., & Armand, R. (2015). The application of medicinal plants in traditional and modern medicine: a review of *Thymus vulgaris*. *International Journal of Clinical Medicine*, 6(09), 635-642.
- Marsden, J. F. (2018). Cerebellar ataxia. *Handbook of clinical neurology*, 159, 261-281.
- Marzban, H., Del Bigio, M. R., Alizadeh, J., Ghavami, S., Zachariah, R. M., & Rastegar, M. (2015). Cellular commitment in the developing cerebellum. *Frontiers in cellular neuroscience*, 8, 450.
- Moghadamtousi, S. Z., Fadaeinasab, M., Nikzad, S., Mohan, G., Ali, H. M., & Kadir, H. A. (2015). *Annona muricata* (Annonaceae): a review of its traditional uses, isolated acetogenins and biological activities. *International journal of molecular sciences*, 16(7), 15625-15658.
- Moghadamtousi, S. Z., Karimian, H., Rouhollahi, E., Paydar, M., Fadaeinasab, M., & Kadir, H. A. (2014). *Annona muricata* leaves induce G1 cell cycle arrest and apoptosis through mitochondriamediated pathway in human HCT-116 and HT29 colon cancer cells. *Journal of ethnopharmacology*, 156, 277-289.
- Patel, M. S., & Patel, J. K. (2016). A review on a miracle fruits of *Annona muricata*. *Journal of Pharmacognosy and phytochemistry*, 5(1), 137.
- Rahimzadeh, M. R., Rahimzadeh, M. R., Kazemi, S., & Moghadamnia, A. A. (2017). Cadmium toxicity and treatment: An update. *Caspian journal of internal medicine*, 8(3), 135.
- Roostaei, T., Nazeri, A., Sahraian, M. A., & Minagar, A. (2014). The human cerebellum: a review of physiologic neuroanatomy. *Neurologic clinics*, 32(4), 859-869.
- Singh, R. (2015). Medicinal plants: A review. *Journal of plant sciences*, 3(1-1), 50-55.
- Singh, S., Kaushal, S., Kaur, J., Kaur, G., Mittal, S. K., & Singh, P. P. (2021). CaFu MOF as an efficient adsorbent for simultaneous removal of imidacloprid pesticide and cadmium ions from wastewater. *Chemosphere*, 272, 129648.

Thang, T. D., Dai, D. N., Hoi, T. M., & Ogunwande, I. A. (2013). Study on the volatile oil contents of *Annona glabra* L., *Annona squamosa* L., *Annona muricata* L. and *Annona reticulata* L., from Vietnam. *Natural product research*, 27(13), 1232-1236.

Wang, B., & Du, Y. (2013). Cadmium and its neurotoxic effects. *Oxidative medicine and cellular longevity*, 2013.

Wang, M. Y., Li, M. Y., Ning, H., Xue, R. Y., Liang, J. H., Wang, N., ... & Li, H. B. (2022). Cadmium oral bioavailability is affected by calcium and phytate contents in food: Evidence from leafy vegetables in mice. *Journal of Hazardous Materials*, 424, 127373.

Yuan, X., Wang, J., Shang, Y. E., & Sun, B. (2014). Health risk assessment of cadmium via dietary intake by adults in China. *Journal of the Science of Food and Agriculture*, 94(2), 373-380.

Zhai, Q., Liu, Y., Wang, C., Zhao, J., Zhang, H., Tian, F., ... & Chen, W. (2019). Increased cadmium excretion due to oral administration of *Lactobacillus plantarum* strains by regulating enterohepatic circulation in mice. *Journal of agricultural and food chemistry*, 67(14), 3956-3965.

Zhang, H., Yan, J., Xie, Y., Chang, X., Li, J., Ren, C., ... & Li, X. (2022). Dual role of cadmium in rat liver: Inducing liver injury and inhibiting the progression of early liver cancer. *Toxicology Letters*, 355, 62-81.

Zhang, X. Y., Wang, J. J., & Zhu, J. N. (2016). Cerebellar fastigial nucleus: from anatomic construction to physiological functions. *Cerebellum & ataxias*, 3, 1-10.

Zhang, Z., Zheng, Z., Cai, J., Liu, Q., Yang, J., Gong, Y., ... & Xu, S. (2017). Effect of cadmium on oxidative stress and immune function of common carp (*Cyprinus carpio* L.) by transcriptome analysis. *Aquatic Toxicology*, 192, 171-177.