

Giant Neck Lymphangioma in Adult with Ethanol Ablation Treatment: A Rare Case Report

ABSTRACT

Introduction: Neck lymphangioma is a benign congenital malformation that occurs frequently in children, and is rare in adults. They are usually found in the head and neck region and are often considered a metastatic lesion rather than a primary neoplasia. Most lymphangiomas are acquired at birth which is about 60%, and by the age of 2 years about 80% to 90% are present. The most common location of the abnormality is the submandibular region followed by the parotid gland.

Case Presentation: A 22-year-old man with complaints of lumps on the right side of the neck that has been getting bigger since 5 months ago. The lump initially appeared the size of a tennis ball, then quickly grew to the size of a watermelon within a month. Physical examination revealed a mass in the right colli region, cystic, fixed, multiple masses of varying size. The core biopsy examination showed the results of lymphangioma. The patient was treated with Ethanol Ablation.

Discussion: Neck lymphangiomas that are clinically more circumscribed than cavernous lymphangioma. On physical examination, they are soft, with varying sizes and shapes, and will typically grow if not surgically excised. MRI can be useful in determining the extent of anatomical involvement of cystic or cavernous lymphangiomas. Treatment of neck lymphoma is mainly surgical resection. Resection surgery can be associated with complications like lymphatic leaks, fistula formation, chronic wounds, neck on account of mucosal oedema, enlargement of internal lymphangiomas, and loss of neural innervation to the pharynx or tongue. Radiofrequency ablation is a safe, viable alternative and effective debulking treatment of neck lymphangioma.

Conclusion: We recommend ethanol ablation is a safe, viable alternative and effective debulking treatment of neck lymphangioma and thermal damage to surrounding tissues. This paper constitutes the first report of successful treatment of airway obstruction due to neck lymphangioma.

Keywords: neck lymphangioma, ethanol ablation, congenital

INTRODUCTION

“Lymphangioma of the neck is a benign congenital malformation that occurs frequently in children, and is rare in adults. They are usually found in the head and neck region and are often considered a metastatic lesion rather than a primary neoplasia. Most lymphangiomas are acquired at birth which is about 60%, and by the age of 2 years about 80% to 90% are present. The most common location of the abnormality is the submandibular region followed by the parotid gland”.¹

“Currently, the resection procedure is still the standard treatment of lymphangioma. Surgical resection may be associated with complications such as lymphatic leakage, fistula formation, chronic wounds, neck due to mucosal oedema, enlarged internal lymphangiomas, and impaired nerve supply to the pharynx or tongue”.³ Ethanol ablation is a safe and feasible alternative therapy and an effective debulking procedure for neck lymphangiomas.² We report in detail the ethanol ablation management of neck lymphangiomas.

CASE PRESENTATION

A 22-year-old man with complaints of lumps on the right side of the neck that has been getting bigger since 5 months ago. The lump initially appeared the size of a tennis ball, then quickly grew to the size of a watermelon within a month. Physical examination revealed a mass in the right colli region, cystic, fixed, multiple masses of varying size. The patient's vital signs showed blood pressure 133/73 mmHg, heart rate 74 beats/minute, respiration rate 20 breaths/minute, temperature 36.0°C. The patient's body mass index was in the underweight category (27 kg/m^2 , weight: 78 kg; TB: 170 cm). On examination of the thorax, abdomen, and extremities, there were no abnormalities.

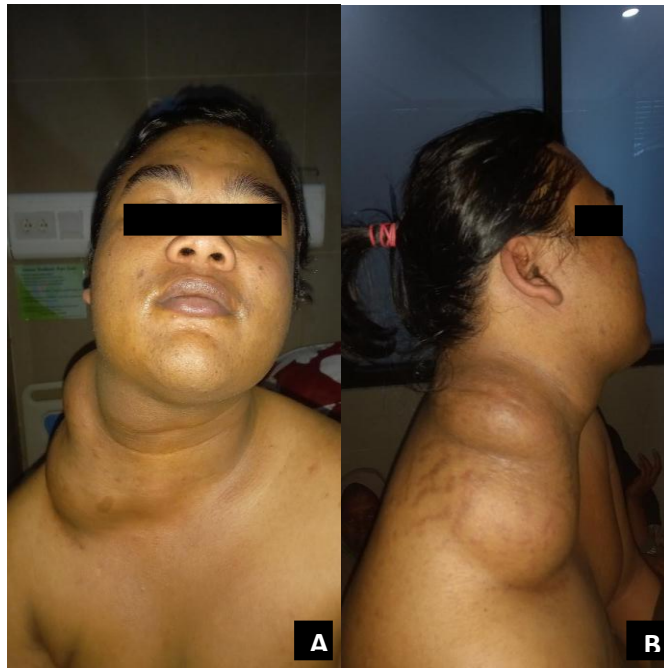

Fig. 1. Preoperative clinical picture (A and B)

The patient has a history of core biopsy and anatomical pathological examination with the results of lymphangioma was carried out in July 2023. The MRI in July 2023 showed a solid mass with cystic areas in the right colli region which extends to the right submandibular region, right supraclavicular, right thoracic inlet, attached to the right carotid artery, m. right sternocleidomastoid, and urgent trachea to the left suggests lymphangioma. The size of the mass was 20 x 15 x 10 cm appearances were consistent with a lymphangioma.

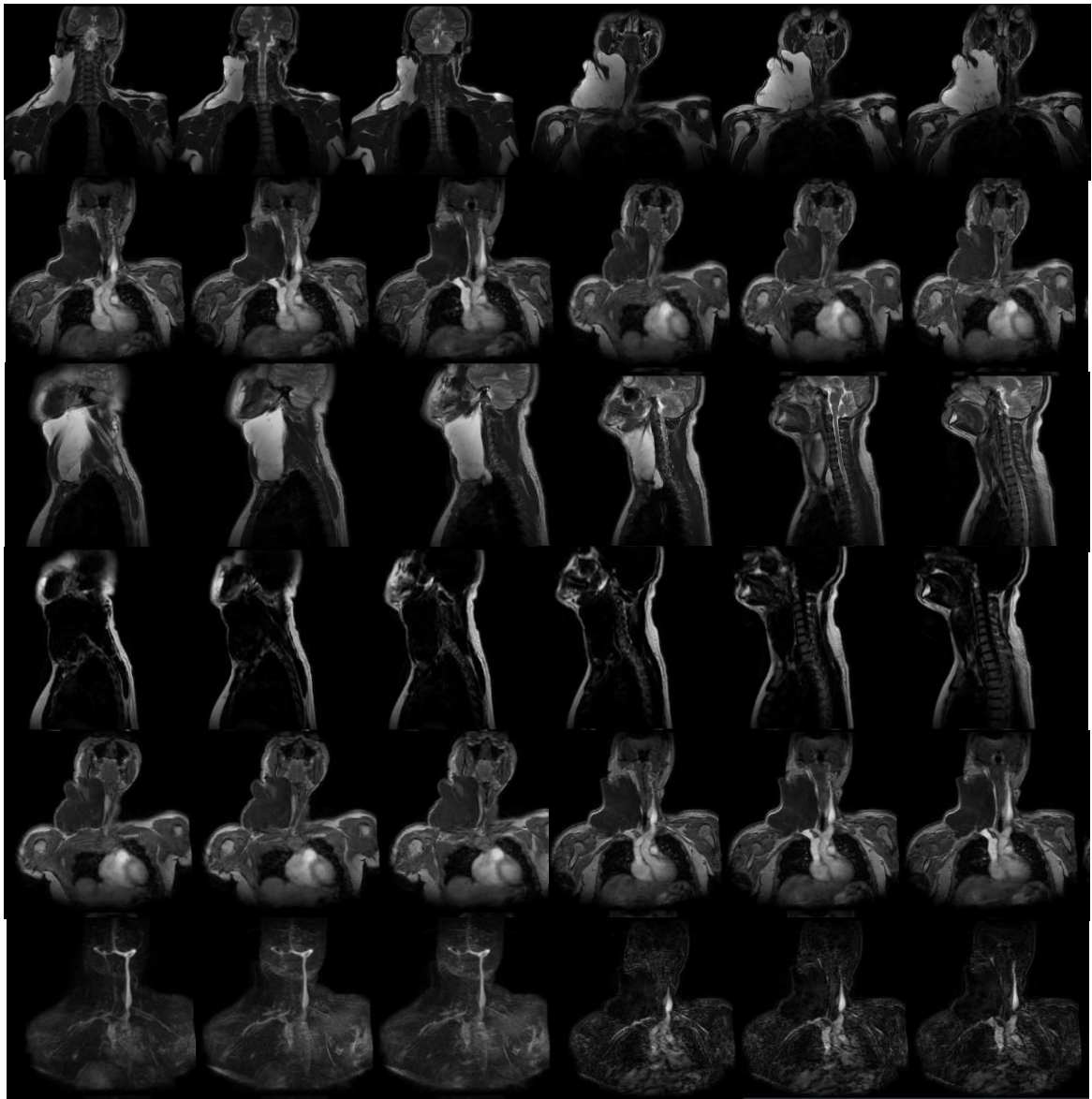


Fig. 2. Cervical MRI with contrast

Hematologic assessment in August 2023 showed that hemoglobin concentration was 17.4 g/L; mean cell volume was 49 fL, low white blood cell counts (9.3 g/L); platelet coun (360 g/L). Biochemical assessment based on Urea 18 mmol/L, Creatinin 1.1 μ mol/L). The management was treated with Ethanol Ablation.

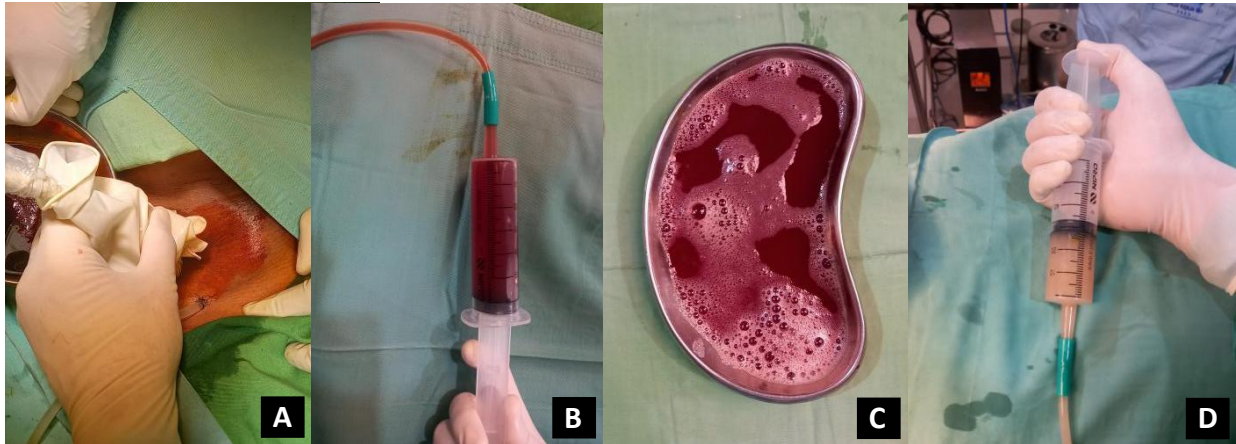

Fig. 3.Intraoperative : drainage tube insertion with US guiding (A), 720 cc liquid drained out from lymphangioma (B and C), 360 cc ethanol solution injection for ablation (D)

After the ethanol ablation procedure, the patient received oral painkiller ketorolac 30 mg / 8 hours. The patient was recovered well for a day in treatment ward. After the patient in good condition, the patient was outward and advised to control the oncology surgery polyclinic for evaluation.

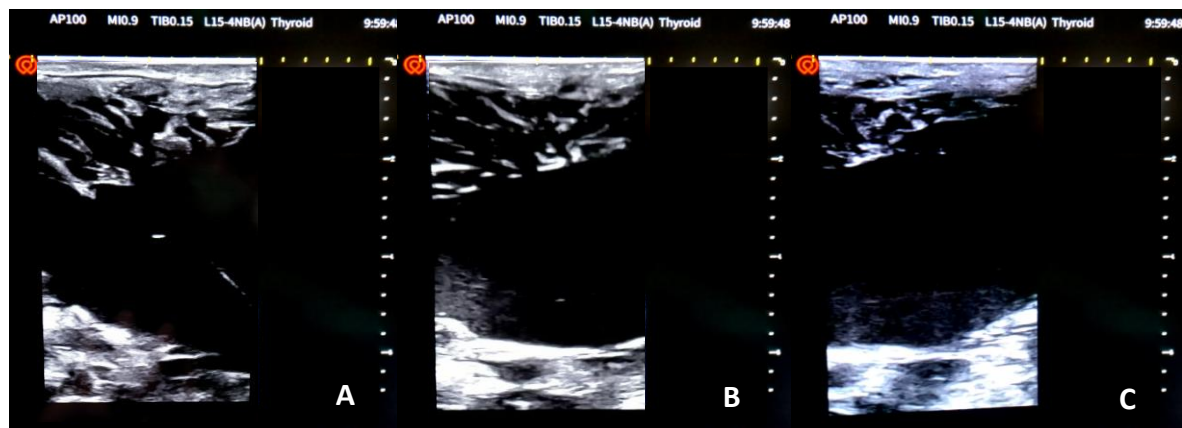


Fig. 4. Intraoperative US imaging : drainage tube insertion (A), 720 cc liquid drained out from lymphangioma (B), 360 cc ethanol solution injection for ablation ©

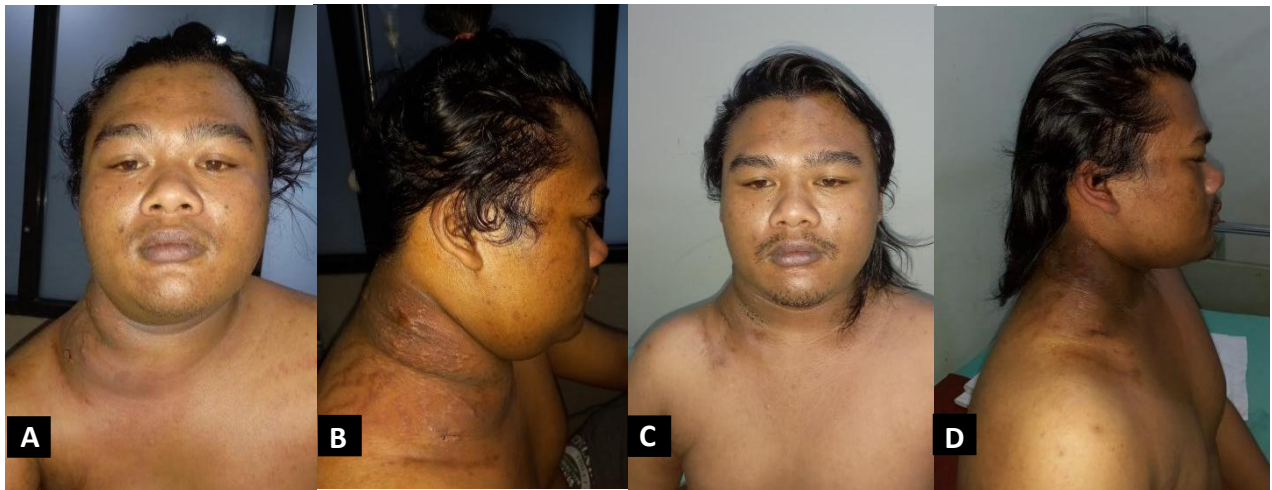

Fig. 5. 1-month follow up (A and B). 3-month follow up (C and D) after ablation

DISCUSSION

“Lymphangiomas of the neck are clinically more circumscribed than cavernous lymphangiomas”.³“Most common location is the posterior triangle of the neck in 75% of cases, then in the submandibular triangle in 20%, and 5% may present in the abdomen, retroperitoneum, mediastinum and even in multiple locations”.¹

“On physical examination, they are soft, with varying sizes and shapes, and will typically grow if not surgically excised”.³“The clinical presentation depends on their location. Lymphangiomas of the neck are generally rentent, with no other signs or symptoms”.¹“They can occasionally cause symptoms due to compression of organs, which can manifest as dysphagia when the oesophagus is compressed and dyspnoea when the trachea is compressed”.¹

“MRI can be useful in determining the extent of anatomical involvement of cystic or cavernous lymphangiomas”.³“Treatment of neck lymphoma is mainly surgical resection”.³“Resection surgery can be associated with complications like lymphatic leaks, fistula formation, chronic wounds, neck on account of mucosal oedema, enlargement of internal lymphangiomas, and loss of neural innervation to the pharynx or tongue. Ethanol ablation is a safe, viable alternative and effective debulking treatment of neck lymphangioma”.²

CONCLUSION

We recommend ethanol ablation is a safe, viable alternative and effective debulking treatment of neck lymphangioma and thermal damage to surrounding tissues. This paper is the first report on the successful treatment of neck lymphangioma with ethanol ablation.

Ethical Approval:

As per international standards or university standards written ethical approval has been collected and preserved by the author(s).

Consent

As per international standards or university standards, patient(s) written consent has been collected and preserved by the author(s).

REFERENCES

1. Basurto Kubo E., et al. Cervical lymphangioma in the adult. A report of 2 cases. *Cirugía y Cirujanos*. 2016; 84(4):313-317
2. Goswamy J. Radiofrequency ablation in the treatment of paediatric microcystic lymphatic malformations. *J Laryngol Otol*. 2013 Mar;127(3):279-84
3. Miceli A., Stewart KM. Lymphangioma. StatPearls Publishing; 2023 Jan.
4. Kristanto Yuli Yarso, Suyatmi, Bellynda M, Kamila Muyasarah, Muhammad F. Ethanol ablation for management of large cyst hygroma colli in adult: A case report. *International Journal of Surgery Case Reports*. 2023;105:108092-108092. doi:<https://doi.org/10.1016/j.ijscr.2023.108092>
5. Prabhu Hubli, Rohith Muddasetty, Sachin BM. A Giant Retroperitoneal Lymphangioma: A Case Report. *Journal of Clinical and Diagnostic Research*. Published online January 1, 2016. doi:<https://doi.org/10.7860/jcdr/2016/19989.8142>
6. Pradeep Balineni, Pavan V, E Debaraju Reddy, Reddy JS. Extensive parapharyngeal lymphangioma in a adult—Case report and review of literature. *International Journal of Surgery Case Reports*. 2020;75:85-88. doi:<https://doi.org/10.1016/j.ijscr.2020.08.051>
7. Rahimi M, Hares R, Mohammad Amin Shinwari, Nawaz Sharif Kashaf, Soghra Khaliqi. Sclerotherapy with 98% ethanol for a neck lymphangioma: A case report. *Journal of Pediatric Surgery Case Reports*. 2024;101:102758-102758. doi:<https://doi.org/10.1016/j.epsc.2023.102758>

8. Lee E, Park I, Amir Elzomor, et al. Efficacy of ethanol ablation as a treatment of benign head and neck cystic lesions. *American Journal of Otolaryngology*. 2021;42(6):103082-103082. doi:<https://doi.org/10.1016/j.amjoto.2021.103082>
9. Timothy Brandon Shaver, Muhammad El Shatanofy, Niermeyer W, Joshi AS. The Use of Ethanol Sclerotherapy To Treat a Large Cervical Lymphocele. *Cureus*. Published online December 28, 2022. doi:<https://doi.org/10.7759/cureus.33043>
10. Lee JH, Yoon SW, Park HS, et al. Efficacy of Percutaneous Ethanol Injection for Benign Neck Cyst. *Korean Journal of Otorhinolaryngology-Head and Neck Surgery*. 2016;59(6):448-452. doi:<https://doi.org/2016.59.6.448>
11. Stein M, Hsu R, Schneider PD, Ruebner BH, Mina Y. Alcohol Ablation of a Mesenteric Lymphangioma. *Journal of Vascular and Interventional Radiology*. 2000;11(2):247-250. doi:[https://doi.org/10.1016/s1051-0443\(07\)61473-0](https://doi.org/10.1016/s1051-0443(07)61473-0)
12. Liu X, Cheng C, Chen K, Wu Y, Wu Z. Recent Progress in Lymphangioma. *Frontiers in Pediatrics*. 2021;9. doi:<https://doi.org/10.3389/fped.2021.735832>
13. Kelekis A, Pavlos Maragkoudakis, Dimitrios Filippiadis. Percutaneous Radiofrequency Ablation of an Auricular Lymphangioma. *Journal of Vascular and Interventional Radiology*. 2019;30(10):1678-1679. doi:<https://doi.org/10.1016/j.jvir.2019.04.013>
14. Sang Woo Park, Cha I, Kim K, Hong SJ, Park C, Chung H. Percutaneous Sclerotherapy Using Acetic Acid After Failure of Alcohol Ablation in an Intra-abdominal Lymphangioma. *Cardiovascular and Interventional Radiology*. Published 2013. Accessed December 23, 2023. <https://www.semanticscholar.org/paper/Percutaneous-Sclerotherapy-Using-Acetic-Acid-After-Park-Cha/1337a97c4d13cf9320a9e414804c3a27ae9eb31e>
15. Manzini M, Schweiger C, Manica D, Kuhl G. Response to OK-432 sclerotherapy in the treatment of cervical lymphangioma with submucosal extension to the airway. *Brazilian Journal of Otorhinolaryngology*. 2020;86(1):127-129. doi:<https://doi.org/10.1016/j.bjorl.2016.04.016>
- 16.