

UNILATERAL STELLATE CATARACT POST ELECTROCUTION- A CASE REPORT AND LITERATURE REVIEW

ABSTRACT

Aim- To outline the evaluation and management of a case of unilateral stellate cataract post electrocution.

Presentation of case- A 54 year old male patient presented with diminished vision in left eye. On evaluation he was found to have a peculiar stellate patterned cataract. He gave history of sustaining an electric shock 3 months prior. He was managed as a routine case of cataract with good visual recovery. **Discussion-** This case demonstrates a peculiar case of cataract seen after typical history in relatively younger age group. It has been reported in literature previously, and comprises an important cause of unilateral cataract.

Conclusion- This is an interesting etiology of presenile cataract which can be managed well with careful clinical evaluation leading to a good visual outcome.

KEYWORDS

Stellate cataract, electrocution, phacoemulsification, unilateral cataract

1. INTRODUCTION

Electrical injury is an established cause of cataract. The earliest case of cataract following lightning injury was reported in literature in 1722 by St Yves [1]. It is generally a cause of visual impairment in the younger age group. It may be unilateral or bilateral and may be associated with other ocular and general injuries which can sometimes be potentially devastating. Most cases are associated with high voltage burns located closer to the eye [2]. We present a case of delayed onset unilateral cataract in a relatively young patient who gave a remote history of electrical injury sustained while doing household chores.

2. CASE PRESENTATION

2.1 History and examination: A 54 year old male patient presented to the Ophthalmology out patient department of a zonal hospital in Gujarat, with history of gradually progressive painless diminution of vision of the left eye of two months duration, which was associated with glare. The patient had no other symptoms and offered no antecedent history like trauma or drug intake. There were no known comorbidities.

On evaluation, the distant visual acuity with Snellen's chart was 6/6 in right eye and 6/36 in left eye with no improvement with refraction. The anterior and posterior segments were examined on the slit lamp with a 90D lens for retina examination. The fundus examination was also done using an indirect ophthalmoscope and a 20D lens. The anterior and posterior segments of the right eye were within normal limits. The left eye showed a peculiar stellate-shaped cataract with distinct feather-like opacities branching out from the center in the posterior cortical region [Fig 1]. Rest of the anterior segment and fundus examination of the left eye were normal. Intra-ocular pressure (IOP) was 14 mmHg and 16 mmHg in right and left eyes respectively, by non contact tonometry (NCT).

Due to the peculiar morphology and unilaterality of the cataract in a relatively young and healthy patient, we thought to seek secondary cause for cataract formation. Although the patient had initially denied any history of trauma, on specific questioning, he recalled sustaining an electric shock to his left hand while doing some electrical work at home, approximately three months prior to the onset of symptoms.

2.2 Diagnosis and management: Based on history and clinical examination findings, the patient was diagnosed as a case of unilateral immature cataract. In view of the typical stellate morphology and unilaterality, the likeliest cause was attributed to the incidence of electric shock that the patient had sustained in the past. The patient underwent routine cataract workup with optical biometry. He was listed for elective cataract surgery after three weeks as per the existing operating room appointment list. The patient was evaluated again three days prior to surgery, when the morphology of the cataract was found to have significantly changed and now resembled an early nucleus sclerosis [Fig 2]. The patient underwent uneventful phacoemulsification with posterior chamber intraocular lens (IOL) implantation of left eye under peribulbar anesthesia [Fig 3]. A monofocal hydrophobic aspheric IOL with extended depth of focus and IOL power of +18.0 D was implanted in the patient [Fig 4]. Eye patch was applied for 24 hours as the surgery was done under peribulbar anesthesia.

2.3 Follow up: Eye patch was removed on first post operative day and the patient was commenced on topical antibiotic-steroid (moxifloxacin 0.5% + prednisolone 1%) six times a day, an IOP lowering eyedrop (timolol 0.5%) twice a day and a cycloplegic eyedrop (homatropine 2%) three times a day. The patient was followed up on post operative day 1, day 7 and day 28. He had good post operative recovery [Fig 5] and distant visual acuity at the end of first week was 6/6 in left eye. Timolol and homatropine were stopped at the end of first week and steroid-antibiotic was tapered gradually over the next five weeks. At third post operative visit on day 28, the patient was prescribed near vision glasses of +2.50 DS for both eyes.

3. DISCUSSION

Electrical injuries are not an uncommon presentation in the medical world, and tend to present commonly in young males, as demonstrated by a study published by Kaergaard et al in 2022 [3]. Electrical injuries to the eye can range from periocular skin burns, eyelid injury, conjunctival and corneal injury, uveitis, cataract, retinal detachment, macular hole, retinal vascular occlusions, choroidal rupture and optic atrophy [4]. Most ocular injuries result from electric shock close to the eyes (face, scalp region). Cases have also been reported after transmission of electric current through the extremities [3]. The voltage of electric current causing ocular injury has been reported to be relatively high, generally in the range of 500-80,000 volts as quoted by Duke Elder [5].

Many cases with diminution of vision following electrical injury can be attributed to isolated unilateral or bilateral cataracts without any other ocular injuries [6,7]. The pathogenesis of cataract is hypothesized to be damage to sub capsular epithelium leading to osmotic changes and coagulation of lens protein [2]. Anterior sub capsular cataract is the most common presentation, although opacification of the posterior cortical fibers has also been documented [8]. Electron microscopy findings first reported by Hanna and Fraunfelder in 1972 have suggested cell proliferation and elongation, each covered by their own capsule, in the anterior sub capsular region, and diffusely opaque posterior cortical fibers with dense circular bodies [9].

We reported a case of unilateral cataract in a 54 year old male, who had sustained an electrical injury to his left hand 3 months prior to onset of symptoms. The injury being sustained while doing electrical work at home, was unlikely to be due to a high voltage electric current as it was sustained in the house, and the patient did not seek any immediate medical assistance. Low voltage electrical injury leading to cataract has been reported by Lock in 1957 and by Duman, Çevik and Tüfekçi in 2015 [10,11]. The latter case was also associated with uveitis and retinal detachment along with other external and systemic injuries. A study

published by Ferreiro et al in 1998 has reported that there is no association between the voltage of electrical current and severity of cataract [12].

The novelty of this case report lies in the fact of relatively trivial electrical injury sustained by the patient, which was not reported for medical attention. There have been very few cases of cataract following low voltage electrical injury reported in literature. This case is also different in respect of morphological features of the cataract, which are among the less common signs as per published literature [8,13]. There was no anterior sub capsular opacity in our patient. Distinct branching patterns were conspicuous in the posterior cortex at presentation. Our patient had a rapid progression of cataract. At the time of surgery within three weeks of presentation, the initial branching pattern had coalesced into a homogenous nucleus sclerosis. If the surgery were delayed, the cataract would likely have progressed rapidly to form a hyper mature cataract. Stephen V et al have reported in 2006 that in rare cases cataract following electric injury may even progress to phacomorphic glaucoma [14]. Hence, timely detection and surgery led to an uneventful intra operative and post operative period and a good visual outcome in this patient. Cases of isolated cataracts have been found to have good visual prognosis even with high voltage injuries, provided the other structures of the eye remain unaffected [15].

4. CONCLUSION

Cataract formation following low voltage electrical injuries may be commoner than expected. The patient may not present immediately due to presumed trivial nature of injury and absence of symptoms. The cataract may have a rapid progression and even lead to complications such as phacomorphic glaucoma. Hence, a timely intervention can lead to uncomplicated surgery with good visual outcome.

7. AUTHORS' CONTRIBUTIONS

First author- Case workup, management, data collection, manuscript preparation, review of literature.

Second author- Data collection, review of literature, proof reading of manuscript.

All authors have read and approved the manuscript.

8. CONSENT

All authors declare that written informed consent was obtained from the patient for publication of this case report and accompanying images.

REFERENCES

1. St. Yves, Nouveau traité d. mal. d. yeux, 368, 1722, cited by S. Duke-Elder, Text-Book of Ophthalmology. St. Louis, C. V. Mosby, 1954, vol. 6, p. 6435.
2. Baranwal VK, Satyabala K, Gaur S, Dutta AK. A case of electric cataract. Med J Armed Forces India. 2014 Jul;70(3):284-5. doi: 10.1016/j.mjafi.2012.06.009. Epub 2012 Sep 28. PMID: 25378786; PMCID: PMC4213923.
3. Kaergaard A, Nielsen KJ, Carstensen O, Biering K. Electrical injury and the long-term risk of cataract: A prospective matched cohort study. Acta Ophthalmol. 2023 Feb;101(1):e88-e94. doi: 10.1111/aos.15220. Epub 2022 Jul 27. PMID: 35894089; PMCID: PMC10086943.

4. Peñaranda CF, Acon D, Valdes CA, Wu L. Bilateral maculopathy and cataracts secondary to an accidental high-voltage electrical discharge. *Taiwan J Ophthalmol*. 2020 Apr 27;11(2):187-189. doi: 10.4103/tjo.tjo_7_20. PMID: 34295627; PMCID: PMC8259525.
5. Duke-Elder, Text-Book of Ophthalmology. St. Louis, C. V. Mosby, 1954, vol. 6, p. 6436.
6. Yadav A, Katiyar V, Phadikar P, Gupta SK. A case of isolated bilateral cataract following high-voltage electrical injury. *Oman J Ophthalmol*. 2020 Feb 17;13(1):34-36. doi: 10.4103/ojo.OJO_129_2016. PMID: 32174738; PMCID: PMC7050452.
7. Srivastava VK. Symmetrical Cataract Formation Both Eyes Due To Electric Injury Over The Central Scalp: (A Case Report). *Med J Armed Forces India*. 1998 Apr;54(2):163-164. doi: 10.1016/S0377-1237(17)30515-4. Epub 2017 Jun 26. PMID: 28775459; PMCID: PMC5531376.
8. Korkmaz A, Karti O, Zengin MO, Sagban LL, Kusbeci T. Simultaneous Cataract, Maculopathy and Optic Atrophy Secondary to High-Voltage Electrical Shock Injury. *Neuroophthalmology*. 2018 Nov 2;44(1):34-37. doi: 10.1080/01658107.2018.1540644. PMID: 32076447; PMCID: PMC6999628.
9. Hanna C, Fraunfelder FT. Electric cataracts: II. Ultrastructural lens changes. *Archives of ophthalmology*. 1972 Feb 1;87(2):184-91.
10. Lock JAN. Electrical Cataract Produced by a 240-Volt Current. *Brit J Ophthal*. 1957; 41(500).
11. Duman R, Çevik SG, Tüfekçi A. Unilateral uveitis, cataract and retinal detachment following low-voltage electrical injury. *Burns Trauma*. 2015 Oct 15;3:19. doi: 10.1186/s41038-015-0020-x. PMID: 27574665; PMCID: PMC4964080.
12. Ferreiro I, Meléndez J, Regalado J, Béjar FJ, Gabilondo FJ. Factors influencing the sequelae of high tension electrical injuries. *Burns*. 1998 Nov;24(7):649-53. doi: 10.1016/s0305-4179(98)00082-5. PMID: 9882065.
13. Khadka S, Bhanju R, Ranabhat S. (2020). Cataract following electric shock -Case report. *Journal of Kathmandu Medical College*. Vol 8 No 3 Issue 29. 167-170. doi: 10.3126/jkmc.v8i3.29726.
14. Stephen V, John SR, Chakraborty A, Chakrabarti M. Bilateral cataract following electrical injury. *Kerala J Ophthalmol*. 2006;18(3):252-4.
15. Rath, M., Bhatt, N.K., Dhull, C.S., Sachdeva, S., & Phogat, J. (2016). Electric cataract: a report of two cases and a review of the literature. *The Egyptian Journal of Cataract and Refractive Surgery*, 22, 54 - 55.

FIGURES

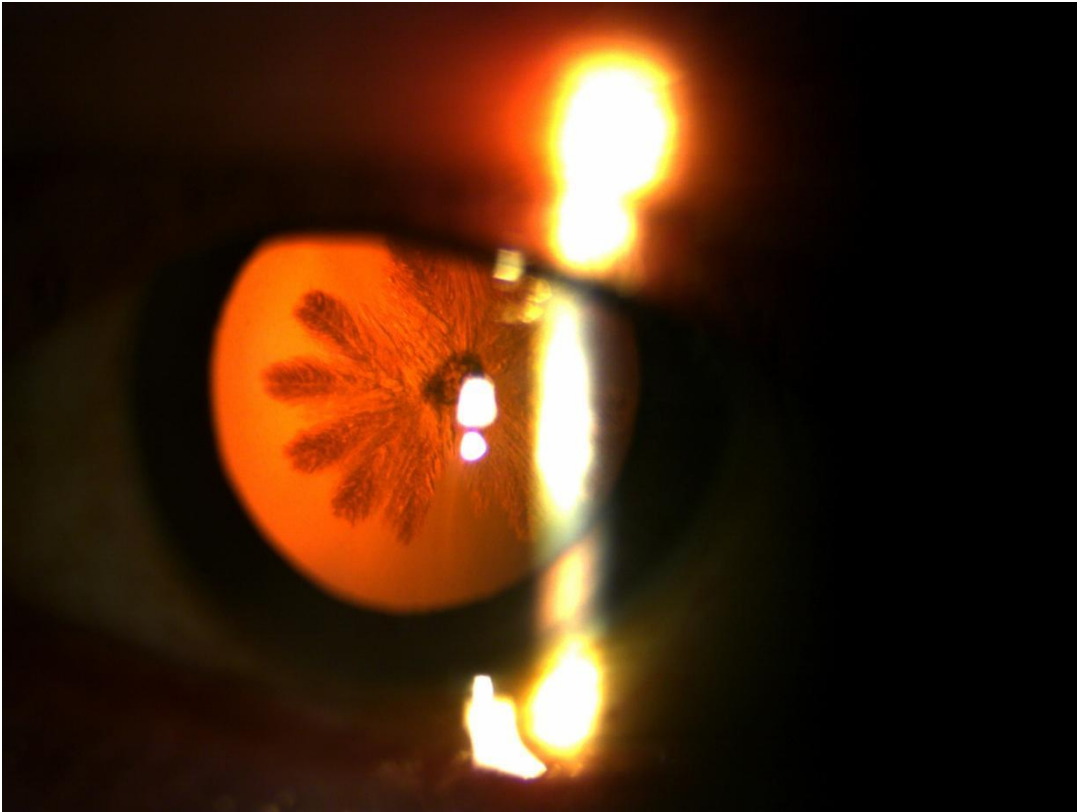


Fig 1: Slit lamp examination in retroillumination showing cataract with feathery branches radiating from centre in posterior cortex region

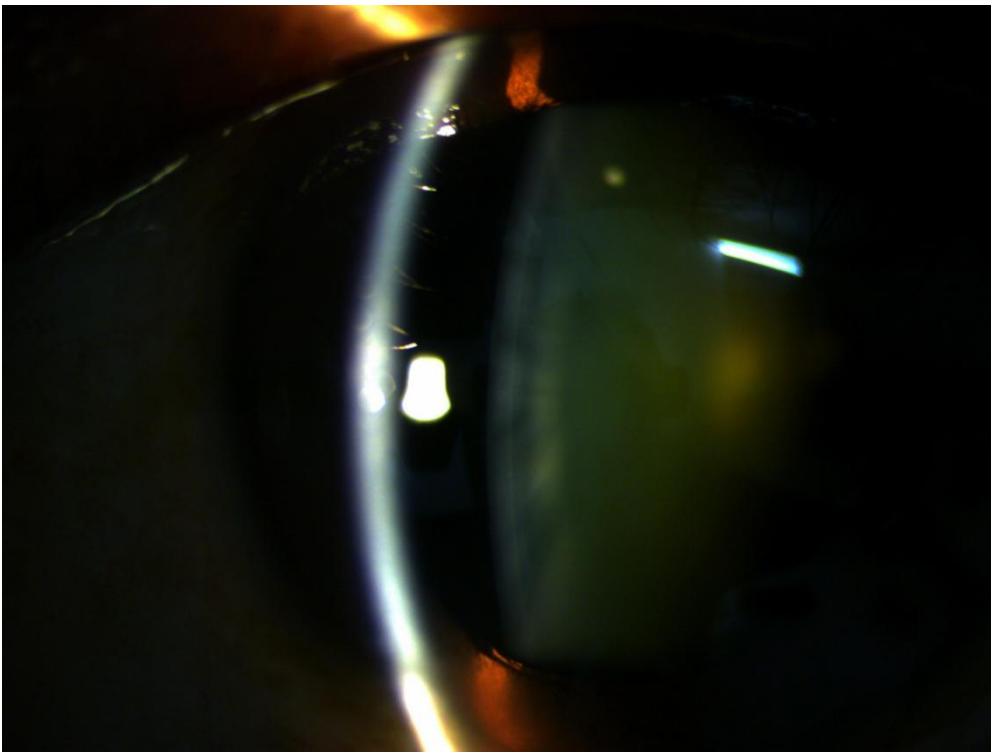


Fig 2: Slit lamp picture from three weeks later showing coalescence of radiating fibres to resemble nucleus sclerosis

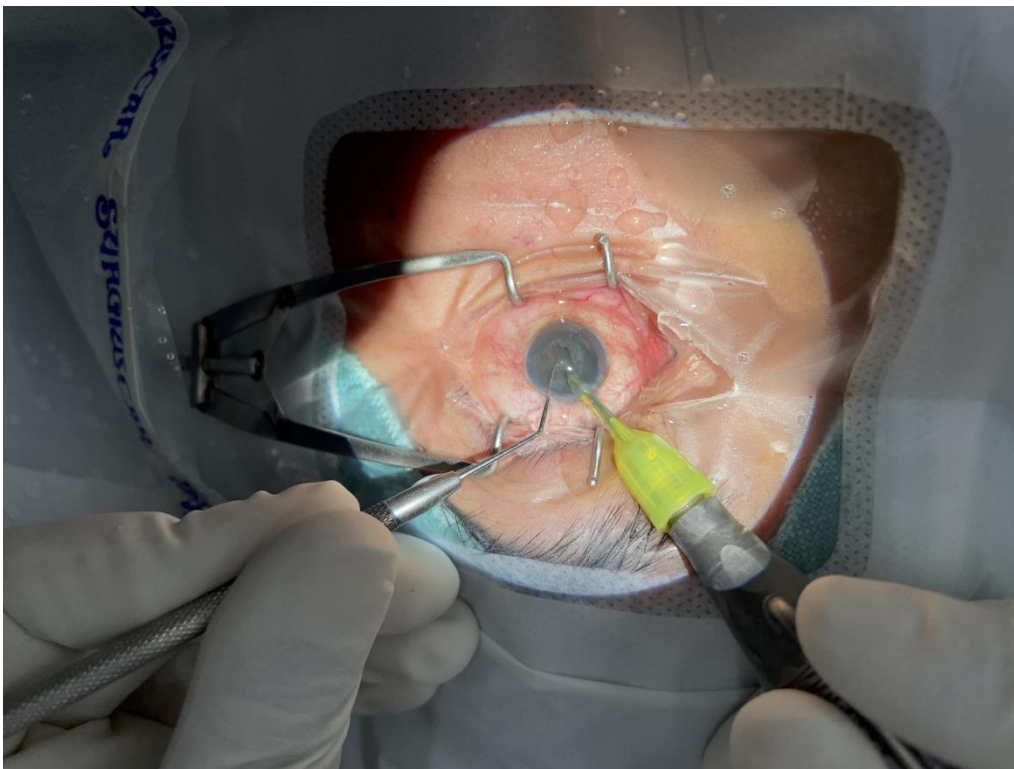


Fig 3: Phacoemulsification of the left eye from superior incision

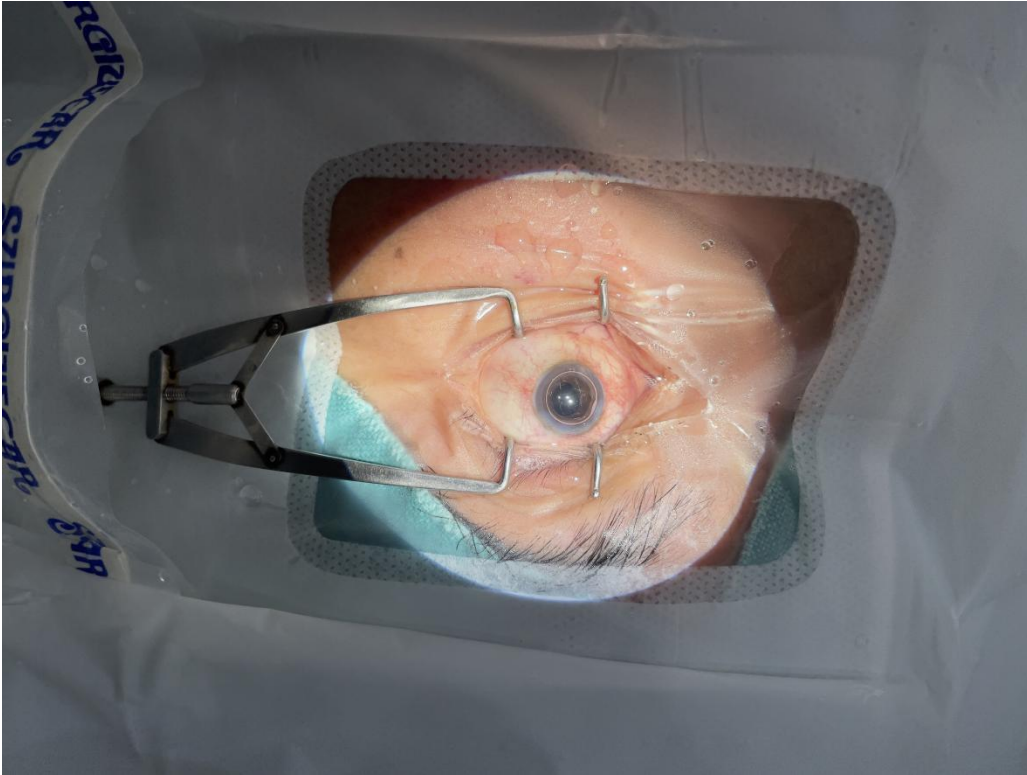


Fig 4: Photograph following completion of surgery showing a reflex from IOL and air bubble in anterior chamber

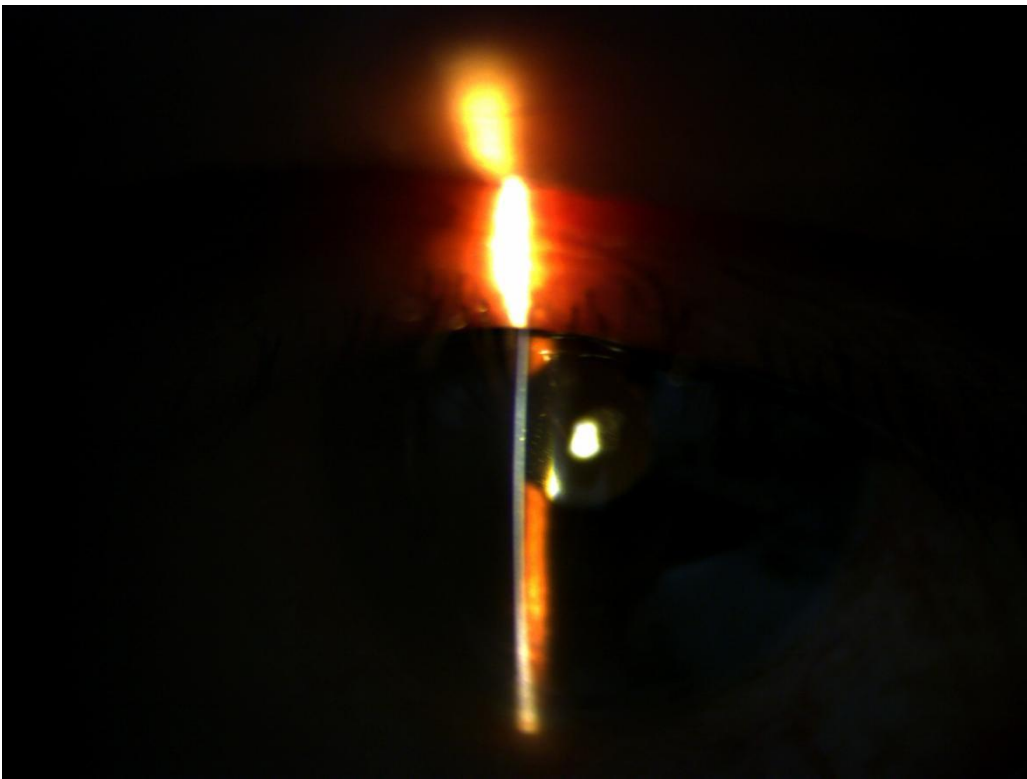

Fig 5: Slit lamp photograph one week post operatively showing a well placed PCIOL and a clear cornea

