

# ADAMS-OLIVER SYNDROME (OSA)

## Abstract

### INTRODUCTION :

Adams-Oliver's syndrome (SAO) is a rare genetic condition characterized by the association of limb anomalies and Aplasia cutis congenita in vertex, often accompanied by underlying ossification defect and vascular lesions. The objective through this new observation is to describe the clinical, radiological, therapeutic and evolutionary elements according to what was described up to there in the literature.

### OBSERVATION:

Female newborn child, stemming from a pregnancy followed with normal obstetric ultrasounds. He presents a scalp agenesis, underlying cranial bone aplasia and toes hypoplasia with syndactyly. The association of these two major criteria allowed making the diagnosis of SAO. Moreover, she presents disjointed and large sagittal suture with left parietal bone borders hypoplasia. The notion of periventricular bleeding. The rest of the balance sheet deformation, namely the abdominal ultrasound and echocardiography was without anomalies. The newborn was sent in neurosurgery for restorative treatment, which will be planned at the age of 3 months.

### DISCUSSION AND CONCLUSION:

This observation illustrates sporadic and not complicated SAO. The absence of complete gene mapping in SAO and therefore of any genetic counseling, prenatal morphological ultrasound, is making important in evolutionary terms of subsequent pregnancies.

Key words: Adams-Oliver syndrome, brachydactyly, cutis aplasia.

### Introduction

Congenital Cutaneous Aplasia (ACC) is a rare condition, characterized by a complete or partial absence of skin tissue over a more or less extensive area. It involves the scalp (vertex) in approximately 80% of cases. It can occur in the context of various pathologies, mainly malformative. Adams-Oliver syndrome (type II of the Frieden classification) is characterized by congenital cutaneous aplasia associated with malformations of the extremities of the limbs. Adams-Oliver syndrome has been considered to be autosomal dominant. Subsequent publications highlight the possibility of autosomal recessive transmission or even de novo mutation. The mortality reported in the literature, around 20%, is essentially due to infectious complications, particularly meningeal complications, and hemorrhage from the superior longitudinal sinus [1].

Our goal through this observation is to compare the clinical biological and radiological elements in our patient in the light of those described so far in the literature.

### **Case presentation**

The newborn female, 3rd of her siblings, originally from and living in Errachidia;

Admitted to our neonatal intensive care unit at H1 of life for respiratory distress and malformation syndrome; He is the product of a non-consanguineous marriage of healthy parents, mother aged 28 years, with no known pathological history, the pregnancy was well monitored (prenatal ultrasound and serologies (-)), carried to term with prolonged rupture of membranes > 19h with liquid clear, vaginal delivery, good adaptation to extra-uterine life birth weight: 2450g, Height: 47cm, head circumference: 32cm.

On admission, the newborn was pink, FR: 63 cycles/min with a Silvermann score of 4/10 and hyporeactive to different stimulations. Absence of rales on auscultation.

Loss of substance at the posterior part of the parietal bone measuring 6.3 by 7 cm, including the scalp, the middle and posterior part of the 2 parietal bones with exposure of the dura mater (photos 1). Presence of 2 dimples at the dorsal and lumbar level. Agenesis of the 4th and 5th toe with syndactyly between the 2nd and 3rd toe on both feet (photo 2)

The rest of the clinical exam is normal

Furthermore, the newborn presents a disjunction and significant widening of the sagittal suture with predominant hypoplasia of the banks of the left parietal bone on the brain CT. MRI reveals "signal abnormalities of the paraventricular white matter and the left lenticular nucleus in T1 hyper signal, T2 hypo signal and FLAIR hyper signal and diffusion at b1000. This is associated with hyposignal T2 and T2\* from the posterior part of the falx cerebri and the left hemi-tente of the falx cerebellum » include in the legend of the MRI section(s) » parahemorrhagic lesions ventricular and white matter with posterior supradural hemorrhagic suffusions (figure 2).

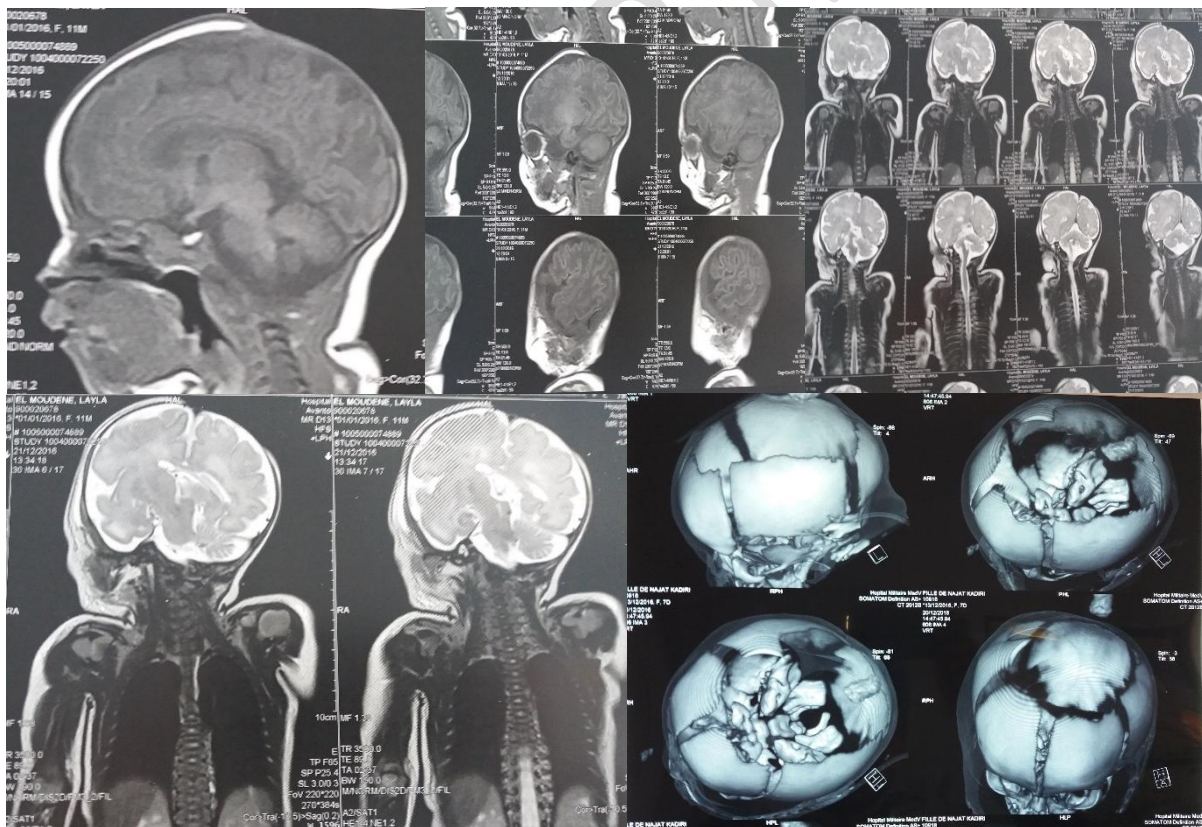
The rest of the malformation assessment, namely abdominal Doppler ultrasound and echocardiography, was without abnormalities.

The newborn was referred to neurosurgery for restorative treatment which is planned at the age of 3 months (figure 3).

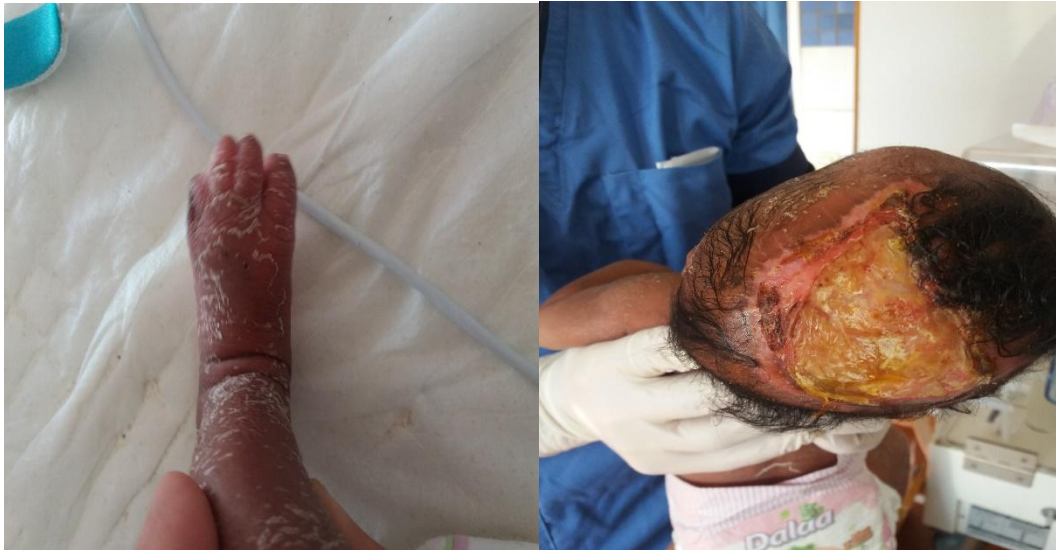

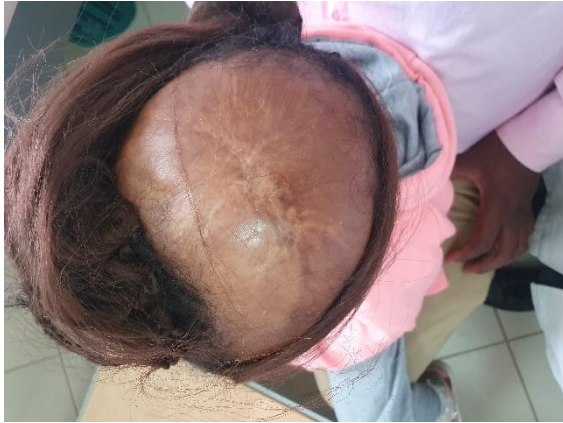Fig 1a, 1b. Morphology showing Adams-Oliver Syndrome (OSA)

Figure 2. radiological images





*Figure3: Evolution after treatment*

## Discussion

Adams-Oliver syndrome (OMIM 100300), classified as an ectodermal dysplasia, is a rare congenital disorder of unknown incidence due to its high heterogeneity [7,9,10]. It includes congenital cutaneous aplasia of the vertex, anomalies of the extremities of the limbs associated variably with a wide range of other physical anomalies [1,4].

It is part of congenital cutaneous aplasia, a very heterogeneous entity classified into 9 groups according to Frieden, of which it represents the 2nd group. It was first described in 1945, in a boy who was one of 8 affected members of the same family, suggesting autosomal dominant transmission with variable expression [2]. Subsequently, other modes of transmission were reported, autosomal recessive or sporadic which would be the most frequent mode of transmission [3].

The exact pathogenetic mechanism of SAO remains unknown, however, a vascular factor is strongly suspected due to the frequency of vascular manifestations observed, notably cutis marmorata and pulmonary and portal vascular anomalies [4]. Furthermore, the involvement of distal areas such as the vertex and the extremities could be explained by a stretching of small abnormal vessels at this level during the period of rapid embryonic growth [5].

Since its first description, it is currently recognized that ODS is a clinically heterogeneous condition in its expression (mild forms and severe forms) and in its possible association with other systemic or malformative abnormalities [4,6]. Classically, ODS is limited to damage to the head and extremities. Scalp involvement is present in more than 86% of cases [7,8]. There are two clinical forms: the membranous form, which represents approximately 2/3 of cases, is characterized by shaped, oval lesions, with a shiny atrophic membrane with a few hairs visible. This form results from incomplete closure of the ectoderm. It is most often sporadic. In this membranous form, particular forms have been reported, in particular pseudo-bullous forms which have histological characteristics close to those of encephaloceles or meningoceles, which is in line with the recent hypothesis according to which these bullous forms represent forms of failure to close the neural tube.

In the non-membranous form, the lesions are large and irregular with an underlying defect whose healing occurs at the expense of an irregular sclerotic scar. Infectious and hemorrhagic

complications are common in this form. The diagnosis is generally neonatal by the discovery of an isolated loss of skin substance or of a thin isolated membrane breaking the cutaneous regularity of the scalp. The border with normal skin is abrupt and the skin tissue is reduced to its simplest expression. In depth, the lesion varies from simple cutaneous absence to the associated absence of the galea of the cranial vault and the dura mater in severe forms. The ACCV constantly involves the midcranial region. It often sits near the posterior fontanelle.

Extremity involvement, present in 84% of cases, is often bilateral [8,9], asymmetric and affects the lower limbs more often than the upper limbs [9]. The latter can manifest as syndactyly, brachydactyly, oligodactyly, anonychia or onychodysplasia or even hemimelia [4,8]. OAS may be associated with congenital cutaneous aplasia affecting the abdomen and knee, supernumerary nipples, microphthalmia and stunted growth [4].

The associated vascular anomalies are represented by *Cutis marmorata telangiectatica* (red or purplish skin reticulations) is observed in 12% of cases before the age of 1 year due to the thickening and maturation of the skin after this age [10]. Other vascular abnormalities have been described such as pulmonary hypertension, portal hypertension and retinal hypervascularization. Various cardiac malformations have been described, such as inter-atrial or inter-ventricular communication or aortic coarctation, making cardiac assessment systematic. Neurological abnormalities are represented by variable hypoplasia of the corpus callosum or even its complete agenesis, periventricular calcifications and microcephaly. Neuroimaging can also demonstrate asymmetry or dysmorphism of the lateral ventricles, hyperechogenicity of the mid-frontal gyri and basal ganglia, or agenesis of the pituitary stalk. Epilepsy, more common in recessive forms, is of the focal type and is believed to result from a primary cerebral anomaly underlying the osteocutaneous lesions of the vertex. Stomatological damage has also been described, such as a gingival cleft reported in several members of the same family or lip and palate [9,11].

## **Diagnostic**

SAO is based on major criteria which are congenital cutaneous aplasia (localized on the vertex with more or less significant aplasia of the underlying cranial bone), involvement of the extremities of the limbs (bilateral, often asymmetrical) and presence of a family history of ODS. Minor criteria are represented by *marmorata telangiectatica congenita* (CMTC), cardiac or vascular involvement. We can also associate other causes such as neurological damage. The presence of two major criteria is considered sufficient to make the diagnosis of ODS, as is the case in our patient. The association of a major criterion and a minor criterion places ODS at the head of differential diagnoses [11].

## **Treatment :**

The goal of treatment is to achieve complete closure of the skin-osseous defect before the occurrence of cerebral complications such as meningitis, hemorrhage or brain trauma [8, 9,10]. This treatment can be surgical repair, conservative or a combination of the two [9]. The choice of appropriate therapeutic modality in the initial phase of management of ODS improves the prognosis of the disease and is based on the size of the cutaneous aplasia, the

general condition of the patient, the presence of bone aplasia or associated lesions. It also seems judicious to us to also include the socio-cultural and economic conditions of the parents and the quality of any local care services [6, 7,8].

When the cutaneous-osseous defect is not very large at the vertex, total closure can be achieved after several months of local care. On the other hand, with a large defect, closure requires secondarily or immediately the use of reconstructive surgery by skin graft which can be associated with conservative treatment [12]. However, the initial choice remains difficult, since a prolonged period of 7 months during which a complete closure of a defect of only 4.5 cm in diameter was noted, thanks to the daily application of a conservative treatment (Integra) , can be quite sufficient to expose one to cerebral complications. Indeed, the mortality rate reported in the literature, mainly attributed to meningeal or cerebromeningeal infection and bleeding from the sagittal sinus, is approximately 20% [8,11,12].

## Conclusion

Adams-Oliver syndrome has been considered to be autosomal dominant. This observation exemplifies occasional and uncomplicated SAO. The absence of comprehensive gene mapping in SAO, and thus of any genetic counseling, prenatal morphological ultrasonography, is making subsequent pregnancies crucial in evolutionary terms.

## Ethical Approval:

As per international standards or university standards written ethical approval has been collected and preserved by the author(s).

## Consent

As per international standards, parental written consent has been collected and preserved by the author(s).

## References

- [1] Meena Balasubramaniana,\*, Amanda L. Collins b. Aplasia cutis congenita, terminal limb defects and periventricular leukomalacia in one sibling with minor findings in the other- probable autosomal recessive Adams-Oliver Syndrome. European Journal of Medical Genetics 52 (2009) 234–238.
- [2] Adams FH, Oliver CP. Hereditary deformities in man: due to arrested development. J Hered. 1945;36:3e7.



- [3] Sankhyan N, Kaushal RK, Jaswal RS. Adams-Oliver syndrome: a case with complete expression. *J Dermatol.* 2006; 33(6).
- [4] Kevin J. Renfree, MD, Paul C. Dell Distal Limb Defects and Aplasia Cutis: Adams-Oliver Syndrome. *J Hand Surg Am.* Vol. 41, July 2016.
- [5] Jaeggi E, Kind C, Morger R. Congenital scalp and skull defects with terminal transverse limb anomalies (Adams-Oliver syndrome): report of three additional cases. *Eur J Pediatr.* 1990 ; 149(8):565e566.
- [6] Sankhyan N, Kaushal RK, Jaswal RS. Adams-Oliver syndrome: a case with complete expression. *J Dermatol.* 2006; 33(6):435e436.
- [7] S. Diabira b, H. Belliard a, A. Hamlat b Adams-Oliver syndrome: A case with minimal expression, *Pediatric Archives*, Volume 17, Issue 10, October 2010, Pages 1460-1464
- [8] S. Yéo, P Perrot, F Bellier-Waast, To David, F Duteille - Hand surgery, 2010 - Adams-Oliver syndrome. About a clinical case: The Adams-Oliver syndrome. A report box *Hand Surgery*; Volume 29, Issue 4, September 2010, Pages 274-276
- [9] Lehman A, Wuyts W, Patel MS, Adams-Oliver Syndrome, Book from University of Washington, Seattle, Seattle (WA), 15 Apr 2016
- [10] W. Kojmane, F. Hmami, S. Atmani; Adams-Oliver syndrome and cutis marmorata telangiectatica congenita; Department of neonatology and neonatal intensive care, CHU Hassan II, Fez, Morocco, annder.2018.11.009
- [11] M. Messerer, S. Diabira, H. Belliard, A. Hamlat, Adams-Oliver syndrome: about a case of minimal expression, Vol 17 - No. 10, P. 1460-1464 - October 2010
- [12] Olga Ntumba-Tshitenge, Célestin Kaputu-Kalala-Malu, Caritas Mukampunga, Kavulu Mayamba Mukendi, Circumscribed cutaneous aplasia of the scalp in a Rwandan child: about an observation *Pan African Medical Journal.* 2014 ; 19:226