

## **Case report**

### **Abdominal Situs inversus with jejuno-ileal atresia and polysplenia: A case report.**

#### **Abstract**

The presence of an abnormally positioned organ is known as situs ambiguous. Polysplenia is defined as the presence of more than one spleen. This is a case of a baby girl antenatal diagnosed to have bowel dilatation and at birth presented with gross abdominal distention and bile-stained aspirate. Derotation of the distal apple peel ileal deformity and alignment of opposing mesentery and end-to-end jejuno-ileal anastomosis was done. Total small bowel length of 37 cms was preserved. Post-operative period was uneventful and she was gradually weaned from total parenteral nutrition to full feeds by day 17. An important aspect to consider is that derotation for volvulus is contrary to the normal derotation of malrotation / volvulus and should be performed in a clockwise direction not anticlockwise. Other gastrointestinal anomalies associated with situs inversus are duodenal atresia, annular pancreas, biliary atresia, preduodenal portal vein, diaphragmatic hernia, lung cyst, genitourinary anomalies, ear, eye, and vertebral defects. Surgical principles remain same as for classic cases, though if there is any midgut volvulus derotation has to be performed in clockwise direction as volvulus in situs inversus will occur in anti-clockwise direction.

**Keywords:** Situs Inversus, Polysplenia, Jejuno-ileal atresia.

#### **Introduction**

Situs inversus viscerum, is described as reversal of the internal body organs which can be complete (totalis) where both the thoracic and abdominal organs are reversed or might be partial (partialis) where either the thoracic or abdominal organs are reversed [1]. The presence of an abnormally positioned organ is known as situs ambiguous. Polysplenia is defined as the presence of more than one spleen. It is associated with situs inversus in about 20% of the cases. Jejuno-ileal atresia is a common cause of intestinal obstruction in neonates and its incidence is about 1 in 5000 live births. Having these three conditions in association is extremely rare.

#### **Case Report**

This is a case of a baby girl antenatal diagnosed to have bowel dilatation and at birth presented with gross abdominal distention and bile-stained aspirate. Abdominal radiograph showed dilated bowel loops (Fig 1(a)), and contrast enema revealed microcolon. At laparotomy multiple intestinal atresia (Fig 1(b)) with Type 3b jejuno-ileal atresia (apple peel appearance), situs Inversus abdominis and polysplenia (in right upper quadrant) were noted. Resection of 10cm of

dilated jejunum just proximal to atresia was done along with resection of two sites of ileal atresia. Derotation of the distal apple peel ileal deformity and alignment of opposing mesentery and end-to-end jejuno-ileal anastomosis was done. Total small bowel length of 37 cms was preserved. Post-operative period was uneventful and she was gradually weaned from total parenteral nutrition to full feeds by day 17. An interrupted Inferior vena cava (IVC) and ridge in the descending aorta with a tiny inlet ventricular septal defect was noted on cardiac evaluation. Further, the findings were confirmed with a CT Angiogram which showed focal mild narrowing of the aorta just distal to the left subclavian artery with mild post stenotic dilatation; there was an absent hepatic segment of the IVC with the hepatic veins draining into the subclavian vein. The baby was discharged on day 27 of life on full oral feeds.

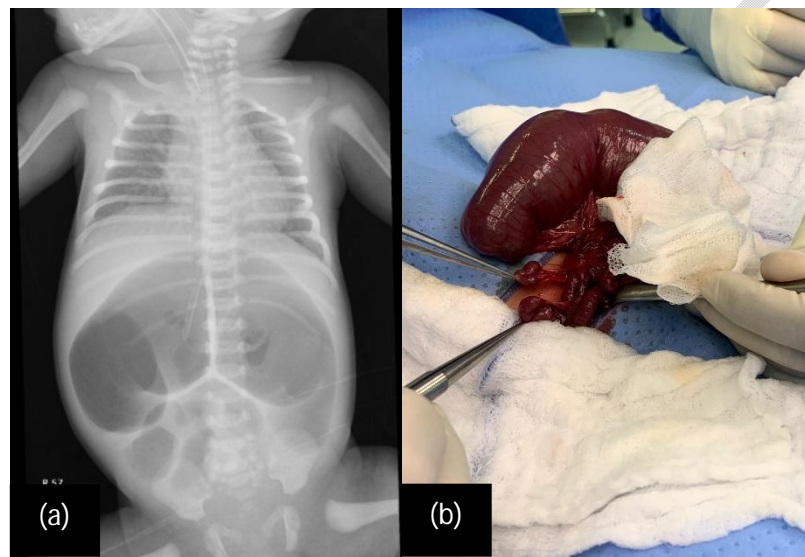


Fig. 1 (a): Abdominal X-ray done pre-operatively with dilated bowel loops with the tip of orogastric tube in right hypochondrium; (b): Intra-operative findings showing multiple atresia

## Discussion

Situs inversus is rare with a prevalence of 1 in 10,000 of the general population. The genetics of situs inversus are complex and multifactorial and largely unknown though, maternal diabetes, retinoic acid exposure, conjoined twinning, cocaine abuse, and consanguinity are all implicated. The embryology has not been well established however, the rotational anomaly can cause a vascular accident due to midgut volvulus during intrauterine period which could be the cause of multiple atresia. Situs inversus is generally asymptomatic and is diagnosed incidentally but when this is associated with atresias or midgut volvulus, presentation is quite soon after birth in the neonatal period (2). An important aspect to consider is that derotation for volvulus is contrary to

the normal derotation of malrotation / volvulus and should be performed in a clockwise direction not anticlockwise. Other gastrointestinal anomalies associated with situs inversus are duodenal atresia, annular pancreas, biliary atresia, preduodenal portal vein, diaphragmatic hernia, lung cyst, genitourinary anomalies, ear, eye, and vertebral defects(3).

Sporadic cases have described the presence of polysplenia, situs inversus abdominus and multiple intestinal atresia and are rarely reported in the English literature (4). Apart from the case presented here, only a single case report could be retrieved highlighting the rare association of these three entities [5]. Challenge in these situation is not the situs abdominis or the multiple speneculi but it's the multiple atresia with Type 3b association. There is always a risk of short bowel with Type 3b, and when this is associated with multiple atresia we need to be extra careful in how much bowel to resect. The length of dilated proximal jejunum and the length of remaining distal ileum should be adequate enough to prevent any short gut syndrome.

Situs inversus in association with polysplenia and multiple JIA is an extremely rare association. Preoperative diagnosis of situs inversus is often missed in spite of some tell-tale sign. Plain radiographs should be carefully looked for in cases with malrotation or jejunoileal atresias. Surgical principles remain same as for classic cases, though if there is any midgut volvulus derotation has to be performed in clockwise direction as volvulus in situs inversus will occur in anti-clockwise direction.

**Declaration: Informed consent for publication was taken from the parents**

## References

1. Ruben GD, Templeton JM, Ziegler MM: Situs inversus: the complex inducing neonatal intestinal obstruction. *J Pediatr Surg.* 1983, 18:751-6.
2. Abdur-Rahman LO, Adeniran JO, Taiwo JO. Concurrent dextrogastrica, reverse midgut rotation and intestinal atresia in a neonate. *J Indian Assoc Paediatr Surg.* 2007;12:228–230.
3. Ruben DG, Templeton MY, Ziegler MM. Situs inversus: the complex inducing neonatal intestinal obstruction. *J Pediatr Surg.* 1983;18:751–6.
4. Nawaz A, Matta H, Hamchou M, Jacobez A, Trad O, Al Salem AH. Situs inversus abdominus in association with congenital duodenal obstruction: a report of two cases and review of the literature. *Pediatr Surg Int.* 2005;21:589–92.
5. Chinya, Abhishek et al. "Situs Inversus Abdominalis, Polysplenia, Complex Jejunal Atresia And Malrotation In A Neonate: A Rare Association". *International Journal Of Surgery Case Reports*, vol 56, 2019, pp. 93-95.

UNDER PEER REVIEW