

Accidental Ingestion of Laryngoscope Bulb During Emergency Endotracheal Intubation: A Rare Event

Abstract:

Accidental ingestion or aspiration of foreign bodies during endotracheal intubation is a rare but potentially life-threatening complication. This report highlights the accidental ingestion of a laryngoscope bulb during emergency intubation and its successful management. A 58-year-old male with multiple comorbidities, including diabetes mellitus, hypertension, and morbid obesity, underwent endotracheal intubation due to respiratory distress. Post-intubation, an X-ray revealed a laryngoscope bulb in the stomach, which was naturally expelled via the stool. Proper equipment checks before and after intubation are crucial, and guidelines should address the management of foreign body ingestion or aspiration during intubation.

Keywords: Accidental ingestion, Laryngoscope bulb, Endotracheal intubation, foreign body, Airway management.

Introduction

Endotracheal intubation is a routine procedure frequently performed in the operating room and in emergencies to maintain the airway and breathing.^[1] There are numerous complications of this procedure including hypoxia, trauma to tissues, and esophageal intubation.^[2] Rarely accidental aspiration or ingestion of foreign bodies like dentures and parts of equipment used for intubation occur. We present one such case of accidental ingestion of a laryngoscope light bulb.

Case Report

A 58-year-old male, with a known case of hypertension, diabetes mellitus, morbid obesity, and chronic non-healing diabetic ulcer on his left leg came to the emergency department with acute onset breathlessness. After the primary survey and simultaneous resuscitation, he was found to have left lung consolidation. The airway assessment was done with the Mococho score which is routinely used to predict difficult intubation in critically ill. The score was 9. In view of hypoxemia, and respiratory distress, endotracheal intubation with mechanical ventilation was planned, macintosh laryngoscope was used for intubation, on laryngoscopy glottic visualization was Cormack lehane grade 3, endotracheal intubation was achieved with the help of bougie. Post-intubation air entry is bilateral and equal, connected to a mechanical ventilator in volume-controlled mode. Post-intubation x-ray showed a laryngoscope bulb in the fundic region (Figure1),

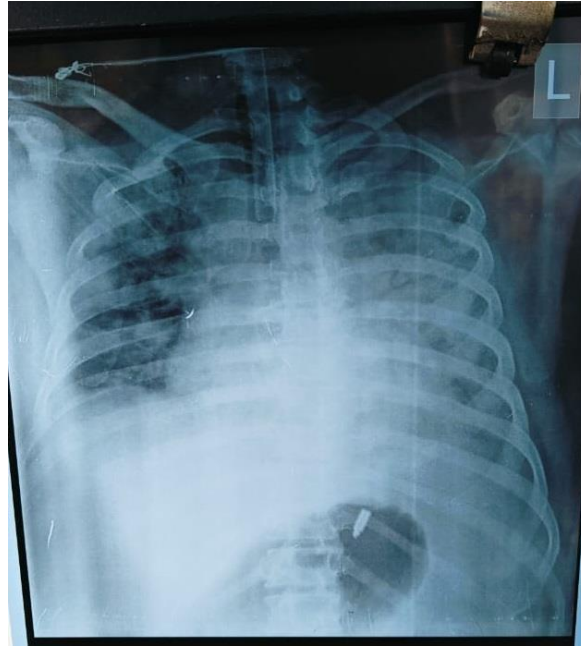


Figure 1: X-ray showing a laryngoscope bulb in the fundic region of the stomach

The clinical abdominal examination and ultrasound were normal. A gastroenterology reference was taken, and conservative management and the initiation of enteral nutrition with dietary fiber supplementation were advised. Subsequently, a day 2 abdomen chest X-ray showed no bulb in the stomach. Subsequently, the bulb was found intact in the patient's diaper.

Discussion

Ingestion of a laryngoscope bulb is a rare but potentially threatening complication.^[2] A few cases have been reported where a laryngoscope's bulb or other components were either aspirated or swallowed. Thapa et al. documented a case involving a lost laryngoscope bulb during endotracheal intubation in a neurology patient,^[3] a case of ingestion of broken glass of a laryngoscope bulb in a patient experiencing seizures was reported by Sklar and Tandberg.^[4] Saurabh Sharma et al reported a 55 years male with intracranial hematoma ingested a laryngoscope bulb following endotracheal intubation, the patient started on high fiber diet and after 4 days, the laryngoscope bulb was retrieved from the stool of the patient.^[5] Muhamed S et al reported a 68-year-old female who came to the emergency department with dyspnea, the patient ingested a laryngoscope bulb during intubation after 3 days bulb was retrieved from the stools of the patient.^[6] Zeynep Ince et al reported that a full-term female newborn ingested a laryngoscope bulb during endotracheal intubation to suction meconium-stained amniotic fluid from the trachea. The infant expelled the bulb by vomiting a few hours later.^[2] Naumovski et al reported a male newborn ingested a laryngoscope bulb during intubation for meconium-stained amniotic fluid, the ingested bulb was later passed naturally in the infant's feces without any complications^[7] and ozmert M.A.et al reported a premature male neonate ingested a laryngoscope light bulb following endotracheal intubation. The bulb was subsequently passed naturally in the infant's feces without any complications.^[1] In our case, no harm was caused to the patient. We recognized immediately that the patient swallowed the bulb rather than aspirated. Post-intubation x-ray showed a laryngoscope bulb in the fundic region. Subsequently, the bulb was found in the diaper of the patient intact. Direct laryngoscopes tend to have more detachable small parts compared to video laryngoscopes.

They need to be checked before and after intubation. The use of a video laryngoscope during difficult intubation is recommended by various guidelines.^[8] Also, a review of multiple difficult airway guidelines in critically ill patients showed no information regarding the management of patients who aspirated foreign bodies into aerodigestive tracts during intubation.

Conclusion

It is essential to ensure proper checking of the integrity of airway equipment both before and after endotracheal intubation. Serious and life-threatening complications can arise if the bulb is aspirated during intubation. We recommend using video laryngoscopes during difficult intubation as suggested by various guidelines in cases of difficulty airway. This incident also highlights the importance of having a second laryngoscope available for emergency intubations. We suggest various authorities of airway management in critically ill and general anesthesia include guidelines for managing foreign bodies in the aerodigestive tract during intubation.

References

1. Özdemir ÖM, Koçyiğit A, Çiçek C, et al. An unusual complication of endotracheal intubation: ingestion of a bulb in a premature neonate. *Turk J Pediatr*. 2016;58(1):119-120.
2. Ince Z, Tuğcu D, Coban A. An unusual complication of endotracheal intubation: ingestion of a laryngoscope bulb. *Pediatr Emerg Care*. 1998;14(4):275-6.
3. Thapa L, Paudel R, Basnet A, et al. A rolling blackout oral cavity. *J Coll Med Sci Nepal* 2010;6(3):44-5.
4. Sklar DP, Tandberg D. Glass ingestion from fracture of a laryngoscope bulb. *J Emerg Med* 1992;10(5):569-71.
5. Sharman, S., Gupta, S., Nagyan, T., et al. A Case of Ingested Laryngoscope Bulb During Emergency Endotracheal Intubation. *Indonesian Journal of Medical Sciences and Public Health*. 2020;1(2): 51 – 53.
6. Muhamed S, Mathew S, Rao BM, et al. A case of ingested laryngoscope bulb during emergency endotracheal intubation. *Saudi J Anaesth*. 2017;11(2):259.
7. Naumovski L, Schaffer K, Fleisher B. Ingestion of a laryngoscope light bulb during delivery room resuscitation. *Pediatrics*. 1991;87(4):581-2.
8. Higgs, A., McGrath, B. A., et al. Guidelines for the management of tracheal intubation in critically ill adults. *British journal of anaesthesia*. 2018;120(2): 323-352.