

## **Case report**

### **Septate gallbladder a rare anatomical variation:About two cases**

#### Abstract :

Diaphragm or septate gallbladder is a rare anatomical variation, whose pathophysiology has not been elucidated. It is often discovered incidentally intraoperatively and requires appropriate management by an experienced surgeon for dissection and individualization of the cystic pedicle elements, which the use of intraoperative cholangiography may facilitate.

Keywords : Septate gallbladder; diaphragm gallbladder; anatomical variation; cholecystectomy; cystic duct

#### Introduction :

Diaphragm or septum gallbladder is an uncommon morphological abnormality of the gallbladder. It accounts for 0.1% of all morphological anomalies of the gallbladder. It may reside asymptomatic or be uncovered incidentally during a radiological exam for another pathology, or be revealed by chronic abdominal pain or a complication such as cholecystitis or biliary peritonitis. We report here two cases of patients suffering from lithiasis of the gallbladder, with incidental discovery of a vesicular diaphragm during laparoscopy.[1]

#### Caserepresentation :

##### 1st case:

We present the case of a 45-year-old male with no medical history, who suffered from a biliaryhepatic colic in the past 2 months before his hospitalization.

Clinical examination revealed tenderness of the right hypochondrium.

Abdominal ultrasound revealed a lithiasis gallbladder with no other anomaly and without dilatation of the bile ducts,(figure 1).

Blood count and liver function tests were unremarkable.

The patient was admitted to the operating room, and laparoscopic surgical exploration revealed the presence of a gallbladder with a transverse septum(figure 2).

The surgical procedure consisted of retrograde laparoscopic cholecystectomy.

The post-operative follow-up was normal, and the patient was discharged on D-1 post-op.

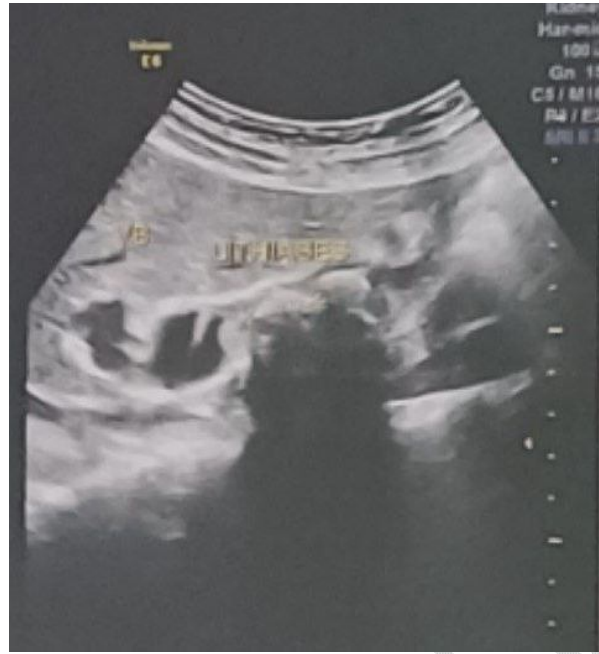

Figure 1 : An ultrasound image of the lithiasis gallbladder

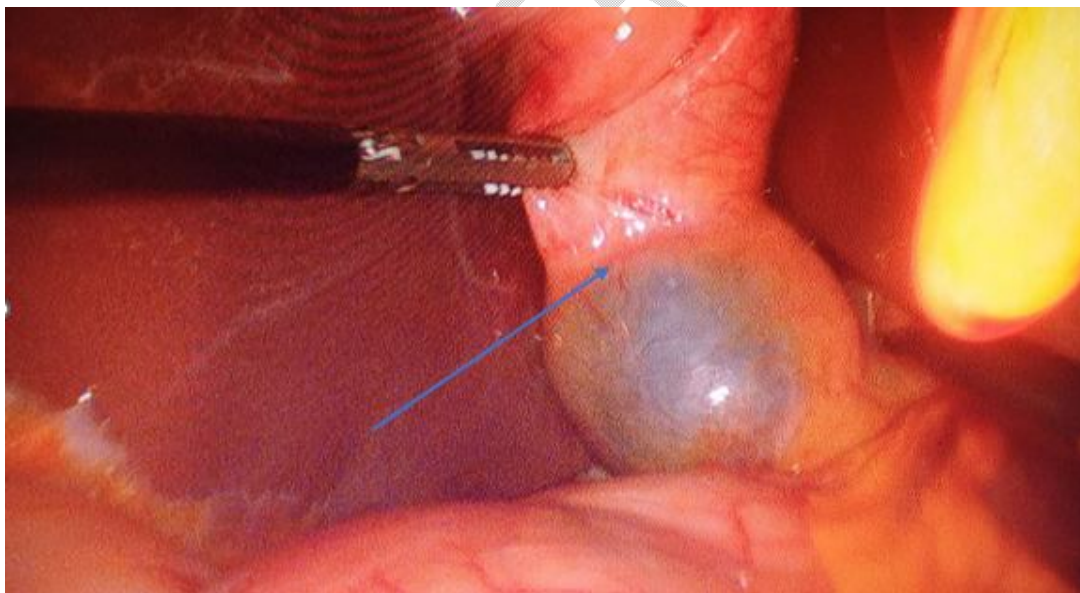


Figure 2 : Perioperative image of the gallbladder showing the septate

## 2nd case

We present the case of a 36-year-old female with no medical history who suffered from [biliaryhepatic](#) colic in the past 6 months before her hospitalization.

Clinical examination revealed tenderness of the right hypochondrium.

Abdominal ultrasound revealed a lithiasis gallbladder with no other anomaly and without dilatation of the bile ducts

Blood count and liver function tests were unremarkable.

The patient was admitted to the operating room, where laparoscopic surgical exploration revealed a gallbladder with a transverse septum that was confirmed after the examination of the cholecystectomy specimen (figure 3)

The surgical procedure consisted of a retrograde laparoscopic cholecystectomy,

The post-operative follow-up was normal, and the patient was discharged on D-1 post-op.

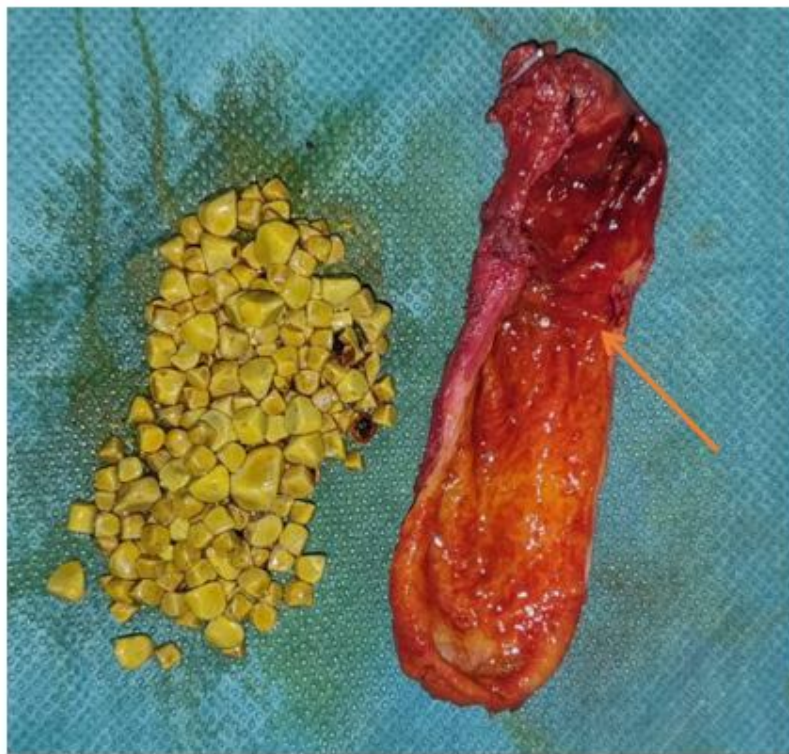

Figure 3 : Specimen of the gallbladder showing the transverse septum

## Discussion :

### *Embryology and pathophysiology*

Development of the gallbladder begins at the 4<sup>th</sup> week of embryogenesis, from the hepatic bud in the distal foregut. The hepatic [buddiverticulum](#) gives rise to the hepatic diverticulum and a smaller diverticulum that forms the gallbladder and bile duct [2,3]. Subsequently, the extra-hepatic bile ducts become obliterated by endodermal cells and then recanalize, a defect in the recanalization of the main bile duct resulting in biliary atresia [4]. Several hypotheses exist to explain the formation of

diaphragms or septa within gallbladders [5]. Inflammation of the gallbladder may produce internal compartmentalization with one or more septa [6].

The septate gallbladder is defined by the existence of a septum separating the organ into two compartments. When the septum is longitudinal, it is called a bilobed gallbladder, and when a transverse septum separates the fundus from the rest of the gallbladder, it is called an hourglass gallbladder [1].

In cases of a bifid or bilobed gallbladder, incomplete recanalization results in a longitudinal septum. Conversely, if recanalization leaves a transverse septum, the gallbladder appears hourglass-shaped. By approximately 6-7 weeks of development, the gallbladder is linked to the duodenum via a translucent bile duct. Bile secretion starts around the 12th week of embryonic development.[7]

These gallbladder septas are most often simple, but gallbladders with multiple septa have also been described, as well as post-inflammatory adhesions and compartmentalization of the gallbladder[6]. Multiple septate gallbladders, are defined by the presence of multiple septa segmenting the gallbladder lumen, is an uncommon condition with only a small number of cases reported in the literature.[8].

#### *Classification:*

In 1926, Boyden described two variations of gallbladder anomalies: vesica fellea divisa, which is a bilobed or double gallbladder with a single neck, and vesica fellea duplex, a double gallbladder with two distinct cystic components. The vesica fellea duplex has been further categorized into two types: the H-shaped type, where the two cystic components each enter the common duct separately, and the Y-shaped type, where the cystic components merge before entering the common duct.[9].

In 1936, Gross classified congenital anomalies by categorizing double vesicles into types A through E, detailing the position of the accessory organ and the distribution of cystic components. Harlafti 1977 classification is the most comprehensive and widely accepted [10].

#### *Pathophysiology and clinic:*

The impact of the existence of a septum within the gallbladder was studied in 2006 by Krishnamurthy et al, who analyzed gallbladder filling and emptying in 17 subjects, 7 with bilobed gallbladders and 10 with non-segmented gallbladders. The study showed that bile entry into the gallbladder was similar in both groups. In patients with segmentation, overall emptying was lower, mainly due to poor emptying of the distal segment[11].

Clinically, this malformation is often asymptomatic, and may be discovered incidentally on radiological examination [1,12]. Bile stagnation in the proximal chamber (fundus side) favors stone formation [1]. Single or multiple diaphragm gallbladder lithiasis may present as cholecystitis, pancreatitis or peritonitis. Clinical manifestations of alithiasis result from the punctiform communication between the two chambers, a source of inflammation or infection. This communication has long been responsible for chronic abdominal pain, and can be complicated by alithiasic cholecystitis. This complication results from dyskinesia of the vesicular wall, with infection of the bile in the proximal chamber[13].

#### *Radiological examination and surgical treatment*

The first-line paraclinical examination for right hypochondrium pain is abdominal ultrasound. Abdominal ultrasound remains the most accessible examination for the diagnosis of lithiasis gallbladder, enabling the study of its measurements and wall, visualization of lithiasis,

detection of complications and, in some cases, anatomical variations [12,14].MRI is the most effective paraclinical examination for visualizing the gallbladder, enabling mapping of the bile ducts and offering greater specificity and sensitivity for diagnosing morphological anomalies of the bile ducts [15]. If a lithiasis gallbladder is diagnosed without other abnormalities, the surgeon must recognize the anatomical variation and treat intraoperatively. In this case, the use of intraoperative cholangiography clarifies the anatomy[16].

Septate biliary vesicles pose a challenge in surgery, both in terms of differentiation and dissection, as their clinical form is similar to that of a main bile duct adherent to the gallbladder. Consequently, identification and definition of the biliary anatomy are essential to prevent damage to the biliary system. In such cases, complete anatomical dissection of the peritoneal tissue and prevesicular fat is essential to clearly expose the junction of the cystic duct with the gallbladder. The presence of a septum is associated with a high risk of complication during cholecystectomy[12].

During the surgical procedures, we performed meticulous dissection of the elements of Calot's triangle until visualization of the cystic duct abutment at the level of the main bile duct.

## Conclusion:

The diaphragm or septum gallbladder is a rare anatomical variation, and its shape may be confused with the main bile duct, leading to iatrogenic lesions of the bile ducts, faulty dissections or sub-total cholecystectomies. We reiterate the importance of a meticulous knowledge of surgical anatomy and the different anatomical varieties for proper management of this type of case.

## DISCLAIMER (ARTIFICIAL INTELLIGENCE)

Author(s) hereby declare that NO generative AI technologies such as Large Language Models(ChatGPT, COPILOT, etc) and text-to-image generators have been used during writing or editing of manuscripts.

## CONSENT

As per international standards or university standards, patient(s) written consent has been collected and preserved by the author(s).

## ETHICAL APPROVAL

Authors declare that the ethical approval has been exempted by my establishment

## References

1. FLANNERY, M. G. et CASTER, M. P. Congenital hourglass gallbladder. *Southern medical journal*, 1957, vol. 50, no 10, p. 1255-1258.
2. Hisami Ando; Embryology of the Biliary Tract. *Dig Surg* 1 June 2010; 27 (2): 87–89.  
<https://doi.org/10.1159/000286463>
3. KEPLINGER, Kara M. et BLOOMSTON, Mark. Anatomy and embryology of the biliary tract. *Surgical Clinics*, 2014, vol. 94, no 2, p. 203-217.
- 4.DACHMAN, Abraham H. et SCHNECK, Carson. Embryology of the gallbladder. In : *Imaging atlas of the normal gallbladder and its variants*. CRC Press, 2018. p. 13-20.



5. ESPER, Eduardo, KAUFMAN, Dixon B., CRARY, Gretchen S., *et al.* Septate gallbladder with cholelithiasis: a cause of chronic abdominal pain in a 6-year-old child. *Journal of pediatric surgery*, 1992, vol. 27, no 12, p. 1560-1562.
6. Hamlin JA: Anomalies of the biliary tract, in Berk JE, Haubrich WS, Kalser MH, *et al* (eds): Bockus Gastroenterology. Philadelphia, PA, Saunders, 1985, pp 3486-3498
7. Housset C, Chrétien Y, Debray D, Chignard N. Functions of the Gallbladder. *ComprPhysiol*. 2016 Jun 13;6(3):1549-77. doi: 10.1002/cphy.c150050. PMID: 27347902.
8. Faure, J.P., Doucet, C., Scepi, M. *et al.* Abnormalities of the gallbladder, clinical effects. *Surg Radiol Anat* **30**, 285–290 (2008). <https://doi.org/10.1007/s00276-008-0332-7>
9. Boyden EA: The accessory gallbladder: an embryological and comparative study of aberrant biliary vesicles occurring in man and the domestic mammals. *Am J Anat*. 1926, 38:177-231. 10.1002/aja.1000380202
10. Harlaftis N, Gray SW, Skandalakis JE: Multiple gallbladders. *Surg Gynecol Obstet*. 1977, 145:928-34.
11. Krishnamurthy, Gerbail T.a; Krishnamurthy, Shakuntalaa; Milleson, Thomasb; Brown, Paul H.d; Urstadt, Donna S.c. Segmentation of the gallbladder: Effect on bile entry and exit and its clinical relevance in a patient with abdominal pain. *Nuclear Medicine Communications* 28(2):p 109-115, February 2007. | DOI: 10.1097/MNM.0b013e328013eb2f
12. ADEAR, H. *et* BARKI, Y. Multiseptate gallbladder in a child: incidental diagnosis on sonography. *Pediatric radiology*, 1990, vol. 20, p. 192-192.
13. ABID, M., MZALI, R., FERIANI, N., *et al.* Gallbladder diaphragm: an unusual cause of acute cholelithiasis complicated of biliary peritonitis. *La Revue de médecine interne*, 2010, vol. 31, no 9, p. e16-8.
14. SMERECZYŃSKI, Andrzej, KOŁACZYK, Katarzyna, *et* BERNATOWICZ, Elżbieta. Optimization of diagnostic ultrasonography of the gallbladder based on own experience and literature. *Journal of ultrasonography*, 2020, vol. 20, no 80, p. 29-35.
15. Omiya, Kojiro, Kazuhiro Hiramatsu, Yoshihisa Shibata, Masahide Fukaya, Masahiro Fujii, Taro Aoba, Atsuki Arimoto, Takayuki Yamaguchi, and Takehito Kato. 2021. "Preoperative Magnetic Resonance Cholangiopancreatography for Detecting Difficult Laparoscopic Cholecystectomy in Acute Cholecystitis" *Diagnostics* 11, no. 3: 383. <https://doi.org/10.3390/diagnostics11030383>
16. SINGH, Kaptan, JOSHI, Atul S., KHEMCHAND, Agrawal K., *et al.* Septate gall bladder: a surgical surprise with review of literature. *International Surgery Journal*, 2020, vol. 7, no 10, p. 3516-3518.