

Effects of *Diallium* and *Ziziphus* honey in second-degree burnson wistar rats.

Abstract :

Background :Nowadays, the use of honeys in the treatment of burns and wounds has aroused growing interest due to its anti-inflammatory, antioxidant and healing properties.

Aim : The aim of this study was to evaluate the effects of *Diallium* and *Ziziphus* honey in second degree burns on wistar rats.

Methodology :A metal cylinder with a diameter of 3 cm was heated for five minutes. In order to cause experimental burns. The rats' shaved skin was lightly pressedwith the cylinder for twenty seconds so as to induce second-degreeburns.

Results : The daily application of honey induces a healing dependent on typology and concentration. The healing rate is higher with DZ, with a score of 1.00 ± 0.63 vs 1.25 ± 0.43 for JUJ which induces almost complete tissue repair after 21 days of treatment.

Conclusion :Findings from the research confirm the use of traditional honeys for burns and wound healing.

Keywords : Honeys, burns, wounds, cicatrization

Legends :DZ : Diallium Ziguinchor et JUJ : Jujubier Podor

1. INTRODUCTION

The wide use of honey to treat different infections among Muslims and in many Islamic countries is based on the belief in the words regarding honey as stated in the Holly Quran about 1900 yearsago “and your lord inspired the bee, saying : “Take your habitations in the mountains and in the trees and in what they erect, then, eat of all fruits, and follow the ways of your Lord made easy (for you).” There comes forth from their bellies, a drink of varying colour wherein is healing for men. Verily, in this is indeed a sign for people who think [1, 2].However, honey treatment meets certain clinical conditions, which are :the viscosity of the honey, which acts as a barrier against bacteria, preventing them from colonizing the wound surface[3].Using honey to treat severe acute post-operative wound infection : After hysterectomies and cesarean sections, topical application of undiluted, crude honey has been used to treat severe acute post-operative wound infection brought on by Gram positive and Gram negative bacteria. This stops bacterial infections, shortens the time patientsneed to use antibiotics and stay in the hospital, speeds up wound healing, stops dehiscence, helps with restructure, and leaves less scars behind [4].Honey has traditionally been used as wound healer for skin conditionwounds. It has been demonstrated to speed up the healing process, for instance, in mild to moderate superficial and partial thickness burns, while there is currently insufficient evidence to support its effectiveness in treating other illnesses[5, 6].Honey is a complex mixture of 82.0% carbohydrates (sucrose, fructose, maltose), 0.3% protein, 17.0% water and 0.7% minerals, vitamins and antioxidants [7]In addition to sugars, honey has a high

mineral content and a number of vitamins, particularly the B complex and vitamin C. Ascorbic acid, pantothenic acid, niacin, and riboflavin are among the vitamins in honey, along with minerals like calcium, copper, iron, magnesium, manganese, phosphorus, potassium, and zinc [8].

In the course of our bibliographical research, no data has been discovered on the study of the healing of honey in Senegal. However, studies on healing by the use of plant extracts were conducted there by [9, 10]. Based on the above, we have been interested in looking for healing potential of honey in an experimental model of second-degree burns in Wistar rats.

2. MATERIALS AND METHODS

2.1 Sampling

Beekeepers with modern production units supplied honey samples in hermetically sealed jars. The samples were transported at the Laboratory of Pharmacognosy and Botany at the Faculty of Medicine, of Pharmacy and of Odontology of the Cheikh Anta DIOP University (UCAD) of Dakar, and then kept refrigerated until analysis began.

2.2 Animals

The rats ranged in weight from 148 to 226 g. The animals were kept in a cage with a temperature of $25 \pm 2^{\circ}\text{C}$, a 12-hour light cycle, and unlimited access to food and water. The experimental procedures were carried out in compliance with the institutional ethics committee's (CADU Research Ethics Committee) norms.

2.3 Methodology

An experimental rat burn model was used to measure healing activities [11]. Twenty rats were split up into the following four batches of five : Rats in Batch 1 are untreated. Rats in Batch 2 were given the healing medicine sulfadiazine ; in Batch 3, the rats were given Dialium Z honey (DZ); in Batch 4, the rats were given Ziziphus honey (JUJ). The rats were subsequently given an intraperitoneal injection (1 mL/100 g) of 3% chloral solution to induce anesthesia. The dorsal flanks of the rats were washed and shaved. A metal cylinder with a diameter of 3 cm was heated for 5 minutes to cause experimental burns. In order to cause second-degree burns, the cylinder was applied for 20 seconds by lightly pushing on the rats' shaved skin [12].

A system of assigning scores based on the severity of the burn was used to measure healing activities (Table 1) [13]. For 28 days, scores were evaluated every four days for twenty eight days.

2.4 Statistical analysis

Data were expressed as mean \pm standard error of the mean (SEM). GraphPad 10.0 software were used to for analyses. A one-way analysis of variance (ANOVA) followed by Dunnett's post hoc test against the control group. P-values <0.05 Table 1 : Experimental burns' evolution scores.

Table 1 : Experimental burns' evolution scores.

Score	Cicatrization process evaluation
0	Healing is complete and tissue repair is complete
1	Tissue healing is almost complete
2	Remnants of the crust remain the size of the lesion decreases (skin reconstruction)
3	All dead tissues (scabs) are removed, wounds and oozing
4	Necrotic skin is partially removed, ulcerated and oozing
5	Necrotic skin completely covers the burned area

3. RESULTS AND DISCUSSION

3.1 RESULTS

3.1.1. Evolution of deep second-degree experimental burn scores in rats without treatment and sulfadiazine application

The burned area was remained covered in necrotic skin eight days after the experimental burn was induced, corresponding to score 5. After three weeks, the burned skin showed ulceration in the absence of treatment (score 4). The experimental burn has an open, oozing wound (score 2) after 4 weeks, which indicating to a total absence of healing.

When sulfadiazine is applied on a daily basis, wound healing is much better than in the control group (Fig. 1). Fig. 2 shows photographs of burned surfaces

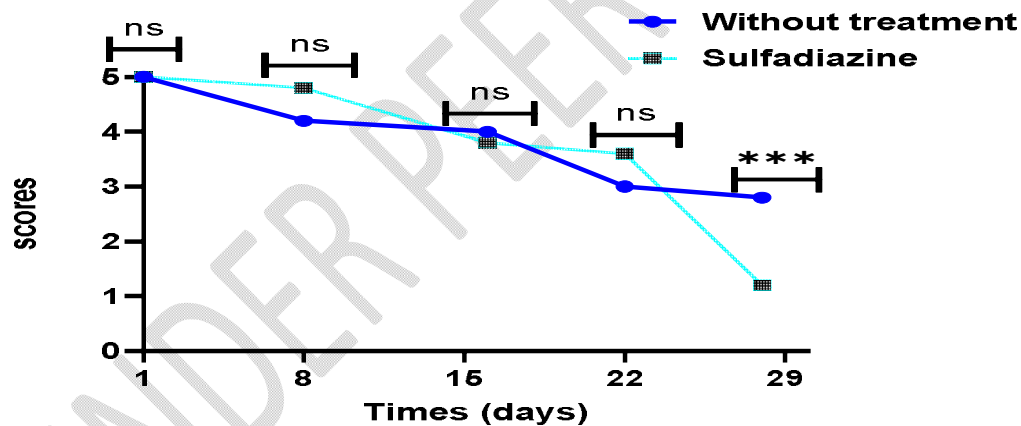


Fig. 1. Evolution of deep second-degree experimental burn scores in rats without treatment and sulfadiazine application.

ns : no significant ; *=p<0.05 ; **=p<0.01; ***=p<0.001; ****=p<0.0001

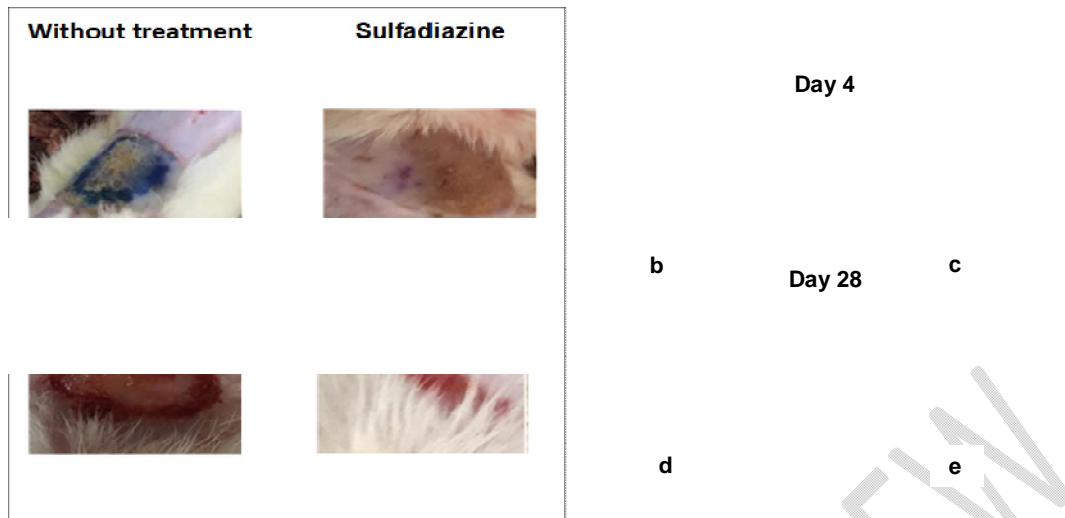


Fig.2. Photographs of burned surfaces without treatment and with sulfadiazine.

3.1.2. Evolution of deep second-degree experimental burn scores after treatment with the Dialium and Ziziphus honeys.

After 20 days, daily application of honey samples showed nearly total tissue healing. The scores obtained are 1.2. Hair regrowth indicates that the healing process is complete after 28 days of treatment, especially when dialium and ziziphus honeys are used. Figure 2 shows the score evolution curves for each group, supported by illustrative images of the rats' healing process.

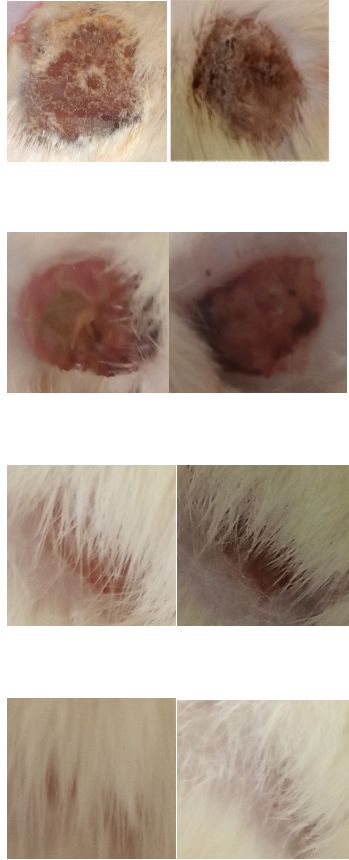


Fig. 3. Healing effect of Diallium and Ziziphus honey on experimental deep second-degree burns (Photographs)

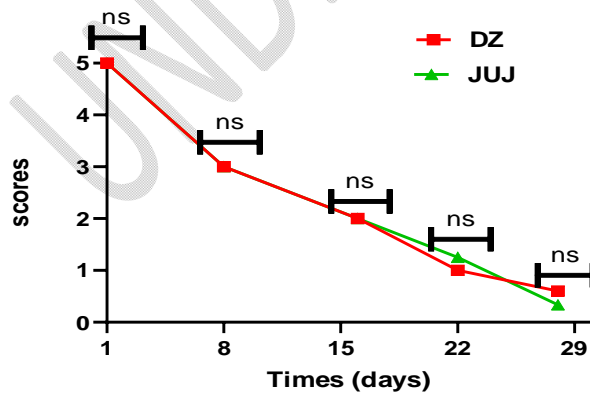


Fig 4 : Score evolution curves for Diallium honey and Ziziphus honey

ns : no significant

3.2 DISCUSSION

The objective of this study was to show how honeys can heal second-degree burns in Wistar rats, a model of experimental burns.

After four weeks of daily application to the burn, sulfadiazine was not linked to full recovery. Clinical trials for first-degree burns are where sulfadiazine is most frequently utilized as a reference product [14]. The fact that this study's experimental burn didn't heal after four weeks of sulfadiazine treatment indicates that it was at least a profound second-degree burn. Our findings in a second-degree burn model are consistent with a number of earlier research using honeys, and the healing rate is nearly full after three weeks [15, 16].

In the wistar rat model of experimental deep second-degree burns, honeys produce concentration-dependent wound healing. Indeed, healing is faster with DZ than JUJ honey.

Many studies have confirmed the beneficial effects of honey on ulcerous wounds [17, 18, 19 and 20]. The outcomes showed faster overall healing rates, shorter average healing periods, and better elimination of wound infection. Honey therapy has been demonstrated to be a cost-effective treatment [17].

In a research by [21], there was a reduction in both wound pain and odor; however, there was no statistically significant difference in healing time.

Honey has been shown to have some healing properties for wounds. It is a curative treatment that is applied locally in a variety of therapeutic methods. According to [22], the primary factors that facilitate burn healing are the high tonicity and acidic pH of honey. Our research indicates that application of honey to rats can help them recover their wounds. Honey's glycolytic enzyme activity provides enough energy for cell repair, which speeds up the healing process from wounds. Three essential stages of wound healing are collagen synthesis, wound contraction, and epithelialization. Thus, intervention during any of these phases can either increase or decrease the healing process' collagen production phase [23].

According to [24], plants' flavonoids and tannins are involved in perfect healing. Plants have antibacterial, antioxidant, and anti-inflammatory qualities in addition to the processes involved in wound healing [25, 26]. Several varieties of honey have also been shown to possess these qualities [27, 28, 29 and 30]. Both manuka honey have demonstrated in vivo activity and can be used to treat burns, infected wounds, and ulcers [31].

We saw that there was no smell and that there was sensation that caused the wounds to be scratched throughout our manipulations. Other writers have noted similar results when employing honeys in surgical wound treatments [32].

4. CONCLUSION

The purpose of this study was to assess the ability of Senegalese honeys to cure second-degree burns in an experimental model of Wistar rats. After 22 days, DZ honey had almost fully repaired the tissue. This therapeutic action might be related to the methylglyoxal and hydrogen peroxide present. The outcomes demonstrate the honeys therapeutic potential for treating second-degree burns, which would support their application in conventional burn and wound care settings. Future research ought to concentrate on how honey aids in the healing of surgical incisions.

8. REFERENCES

1. Ahmadi FM, Sare SH, Yusof MA, Khamverdi Z. Antibacterial Activity of Honey on Cariogenic Bacteria. Journal of Dentistry, Tehran University of Medical Sciences. 2013 : 10 :1
2. Holy - Qur'an Chapter 16 (The Bee). Quoted from The Holy- Qur'an : Original Arabic Text with English Translation and selected commentaries. Saba Islamic Media; 2013.
3. Subrahmanyam M, Archan H, Pawar SG. Antibacterial activity of honey on bacteria isolated from wounds. Annals of Burns and fire disasters. 2001 ; XIV :1.
4. Cooper R. Honey as an effective antimicrobial treatment for chronic wounds: is there a place for it in modern medicine? Chronic Wound Care Management and Research. 2014;1 : pp 15-22. DOI : <https://doi.org/10.2147/CWCMR.S46520>
5. Evans J, and Flavin S. Honey : a guide for healthcare professionals. Br J Nurs. 2008 ;17(15):S24, S26, S28-30. <https://doi.org/10.12968/bjon.2008.17.Sup6.30707>
6. Jull AB, Rodgers A, Walker N. Honey as Adjuvant Leg Ulcer Therapy trial collaborators. Randomized clinical trial of honey-impregnated dressings for venous leg ulcers. Cochrane Database Syst Rev. 2008 ;(4) CD005083. <https://doi.org/10.1002/14651858.CD005083.pub4>

7. Ndayisaba G, Bazira L, Habonimana E, Muteganya D. Clinical and bacteriological outcomes of wounds treated with honey. *J Orthop Surg*. 1993 ; 7 : 202–204. PMID : 8121994.
8. Ajibola A, Chamunorwa JP, Erlwanger KH. Nutraceutical values of natural honey and its contribution to human health and wealth. *Nutr Metab (Lond)*. 2012; 9: 61. PMID: 22716101. PMCID: [PMC3583289](https://pubmed.ncbi.nlm.nih.gov/PMC3583289/). DOI: [10.1186/1743-7075-9-61](https://doi.org/10.1186/1743-7075-9-61)
9. Sène M, Tine Y, Keita F, Zougouri KAD, Sarr A, Diatta C, Barboza FS, Ndiaye M, Sy AN and Sy G Y. In vivo anti-inflammatory and healing activities of the methanolic fraction of *Combretum glutinosum* Perr. Bark. *Phytomol. Pharmacol*. 2023 ; 2(2) : 55-63. <https://doi.org/10.56717/jpp.2023.v02i02.018>
10. Sène M, Ndiaye M, Barboza FS, Sene M, Diatta W, Sarr A, Ndiaye SA, Dieye AM and Sy GY. Activité anti-inflammatoire de l'extrait aqueux des feuilles d'*Elaeis guineensis* Jacq. (Arecaceae) sur l'œdème aigu de la patte de rat induit par la carraghénine. *Int. J. Biol. Chem. Sci*. 2016 ; 0(6) : 2568-2574. DOI : <http://dx.doi.org/10.4314/ijbcs.v10i6.13>
11. Gurung S, Škalko-Basnet N. Wound healing properties of *Carica papaya* latex: in vivo evaluation in mice burn model. *J. Ethnopharmacol*. 2009 ; 121(2) : 338-341. DOI : <https://doi.org/10.1016/j.jep.2008.10.030>
12. Hoşnüter M, Gürel A, Babuççu O, Armutcu F, Kargı E, Işıkdemir A. The effect of CAPE on lipid peroxidation and nitric oxide levels in the plasma of rats following thermal injury. *Burns*. 2004 ; 30(2) : 121-125. DOI : <https://doi.org/10.1016/j.burns.2003.09.022>
13. Adhya A, Bain J, Ray O, Hazra A, Adhikari S, Dutta G, Ray S. Healing of burn wounds by topical treatment: A randomized controlled comparison between silver sulfadiazine and nano-crystalline silver. *Majumdar, B.K. J. Basic Clin. Pharmacol*. 2015 ; 6(1) : 29-34. DOI : <https://doi.org/10.4103/0976-0105.145776>
14. Prafulla CT, Ahamed N, Keshari C, Kalpesh N. Comparative study of wound healing activity of soframycin & honey in excision wound model. *International Journal Of Pharmacy & Technology*. 2015 ; ISSN : 0975-766X ; Vol. 5, Issue No.1, 2015 : 5378-5382.
15. SFETB. (2006). Société Francophone de Brûlologie. Consulté le 23 Septembre 2024. Disponible sur <http://www.sfbbrulure.com/docs/2017/soins-locaux-brules-suivis-ambulatoire.pdf>
16. Iftikhar F, Arshad M, Rasheed F, Amraiz D, Anwar P and Gulfranz M. Effects of Acacia Honey on Wound Healing in Various Rat Models. *Phytother. Res*. 2010 ; 24 : 583–586. DOI: [10.1002/ptr.2990](https://doi.org/10.1002/ptr.2990)
17. Moghazy AM, Shams ME, Adly OA, Abbas AH, El-Badawy MA, Elsakka DM, Hassan SA, Abdelmohsen WS, Ali OS, Mohamed BA. The clinical and cost effectiveness of bee honey dressing in the treatment of diabetic foot ulcers. *Diabetes Research and Clinical Practice*. 2010 ; 89(3) : 276–281. DOI: [10.1016/j.diabres.2010.05.021](https://doi.org/10.1016/j.diabres.2010.05.021)

18. Kamaratos A, Tzirogiannis K, Iraklianos S, Panoutsopoulos G, Kanellos I, Melidonis A. Manuka honey-impregnated dressings in the treatment of neuropathic diabetic foot ulcers. *International Wound Journal*. 2014 ;11(3) : 259–263. DOI: [10.1111/j.1742-481X.2012.01082.x](https://doi.org/10.1111/j.1742-481X.2012.01082.x)
19. Al Saeed M. Therapeutic efficacy of conventional treatment combined with manuka honey in the treatment of patients with diabetic foot ulcers : a randomized controlled study. *The Egyptian Journal of Hospital Medicine*. 2013 ; 53 : 1064–1071. DOI: <https://doi.org/10.12816/0001668>
20. Imran M, Hussain MB, Baig M. A randomized, controlled clinical trial of honey-impregnated dressing for treating diabetic foot ulcer. *J Journal of the College of Physicians and Surgeons - Pakistan: JCPSP*. 2015 ;25(10) : 721–725. PMID: 26454386 DOI: <https://doi.org/10.2015/JCPSP.721725>
21. Shukrimi A, Sulaiman AR, Halim AY, Azril AA. Comparative study between honey and povidone iodine as dressing solution for Wagner type II diabetic foot ulcers. *Med J Malaysia*. 2008 ; 63(1) : 44–46. PMID: 18935732.
22. Postmes TJ, Bosch MMC, Dutrieux R, van Baare J, Hoekstra MJ. Speeding up the healing of burns with honey. An experimental study with histological assessment of wound biopsies. In *Bee products : Properties, applications and apitherapy*, Mizrahi A, Lensky Y (eds). Plenum Press: New York. 1997 : 27–37. https://doi.org/10.1007/978-1-4757-9371-0_6
23. Vyhľádalová D, Kozáková R, and Zeleníková R. Management of non-healing wounds with honey dressings : a literature review *Cent Eur J Nurs Midw*. 2018 ;9(3) : 880–888 doi : <https://doi.org/10.15452/CEJNM.2018.09.0019>
24. Sène M, Tine Y, Keita F, Zougouri KAD, Sarr A, Diatta C, Barboza FS, Ndiaye M, Sy AN and Sy G Y. In vivo anti-inflammatory and healing activities of the methanolic fraction of *Combretum glutinosum* Perr. Bark. *Phytomol. Pharmacol*. 2023 ; 2(2) : 55-63. <https://doi.org/10.56717/jpp.2023.v02i02.018>
25. Sarr A, Dieng SIM, Sene M, Diatta C, Diatta KB, Diatta W and Fall AD. Role of Condensed Tannins in the Antioxidant Activity of Seeds of *Cola nitida* (Vent.) Schott & Endl. (Malvaceae). *Euro. J. Med. Plants*. 2022 ; vol. 33, no. 12 : pp. 26-33. DOI : <https://doi.org/10.9734/ejmp/2022/v33i121111>
26. Dieng SIM, Mathieu C, Sène M, Badji DK, Sarr A, Fall AD. Anti-Inflammatory Activity of Hydro-Ethanollic Bark Extracts of *Piliostigma reticulatum* Hochst (Caesalpiniaceae) and Analysis by HPLC-DAD and HPLC-MS of its Methanol Fraction. *Journal of Drug Delivery & Therapeutics*. 2020; 10(3):97-106. DOI: <https://doi.org/10.22270/jddt.v10i3.4058>
27. Ishimwe AP, Munezero PC, Migabo H, Itangimbabazi J, Saramba E. The Effect of Honey on Bacteria Isolated from Urinary Tract Infections among Patients Attending Ruhengeri Referral Hospital. *Journal of Drug Delivery and Therapeutics*. 2024 ; 14(4):10-13. DOI: <https://doi.org/10.22270/jddt.v14i4.6104>

28. Mandal, M.D. and S. Mandal, Honey: its medicinal property and antibacterial activity. Asian Pac J Trop Biomed, 2011. 1(2): p. 15460. [https://doi.org/10.1016/S2221-1691\(11\)60016-6](https://doi.org/10.1016/S2221-1691(11)60016-6) . PMID:23569748
29. Vallianou NG, Gounari P, Skourtis A, Panagos J and Kazazis C. Honey and its Anti-Inflammatory, Anti-Bacterial and Anti-Oxidant Properties. General Medicine : Open Access. 2014 ; 02 : pp 5. <https://doi.org/10.4172/2327-5146.1000132>
30. Yupanqui Mieleles, J., et al., Honey: An Advanced Antimicrobial and Wound Healing Biomaterial for Tissue Engineering Applications. Pharmaceutics. 2022 ; 14(8). PMCid: <https://doi.org/10.3390/pharmaceutics14081663> . PMC9414000
31. Prakash A, Medhi B, Avti PK, Saikia UN, Pandhi P and Khanduja KL. Effect of different doses of Manuka honey in experimentally induced inflammatory bowel disease in rats. Phytother Res. 2008; 22(11): 1511-9. Doi: <https://doi.org/10.1002/ptr.2523>
32. Mohamed H, Salma MA, Al Lenjawi B, Abdi S, Gouda Z, Barakat N, Elmahdi H, Abraham S, Hamza AH, Al Khozaei D, Al Majid S, Al Majid H, Abdini J, Al Jaber M, Al Masseh F, Al Ali AA. The efficacy and safety of natural honey on the healing of foot ulcers : a case series. Wounds. 2015 ; 27(4): 103– 114. PMID: 25855854.