

## Case report

# Chondroblastic osteosarcoma of the mandible: An uncommon site for osteosarcoma

---

### ABSTRACT

Osteosarcoma is one of the most common types of malignant bone tumors, typically involving long bones such as the femur, tibia, and humerus. However, osteosarcomas occurring in the jaws are exceptionally rare, accounting for approximately 7% of all osteosarcoma cases and just 1% of malignancies in the head and neck region. This type of tumor usually affects individuals in their second and third decades of life. The subtypes of osteosarcoma include osteoblastic, chondroblastic, fibroblastic, small cell, and epithelioid. Chondroblastic osteosarcoma is associated with a poor prognosis, marked by a high recurrence rate, metastatic potential, and poor long-term survival outcomes.

Here, we present the case of a 65-year-old woman with a painless swelling over the left cheek for 1 year, which significantly increased in size over the past 3 months, accompanied by trismus, reduced oral intake, and weight loss. Examination revealed a non-tender, hard swelling on the left cheek measuring 20x20cm, with prominent dilated veins. The left external auditory canal was collapsed due to the mass effect. Histopathological examination resulted as chondroblastic osteosarcoma of the left mandible. Computer tomography showed a large lobulated enhancing mass occupying the left cheek, associated with bone erosion and an aggressive periosteal reaction resembling a 'sunburst' pattern involving the ramus extending to the angle of the left mandible. The patient undergone open tracheostomy, left temporary tarsorrhaphy, wide local excision of tumor, left hemimandibulectomy, left partial maxillectomy and anterolateral thigh free flap reconstruction as patient unable to tolerate neoadjuvant chemotherapy.

*Keywords: Chondroblastic osteosarcoma, sunburst appearance, partial maxillectomy, hemimandibulectomy*

### 1. INTRODUCTION

Osteosarcoma is a type of malignancy where the tumor cells form the osteoid or bone directly. Long bone such as femur, tibia and humerus are the most common site for this type of primary tumor (1). Jaw osteosarcoma is extremely rare where it only comprises 6-7% of osteosarcoma and less than 1% of all head and neck malignancies (2- 5). Jaw osteosarcoma usually confined to the ramus and angle of mandible. The manifestation of jaw osteosarcoma usually presented as facial swelling, pain, parestheisa and loose teeth (3). World Health Organization defined chondroblastic osteosarcoma as a histological entity which consisted the presence of chondroid matrix as well as nonchondroid component such as bone matrix (4). This is the most common histological type of osteosarcoma (4). Due to

the rarity of jaw osteosarcoma, we report a case of lady with extensive chondroblastic osteosarcoma over her left jaw.

## 2. CASE PRESENTATION

A 65-year-old woman, with no underlying comorbidities, presented with a painless swelling over the left cheek for 1 year, which significantly increased in size over the past 3 months, accompanied by limited mouth opening, reduced oral intake, and weight loss. **There was no other swelling on the body.**

Examination revealed a non-tender, hard swelling on the left cheek measuring 20x20cm, with prominent dilated veins. The left external auditory canal was collapsed due to the mass effect. There was delay in getting proper treatment as the initially histological result from other medical centre showed inconclusive, patient decided to wait and self-monitor and only seek treatment again when the swelling suddenly increase in size for the past 3 months. Fine needle aspiration for cytology unable to yield satisfied result.

Diagnosis of chondroblastic osteosarcoma of the left mandible only able to obtain by a Trucut biopsy. Computer tomography showed a large lobulated enhancing mass occupying the left cheek, associated with bone erosion over the lateral wall of the left maxillary sinus, left pterygoid bones, and left zygomatic arch, and an aggressive periosteal reaction resembling a 'sunburst' pattern involving the ramus extending to the angle of the left mandible.

The patient was scheduled for neoadjuvant chemotherapy for 3 cycles with Doxorubicin and Ifosfamide. However, patient unable to complete the given oncological treatment due to unable to tolerate the effect of chemotherapy. The patient undergone open tracheostomy, left temporary tarsorrhaphy, wide local excision of tumor, left hemimandibulectomy, left partial maxillectomy and anterolateral thigh free flap reconstruction. The operation was combined with Plastic surgery team.

Intraoperative finding showed a large hard mass arising from left mandible and superiorly extended till base of skull and laterally extended until the lower part of zygoma and inferiorly extended till the level of hyoid bone. Anteriorly, the tumor extended till the skin over maxilla region, posteriorly extended till the posterior wall of maxilla and mastoid tip. Medially, the tumor abutting the buccal mucosa, extending superiorly to lateral wall of maxilla sparing the retromolar trigone. Left facial nerve was sacrificed and left submandibular gland was removed en bloc as the gland adhered to the mass. The operation was uneventful. Patient managed to discharge home after 18 days of hospitalization. **The patient was subsequently referred to the oncology team for further radiotherapy due to a close tumor margin (1mm). She sustained left facial nerve palsy post-operation. Otherwise, her wound healed well, and no new swellings were observed during her follow-up 3 months later.**

## 3. DISCUSSION

Osteosarcomas are defined as intramedullary high grade osteoid producing sarcomas and long bones such as tibia and femur are usually the common sites for osteosarcoma (1). Osteosarcomas of jaw are often rare and consist only 1% of all head and neck malignancies cases. Osteosarcomas are more common in male population and happens during patient's thirties to forties (2-6). However, this patient presented with cheek swelling at old age of sixties. It has higher mortality in view of its locally advanced disease as compare to osteosarcoma over the extremities which affect more on younger populations (7). Mandible

has slightly more common site for osteosarcoma as compare to maxilla (4) and similar in this case.

Predisposes factors for osteosarcoma are Paget disease, fibrous dysplasia and ionizing radiation (3, 4). However, in this case, the patient didn't have any predispose factors as mentioned above. The most common complaint for patient with osteosarcoma of jaw is oral swelling (3). On the contrary, patient initial presentation is cheek swelling instead of oral swelling. Other manifestations include oral ulcer, pain, lip numbness, loosening of tooth, and/or separation of the teeth (3, 5). This patient didn't present the typical presentation of osteosarcoma of jaw.

CT and MRI are commonly used in diagnosing osteosarcoma by identifying the morphological alterations of tumor, assessing the extent of the tumor and its invasion toward adjacent structure (3, 5). Osteosarcoma can present with Garrington sign and Sunburst appearance radiologically. Garrington sign is widening of periodontal space around affected teeth while sunburst appearance is due to radiating mineralized tumor spiculae in tumor (2-4). Sunburst appearance was seen in this case.

It is always challenging for pathologist to differentiate chondroblastic osteosarcoma from chondrosarcoma (3, 6). However, the presence of osteoid matrix formation in the tumor able to rule out chondrosarcoma (2, 8). The tumor site for chondrosarcoma rarely appears in the jaw bone, although chondrosarcoma has a better prognosis as compare to osteosarcoma (8).

The prognosis of osteosarcoma in the adult population depends on several independent factors, such as age, primary site, tumor size, grade, AJCC stage, and surgery (9). The only factor that points toward a good prognosis in this patient is early surgery to completely remove the tumor.

According to the Enneking system (Musculoskeletal Tumor Society staging), this patient is classified as Stage III osteosarcoma. The osteosarcoma is high-grade, as indicated by the histopathological examination, and it has involved the extracompartmental region and metastasized to the lungs at the time of diagnosis. According to the AJCC staging system, this patient is classified as Stage IVA (10, 11).

The mainstay of treatment is adequate surgical resection and complement with post op radiotherapy (4). Given the complexity of the human skull, including the blood vessels and branches of cranial nerves, performing a complete surgical resection with tumor-free margins poses a challenge for the surgeon. On the other hand, neoadjuvant chemotherapy aid in shrink the tumor size and facilitate the surgery later (2, 4). In this case, neoadjuvant chemotherapy was not effective for her as the tumor remain the same the size despite already given 2 cycle of chemotherapy and she had to default due to unable to tolerate the side effect of chemotherapy.

Amplifications of MDM2 and VEGFA, as well as deletions or loss of heterozygosity in TP53, RB1, CDKN2A/B, CDKN2AP14ARF, and CDKN2AP16INK4A, have been reported in osteosarcoma (12). Genetic testing may provide valuable insights into prognosis, potential therapeutic targets, and treatment response. Genetic analysis should be performed for the patient and their next of kin.

#### **4. CONCLUSION**

Besides sinonasal malignancies, lymphomas, or parotid tumors, a mass over the cheek region can be one of the manifestations of osteosarcoma. Adequate surgical resection

remains the most important step in treating osteosarcoma of the jaw. Public awareness of tumor growth and cancer screening is important, as it allows patients to detect tumors early and receive proper treatment before the condition worsens. This will definitely increase patients' chances of survival.

## **Ethical Approval:**

As per international standards or university standards written ethical approval has been collected and preserved by the author(s).

## **Consent**

As per international standards or university standards, patient(s) written consent has been collected and preserved by the author(s).

## **ABBREVIATIONS**

CT: Computer tomography

MRI: Magnetic resonance imaging

## **Disclaimer (Artificial intelligence)**

Author(s) hereby declare that generative AI technologies such as Large Language Models, etc have been used during writing or editing of manuscripts. This explanation will include the name, version, model, and source of the generative AI technology and as well as all input prompts provided to the generative AI technology

Details of the AI usage are given below:

1. OpenAI. (2024). ChatGPT (GPT-4) [Large language model]. OpenAI. <https://www.openai.com/chatgpt>

## **REFERENCES**

1. Bhardwaj, N., Bachhal, V., & Saikia, U. N. (2024). Chondroblastic osteosarcoma. *Autopsy & Case Reports*, 13, e2023466. <https://doi.org/10.4322/acr.2023.466>
2. Oliveira, L., Cunha, J. L., Bezerra, B., Melo, M., da Fonte, J., & Jr, R. (2018). Chondroblastic osteosarcoma of the mandible: Case report. *Jornal Brasileiro de Patologia e Medicina Laboratorial*, 54. <https://doi.org/10.5935/1676-2444.20180021>
3. Hasen, Y. M., Tawel, H., Alreeshi, K. M., Khalifa, O., & Furjani, J. M. (2024). Mandibular chondroblastic osteosarcoma: A case report. *Cureus*, 16(2), e53713. <https://doi.org/10.7759/cureus.53713>
4. Mamachan, P., Dang, V., Bharadwaj, N. S., DeSilva, N., & Kant, P. (2019). Chondroblastic osteosarcoma: A case report and review of literature. *Clinical Case Reports*, 8(11), 2097–2102. <https://doi.org/10.1002/ccr3.1761>

5. Mirmohammad, S. H., Karimi, A., Derakhshan, S., Aminishakib, P., & Parchami, K. (2021). Conventional osteosarcoma of the mandible: Report of a rare case. *Clinical Case Reports*, 9(9), e04843. <https://doi.org/10.1002/ccr3.4843>
6. Boussouni, S., & Touré, G. (2021). Chondroblastic osteosarcoma of the mandible in a patient on risedronate: A rare case of neoadjuvant chemotherapy failure. *Cureus*, 13(11), e19929. <https://doi.org/10.7759/cureus.19929>
7. Ahmad, I., Bhatt, C. P., Bashir, I., & Rathour, S. (2018). High-grade osteosarcoma of the mandible: A rare tumor successfully treated with surgery and image-guided volumetric modulated arc therapy. *BMJ Case Reports*, 2018, bcr2018226516. <https://doi.org/10.1136/bcr-2018-226516>
8. Bajpai, M., & Pardhe, N. (2018). Chondroblastic osteosarcoma: The wolf in sheep's clothing. *Cukurova Medical Journal*, 43(3), 761–762. <https://doi.org/10.17826/cumj.397502>
9. Deng, G., & Chen, P. (2023). Characteristics and prognostic factors of adult patients with osteosarcoma from the SEER database. *Medicine*, 102(37), e33653. <https://doi.org/10.1097/MD.00000000000033653>
10. American Cancer Society. (n.d.). Staging osteosarcoma. *American Cancer Society*. <https://www.cancer.org/cancer/types/osteosarcoma/detection-diagnosis-staging/staging.html#:~:text=Musculoskeletal%20Tumor%20Society%20%28MSTS%29%20staging%20system%20A%20system,based%20on%20how%20it%20looks%20under%20the%20microscope>
11. Gorlick, R. (2010, October). Osteosarcoma: A review of diagnosis, management, and treatment strategies. *Hematology/Oncology Clinics of North America*. <https://www.hematologyandoncology.net/archives/october-2010/osteosarcoma-a-review-of-diagnosis-management-and-treatment-strategies/>
12. Suehara, Y., Alex, D., Bowman, A. S., Middha, S., Zehir, A., Chakravarty, D., ... Ladanyi, M. (2019). Clinical genomic sequencing of pediatric and adult osteosarcoma reveals distinct molecular subsets with potentially targetable alterations. *Clinical Cancer Research*, 25(3), 1168–1178. <https://doi.org/10.1158/1078-0432.CCR-18-4032>

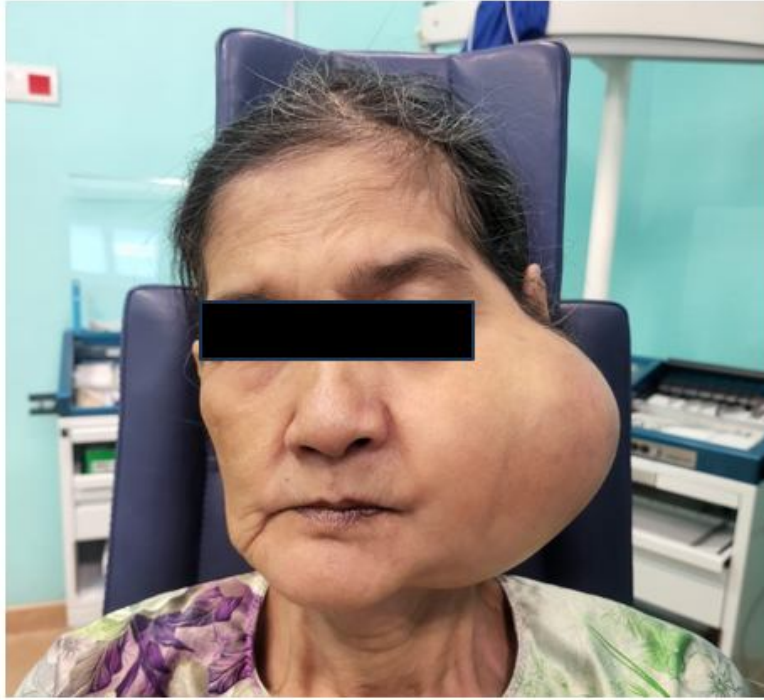

Figure 1: Patient's left cheek swelling with dilated vessels seen.

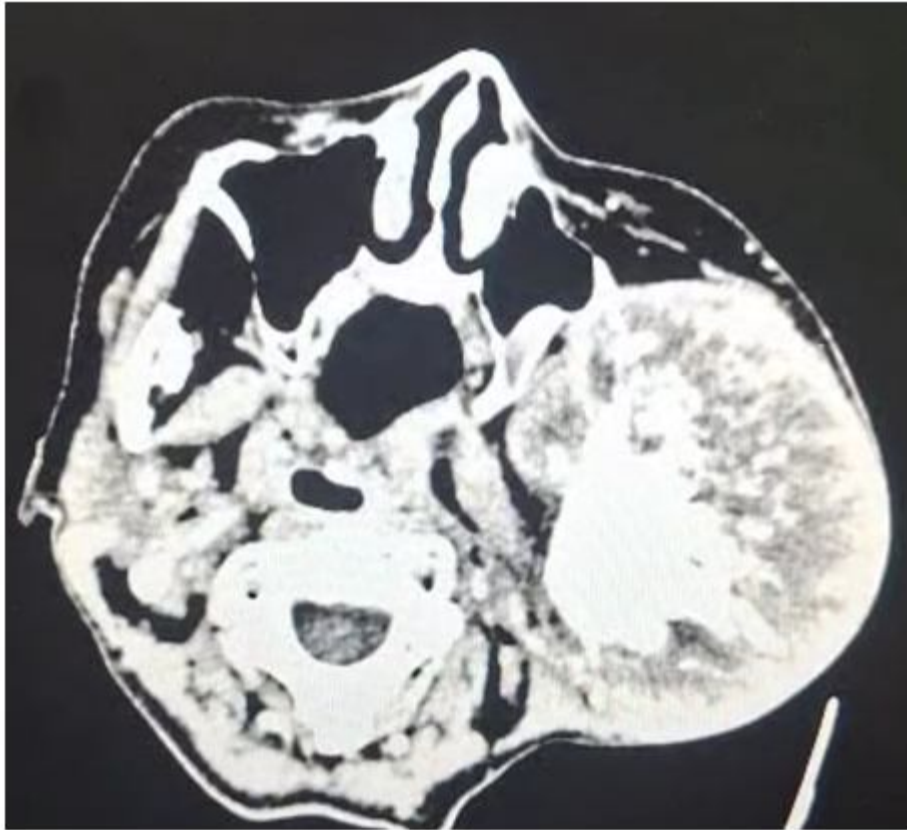


Figure 2: Computer tomography showed Sun burst appearance involving the ramus and extending to the angle of left mandible.



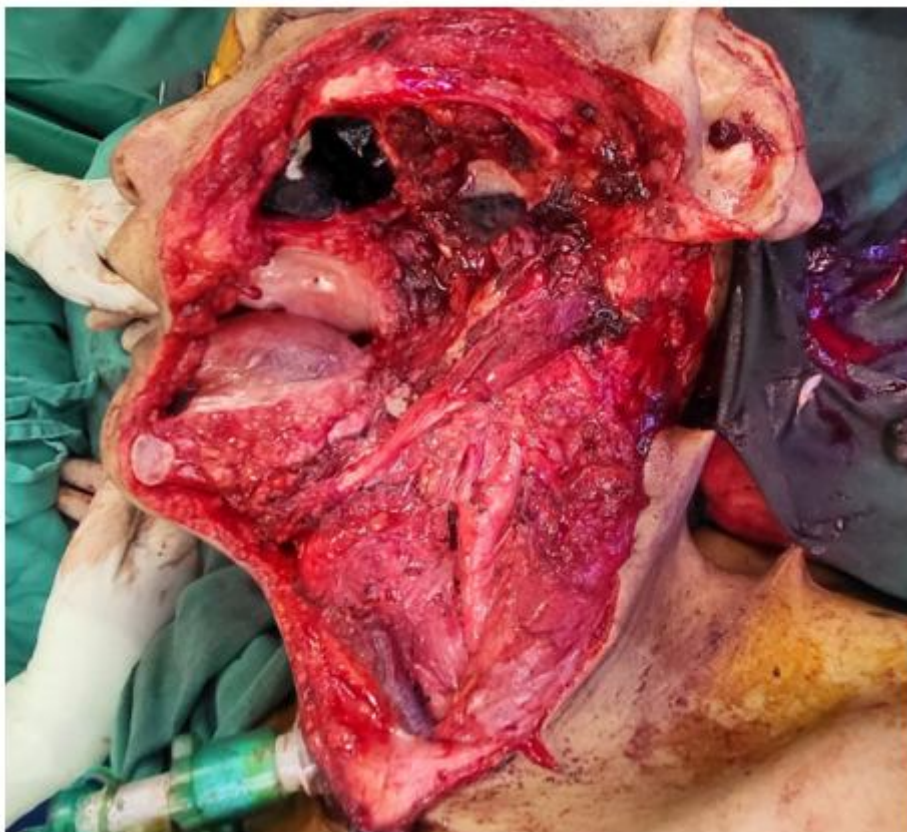

Figure 3: The patient underwent open tracheostomy, left temporary tarsorrhaphy, wide local excision of the tumor, left hemimandibulectomy, left partial maxillectomy, and anterolateral thigh free flap reconstruction.



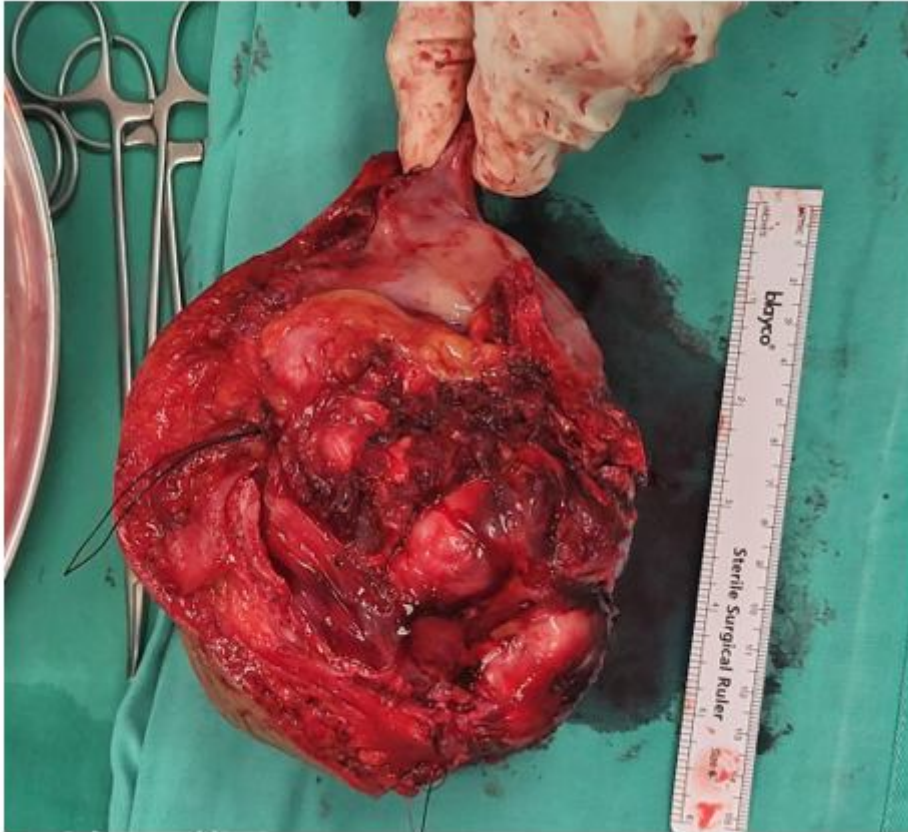
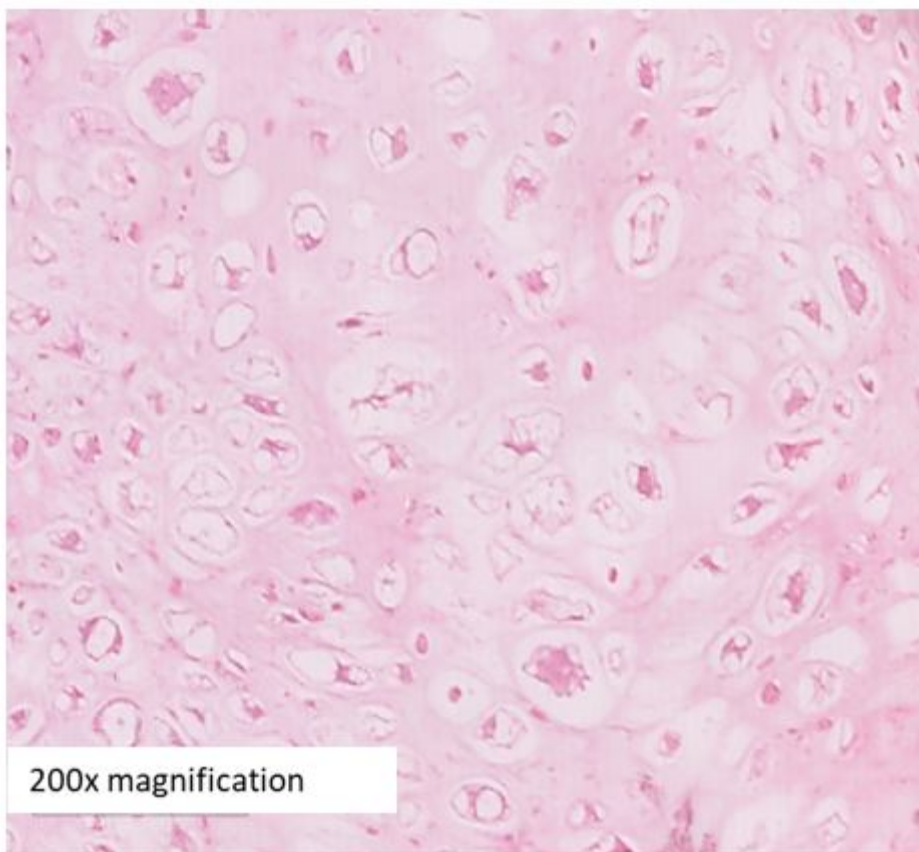


Figure 4: Large hard mass over left mandible with histopathology examination resulted as chondroblastic osteosarcoma.



UNDER PEER REVIEW

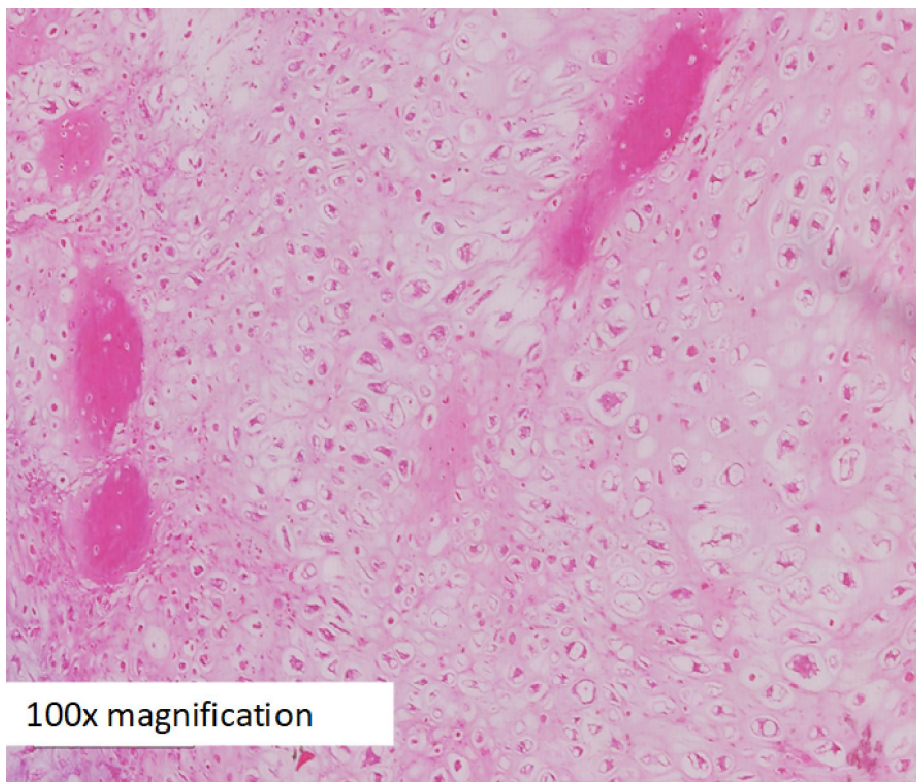


Figure 5(A-B): HPE showed pleomorphic and bizarre tumor cells with osteoid formation in background (hematoxylin and eosin stain). Additionally, a chondroid matrix was identified in focal areas.