

Cystoid macular edema in retinitis pigmentosa patients and its medical management: A case report

Abstract

Retinitis Pigmentosa (RP) take in a group of hereditary retinopathies that lead to progressive vision loss ; RP may be complicated by cystoid macular oedema (CMO). A 40-year-old female presented with fluctuant blurred vision for 4 years. Best corrected Visual acuity (BCVA) was 20/20 in both eyes. Examination and imaging showed besides bone spicule pigmentation a macular edema . Currently the patient is under medical treatment. Successful management of RP-CMO should allow to improve quality and quantity of vision in the short term and also slow the progression of central vision loss on the long term. This report describes a case of using carbonic anhydrase inhibitor CAI per os medication to manage CMO secondary to RP in a long term .

Keywords : retinitis pigmentosa , macular edema , carbonic anhydrase inhibitor , case report

Introduction

"Retinitis pigmentosa (RP) is a group of disorders which the main feature is a gradual loss of vision . Males are affected slightly more often than females. The average age of symptom onset is dependent on the genetic type, the first symptom of RP is generally nyctalopia. Hyperpigmentation in a bone spicule pattern in the mid-peripheral retina is the most important fundus sign. Other signs include Narrowing of the retinal arterioles , Cystoid macular edema, Waxy yellow appearance of the papilla, Posterior subcapsular cataract, Cells in the vitreous body (less frequent) and Myopia" (1) (2). "In addition, there are some uncommon ocular comorbidities in RP patients, such as central retinal vein occlusion (CRVO) and Coats-like exudative vitreoretinopathy". (3) "One important treatable cause of central vision loss is RP-associated CMO. (RP-CMO)" (4)

Case Presentation

A 40-year-old woman followed up for RP presented to our structure for blurred vision with no family history of retinitis pigmentosa. the patient reported no notable ophthalmological history, in particular the absence of any notion of trauma or inflammation. As far as her family is concerned, there are no similar affections in the family, and no notion of consanguineous marriage between the parents.

It should be noted that the patient is a carrier of the PRPH2 mutation revealed by genetic testing 4 years ago, in the context of rod cone dystrophy. Moreover, the patient is not a

carrier of a systemic pathology; this is a non-syndromic form of RP. The patient is paucisymptomatic, and her main functional complaint is night blindness. This dystrophy is complicated by cystoid macular edema, which causes visual discomfort experienced by the patient as moderate blurring; this is what initially prompted the consultation and led to the diagnosis. The particularity of our case lies in the fact that the patient has been reporting an exacerbation of the symptomatology and an accentuation of the visual blur during menstruation for several years.

On general examination, the patient was in good health, and her visual acuity was generally preserved at 20/20 in the right and left eyes. Intraocular pressure was normal in both eyes.

Slit lamp examination showed a normal anterior segment with no cataract. Fundus examination revealed a slight hyperpigmentation in a bony spicule pattern in the mid-peripheral retina, there was no narrowing of the retinal arterioles, cystoid macular edema, and no waxy yellow appearance of the papilla. (Figure 1).

FAF of the right eye shows patches of hypofluorescence, initially localized in the periphery, contrasting with a hyperfluorescent ring in the macular region. [Figure 2]. OCT of the right eye showed cystoid macular edema. The left macula was abnormal with slight intraretinal fluid [Figure 3]. "Several therapeutic methods have been introduced since the diagnosis. Initially, central macular thickness (CMT) was 550 μm in the right eye and 431 μm in the left eye. Both eyes were treated with several intravitreal injections of anti-VEGF medication. Few months later, BCVA increased, CMT decreased in both eyes and intraretinal fluid decreased significantly. However, 6 months after injection, these improvements of both eyes were not maintained". [20] The evolution was fluctuant. The patient is currently stable on carbonic anhydrase inhibitor CAI per os, half a tablet 2 times a day; with a satisfying BCVA (20/20) and CMT. A follow-up visits are established every 3 months with a systematic OCT scan and a monitoring of potassium and sodium bicarbonate levels, in particular.

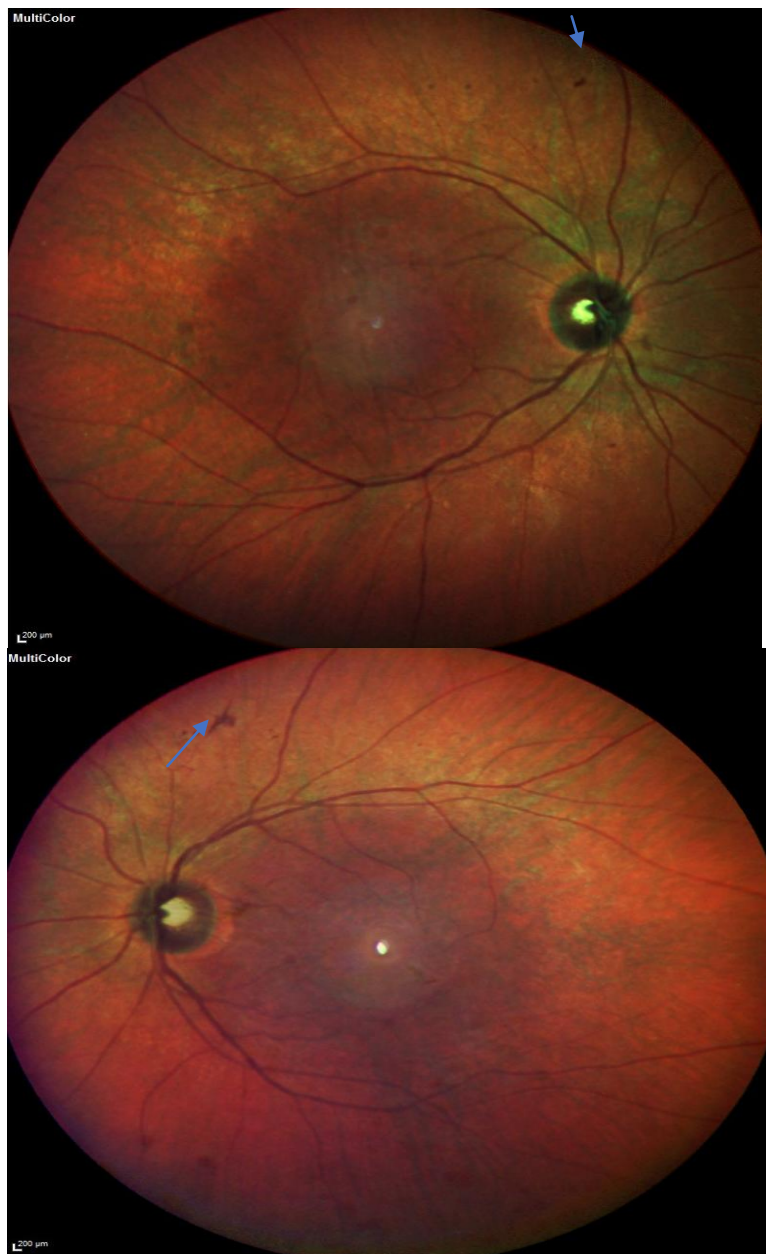

Figure 1 : Color fundus photographs of right then left eyes showing slight hyperpigmentation in a bony spicule pattern in the mid-peripheral retina

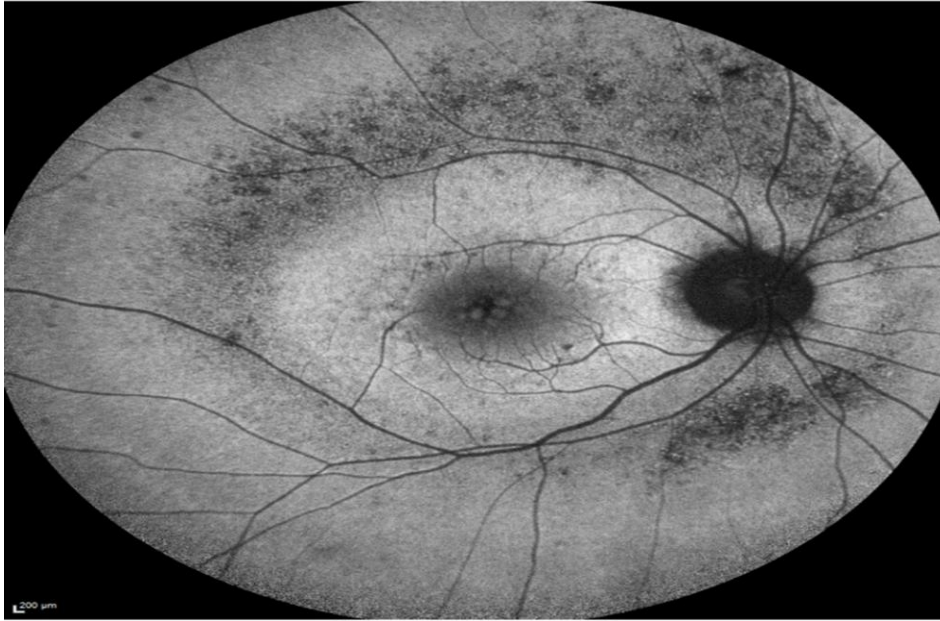

Figure 2 : Fundus autofluorescence (FAF) imaging showing patches of hypofluorescence, initially localized in the periphery, contrasting with a hyperfluorescent ring in the macular region

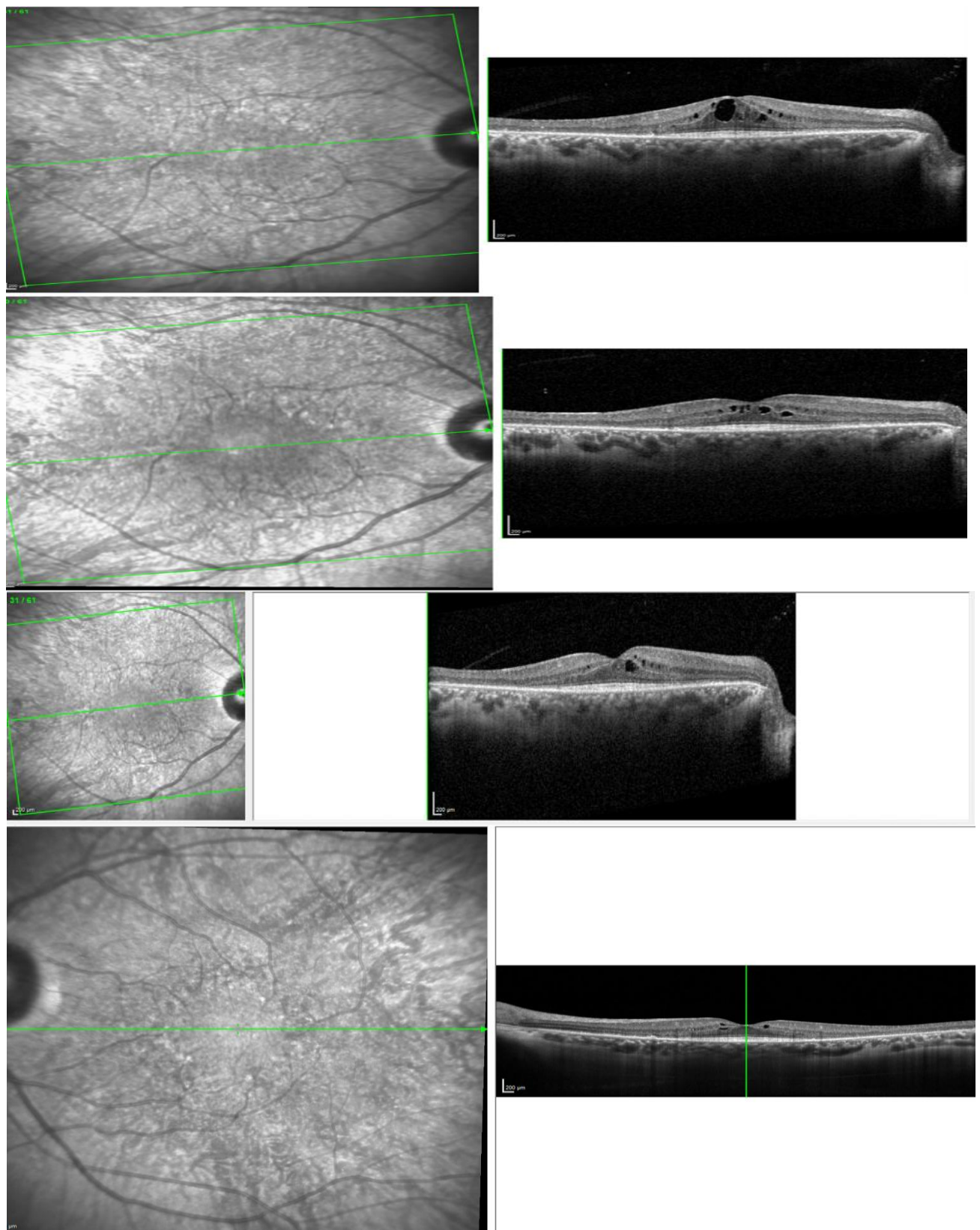


Figure 3 : spectral domain optical coherence tomography scans of the right eye showing cystoid macular edema in different stages of the follow up . The left macula appeared with slight intraretinal fluid

Discussion

Retinitis pigmentosa RP is also known as hereditary retinal dystrophy, it is the most common inherited disease of the retina. usually bilateral,. RP may present and progress with a variety of clinical manifestations, , mainly loss of night vision, which is followed by a gradual narrowing of the visual fields. Over time, depending on the severity and rate of progression of the disease, tunnel vision or complete vision loss can be the result.

The "non-syndromic" RP , which represents around 70% to 80% cases, involves vision loss only,. When RP occurs in conjunction with a systemic disease, it is called "syndromic" RP. "The syndromic RP involves some systemic symptoms associated to vision loss .The most common form is Usher syndrome, which associates sensorineural hearing loss to vision loss". (5)

"There are several Genetic mutations responsible for retinitis pigmentosa , they affect specifically rod photoreceptors in the retina.and leads to their destruction".(6) "Rods are responsible for low-light vision, their progressive destruction is responsible for night blindness or hemeralopia and a gradual diminution of peripheral vision. Eventually, the destruction of large numbers of rods has a noxious effect on the retinal pigment epithelium (RPE) and cone photoreceptors"(7).

Several responsible genes have been identified. Transmission may be autosomal dominant, recessive or, more rarely, X-linked. The genetic heterogeneity of typical non-syndromic rod-predominant RP is significant: 11 genes and one locus have been identified for dominant forms, 17 genes and 5 loci for recessive forms, 2 genes and 2 loci for X-linked forms. A bibliographic survey of large series indicates that the frequency of mutations found for all currently known genes varies from 40 to 54% of cases in autosomal dominant forms, 17 to 24% in recessive and 61 to 89% of cases in X-linked forms. Very few studies exist for sporadic cases. Overall, the 2 most frequently implicated genes are RPGR and RHO,they represent the 2 genes of choice for systematic diagnosis.

The classical triad of retinitis pigmentosa are Hyperpigmentation in a bony spicule pattern typically in the mid-peripheral retina, Narrowing of the retinal arterioles and Waxy yellow appearance of the papilla (8).

Macular edema (ME) can occur in any patient with retinitis pigmentosa, and at any stage.. However, it is unclear why some patients develop ME, and others do not. (9) Cystoid macular oedema (CMO) has been reported to occur in 10%–50% of patients.(10)RP-CMO is not always associated with a reduction in visual acuity (VA) ; some studies found no correlation between total macular thickness and VA.

"There are no standard treatments for RP. It is not possible to cure retinitis pigmentosa lesions, but vitamin A palmitate 15,000 IU orally once a day can slow disease progression in some patients. Patients taking vitamin A palmitate should undergo regular liver checks. Some studies have shown that it slows the progression of the disease ; but this still controverted".(11)(12)

"Gene therapy is an innovative strategy of particular interest in RP. It aims to restore the deficient molecular function by transferring a therapeutic gene into the target cells.. Other research involves cell replacement therapy, aiming to repopulate the retina with functional photoreceptors".(13)

Multiple devices have the potential to partially restore sight and thus improve patients' autonomy and mobility, although evidence of its long-term effects is not available. Studies have shown that patients who have received the implant have improved their performance in motion detection, letter recognition and color perception. (14) (15)

Multiple therapeutic options have been investigated for the treatment of OM in retinopathy pigmentosa. Several studies have shown RP-CMO improvement following treatment with CA inhibitors (CAIs) oral, or topical. (16) CAIs are considered part of the diuretic class of medications, (17), Target action on membrane ACs in the retinal pigment epithelium. Studies have clearly demonstrated improvement after treatment with topical dorzolamide 2% (3 instillations per day): reduction in retinal thickness on OCT and diffusion on fluorescein angiography. However, some studies reported no improvement in visual acuity. The dose ranges are different adjusted to the indication and the route of drug administration. The oral route, at a dose of 500 mg/d, is even more effective, with better anatomical and functional results. However, it requires fairly regular clinical and biological monitoring to detect treatment-related side-effects (tingling, hypokalemia, severe allergic reaction, renal lithiasis, etc.). Some patients experience a certain rebound of edema after discontinuation of treatment. In such cases, it is advisable to reintroduce treatment over a longer period of time, on a tapering basis.

Oral, periocular and intravitreal Steroids reduce the synthesis and release of pro-inflammatory cytokines, together with suppression of inflammatory cell proliferation and migration which contributes to reduction of CMO. Steroids have been observed to improve visual acuity VA and/or central macular thickness CMT in RP-CMO

"While no studies have assessed vitreous levels of VEGF in patients with RP or RP-CMO, anatomical and/or functional improvement of RP-CMO has been observed following intravitreal anti-VEGF medication" (18)(19)

Dietary supplementation with an omega-3 fatty acid (e.g. docosahexaenoic acid) and an oral preparation of lutein plus zeaxanthin can also slow the rate of vision loss; however no significant effect on CMT have been noticed.

"a pilot study of grid laser photocoagulation was performed in 16 patients with RP-CME. Six of the treated eyes showed a positive response, while none of the fellow untreated eyes did. Seven of the untreated eyes lost one or more lines of vision, while none of the treated eyes did". (18)

Conclusion

OM complicating pigmentary retinopathies is a major cause of central vision impairment in patients with a more or less narrowed visual field. Screening, diagnosis and management are essential in the comprehensive follow-up of patients with retinal dystrophy and in the preventing of the central visual loss. Topical and/or oral CAI remain the first-line treatment.

Consent

As per international standards or university standards, patient(s) written consent has been collected and preserved by the author(s).

Referencens

1. Chatterjee S, Agrawal D, Agrawal D, Parchand SM, Sahu A. Cataract surgery in retinitis pigmentosa. *Indian J Ophthalmol.* (2021) 69:1753–7.
2. Liew G, Strong S, Bradley P, Severn P, Moore AT, Webster AR, et al. Prevalence of cystoid macular oedema, epiretinal membrane and cataract in retinitis pigmentosa. *Br J Ophthalmol.* (2019) 103:1163–6.
3. Moinuddin O, Sathrasala S, Jayasundera KT, Branham KH, Chang EY, Qian CX, et al. Coats-like exudative vitreoretinopathy in retinitis pigmentosa: ocular manifestations and treatment outcomes. *Ophthalmol Retina.* (2021) 5:86–96
4. Verbakel SK, van Huet RAC, Boon CJF, den Hollander AI, Collin RWJ, Klaver CCW, Hoyng CB, Roepman R, Klevering BJ. Non-syndromic retinitis pigmentosa. *Prog Retin Eye Res.* 2018 Sep;66:157-186.
5. Wolfrum U, Nagel-Wolfrum K. [The Usher Syndrome, a Human Ciliopathy]. *Klin Monbl Augenheilkd.* 2018 Mar;235(3):273-280.
6. Yang YJ, Peng J, Ying D, Peng QH. A Brief Review on the Pathological Role of Decreased Blood Flow Affected in Retinitis Pigmentosa. *J Ophthalmol.* 2018;2018:3249064.
7. Xu H, Chen M, Forrester JV. Para-inflammation in the aging retina. *Prog Retin Eye Res.* 2009 Sep;28(5):348-68.
8. Shintani K, Shechtman DL, Gurwood AS. Review and update: current treatment trends for patients with retinitis pigmentosa. *Optometry.* 2009 Jul;80(7):384-401.
9. Arias, J.D., Kalaw, F.G.P., Alex, V. et al. Investigating the associations of macular edema in retinitis pigmentosa. *Sci Rep* 13, 14187 (2023)
10. S Strong, G Liew, and M Michaelides Retinitis pigmentosa-associated cystoid macular oedema: pathogenesis and avenues of intervention *Br J Ophthalmol.* 2017 Jan; 101(1): 31–37
11. Rayapudi S, Schwartz SG, Wang X, Chavis P. Vitamin A and fish oils for retinitis pigmentosa. *Cochrane Database Syst Rev.* 2013 Dec 19;2013(12):CD008428.
12. Schwartz SG, Wang X, Chavis P, Kuriyan AE, Abariga SA. Vitamin A and fish oils for preventing the progression of retinitis pigmentosa. *Cochrane Database Syst Rev.* 2020 Jun 18;6(6):CD008428.
13. Fahim A. Retinitis pigmentosa: recent advances and future directions in diagnosis and management. *Curr Opin Pediatr.* (2018) 30:725–33.
14. Ward J, Meijer P. Visual experiences in the blind induced by an auditory sensory substitution device. *Conscious Cogn.* 2010 Mar;19(1):492-500.
15. Anil K, Garip G. Coping strategies, vision-related quality of life, and emotional health in managing retinitis pigmentosa: a survey study. *BMC Ophthalmol.* 2018 Jan 30;18(1):21.

16. Pacella E, Arrico L, Santamaria V, et al.. Dorzolamide chlorhydrate versus acetazolamide in the management of chronic macular edema in patients with retinitis pigmentosa: description of three case reports. *Ophthalmol Eye Dis.* 2014;6:21–6.
17. Wang AL, Knight DK, Vu TT, Mehta MC. Retinitis pigmentosa: review of current treatment. *Int Ophthalmol Clin.* (2019) 59:263–80.
18. Ahn SJ, Kim KE, Woo SJ, et al.. The effect of an intravitreal dexamethasone implant for cystoid macular edema in retinitis pigmentosa: a case report and literature review. *Ophthalmic Surg Lasers Imaging Retina* 2014;45:160–4.
19. Schaal Y, Hondur AM, Tezel TH. Subtenon triamcinolone for cystoid macular edema due to retinitis pigmentosa unresponsive to oral acetazolamide. *Can J Ophthalmol* 2016;51:e113–5.
20. Mnejja M, Hammami B, Bougacha L, Chakroun A, Charfeddine I, Khabir A, Boudaoura T, Ghorbel A. Occult lymph node metastasis in laryngeal squamous cell carcinoma: therapeutic and prognostic impact. *European annals of otorhinolaryngology, head and neck diseases.* 2010 Nov 1;127(5):173-6.