

## HEMOBILIA : A RARE CASE OF UPPER GASTROINTESTINAL BLEED

### Abstract

Hemobilia is a rare but important cause of upper gastrointestinal haemorrhage that refers to bleeding from and/or into the biliary tract. The common visceral aneurysm with the highest reported rate of rupture is Hepatic Artery Aneurysm (HAA). Depending on the size of the aneurysm, clinical manifestations include epigastric pain, biliary tract obstruction, gastrointestinal (GI) bleed, aneurysm rupture and death. HAA is a rare disease with an incidence of 0.002%–0.4% of which 50 % is hepatic pseudo aneurysm. In this case report, we discussed a case of 55 years female with complaints of abdominal pain for 15 days, yellowish discolouration of skin and sclera for 15 days and multiple episodes of hematemesis with Malena for 2 days.

**Keywords:** Haemobilia, Upper G.I bleeding, Pseudoaneurysm, Endovascular coiling

### Introduction

Hemobilia is bleeding into the biliary tree. It is a rare cause of upper GI bleed. Most of the Hemobilia cases are iatrogenic and caused by invasive procedures involving liver, pancreas, bile duct, hepatopancreaticobiliary vasculature<sup>[1]</sup>. Non iatrogenic causes of hemobilia include gallbladder and bile duct stones, biliary varices, biliary parasite infestation like *Ascaris lumbricoides*, benign and malignant tumors of biliary tree, liver surgery (including transplantation), congenital or acquired vascular aneurysms, pancreatitis, and hepatitis (drug-induced or autoimmune).

### Case presentation

Here I am reporting an interesting case of 55 years old female patient presented to emergency department with complaints of abdominal pain for 15 days, which was acute in onset and intermittent in nature. She also complains of jaundice for 15 days and had multiple episodes of hematemesis in last 2 days leading to anaemia, tachycardia, hypotension, significant drop in haemoglobin (Hb). Previously patient underwent Cholecystectomy for calculus cholecystitis, followed by ERCP stenting on 12<sup>th</sup> post operative day for common hepatic duct stricture (benign biliary stricture) with cholangitis & obstructive jaundice. On physical examination, Patient was conscious, oriented, irritable & had pulse 123/Min, BP was 80/60 mm of Hg & respiratory rate was 24 breaths/Min. Patient had severe pallor and jaundice. Laboratory investigations revealed Hb of 6.2 gm/dl, alkaline phosphatase 412 IU/L with total bilirubin 17.4 mg/dl. Patient resuscitated with 3 Packed cell volume and 4 fresh frozen plasma transfusion. Triple phase CT abdominal angiography showed rupture of common hepatic artery pseudo aneurysm with dilated hepatic and common bile duct with haemobilia and obstructive jaundice as its sequelae. Patient was managed successfully with common hepatic artery pseudo aneurysm angioembolisation with multiple platinum micro-coils by interventional radiologist. The haematemesis and Malena was controlled and patient became vitally stable.

### Discussion

The first case report of haemobilia was from Francis Glisson in 1654<sup>[2]</sup>. Antonie Portal was the first person to publish a case of haemobilia identified antemortem.

Most common cause of haemobilia is iatrogenic trauma during surgical intervention procedure like laproscopic or open Cholecystectomy or rarely ERCP or in traumatic injuries. Rupture of common hepatic artery Pseudo aneurysm is also reported as a source of bleeding [3 4 5]. Hemobilia presents like melena, or substantial upper gastrointestinal bleeding [6 7], which causes hemodynamic instability in the patient. A patient with haemobilia may have acute biliary pain due to bile duct distension and obstruction. Primary resuscitation of patient to be done with intravenous fluids, blood transfusion, fresh frozen plasma (FFP) transfusion and inotropic support. There are mainly two definitive therapeutic options for this emergency clinical scenario. Such emergencies can be managed by surgical gastroenterology with ligation of bleeding vessel or interventional radiology with endovascular angioembolisation. The present case was resuscitated successfully and after haemodynamic stability, patient was subjected for endovascular angioembolization which Post operative course was uneventful and patient was discharged on 4<sup>th</sup> postoperative day and under follow up for 3 months.

## Conclusion

The haemobilia is very rare cause of G.I bleeding. Such rare cause should be suspected when there is history of any surgical intervention or trauma to liver or biliary system. With the new advent of G.I surgery and interventional radiology, Such cases are diagnosed in the time and treated successfully with the help of interventional radiology procedures like endovascular coiling or plugging.[8 9 10]

## Ethical Approval:

As per international standards or university standards written ethical approval has been collected and preserved by the author(s).

## Consent

As per international standards or university standards, patient(s) written consent has been collected and preserved by the author(s).

## Reference

1. Berry R, Han JY, Kardashian AA, LaRusso NF, Tabibian JH. Liver Res. 2018 Dec;2(4):200-208. doi: 10.1016/j.livres.2018.09.007. Epub 2018 Sep 22. PMID: 31308984
2. Bates D. English manuscripts of Francis glisson (1): From anatomia hepatis (the anatomy of the liver), 1654. Andrew Cunningham. Isis 1996; 87: 357–358.
3. Arneson MA, Smith RS. Ruptured hepatic artery aneurysm: case report and review of literature. Annals of vascular surgery. 2005;19(4):540–5.
4. Altaca G. Ruptured aneurysm of replaced left hepatic artery as a cause of haemorrhagic shock: a challenge of diagnosis and treatment. Interactive cardiovascular and thoracic surgery. 2011;14(2):220–2
5. Abbas M.A., Fowl R.J., Stone W.M. Hepatic artery aneurysm: factors that predict complications. J. Vasc. Surg. 2003;38(1):41–45. doi: 10.1016/s0741-5214(03)00090-9.
6. Green MH, Duell RM, Johnson CD, Jamieson NV. Haemobilia. Br J Surg 2001; 88: 773–786.
7. Murugesan SD, Sathyanesan J, Lakshmanan A, et al. Massive hemobilia: A diagnostic and therapeutic challenge. World J Surg 2014; 38: 1755–1762.

8. Har B, Sanfui S, Saha D, Chattopadhyay BK. Massive hemobilia in a case of hepatic artery pseudoaneurysm: A rare complication after open cholecystectomy. *Saudi Surg J* 2015;3:53-5
9. Mate, Ajay D; Surnare, Kailas R; Deolekar, Samir S; Gvalani, Anil K. Lower gastrointestinal bleeding due to hepatic artery pseudoaneurysm following laparoscopic cholecystectomy. *Journal of Minimal Access Surgery* 9(1):p 31-33, Jan–Mar 2013. | DOI: 10.4103/0972-9941.107135
10. Niziolek GM, Smith B, Cannon J, *et al* Management of a common hepatic artery pseudoaneurysm after blunt trauma *Trauma Surgery & Acute Care Open* 2022;7:e000909. doi: 10.1136/tsaco-2022-000909

UNDER PEER REVIEW

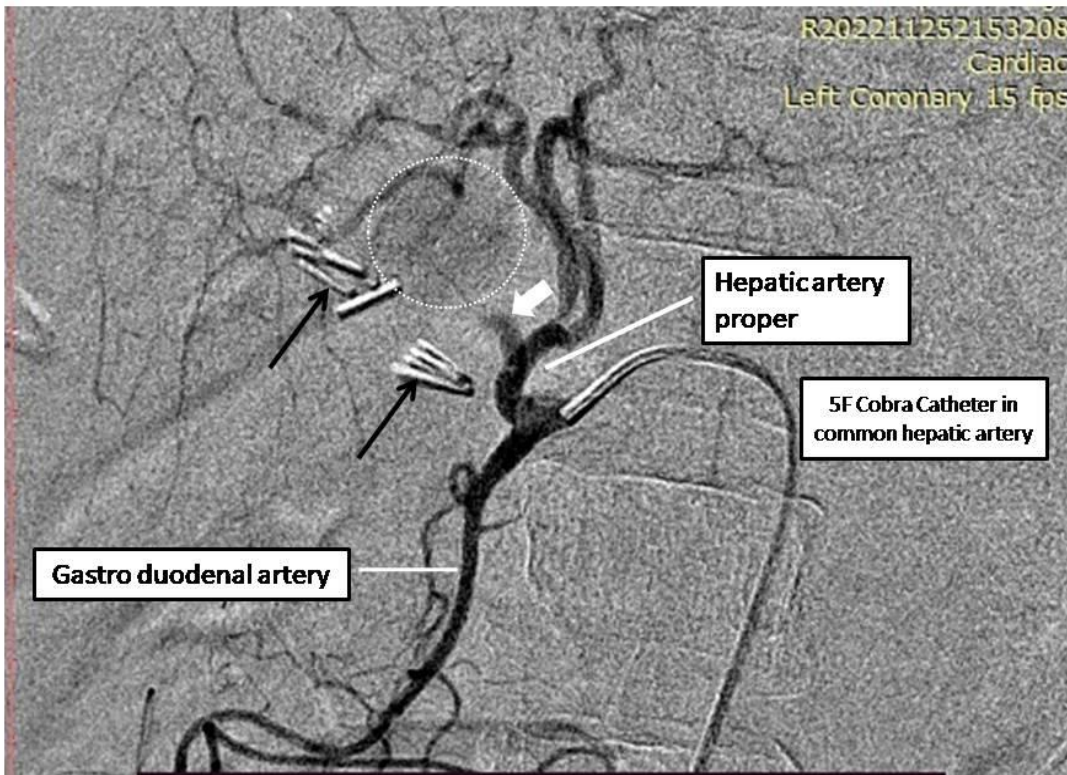
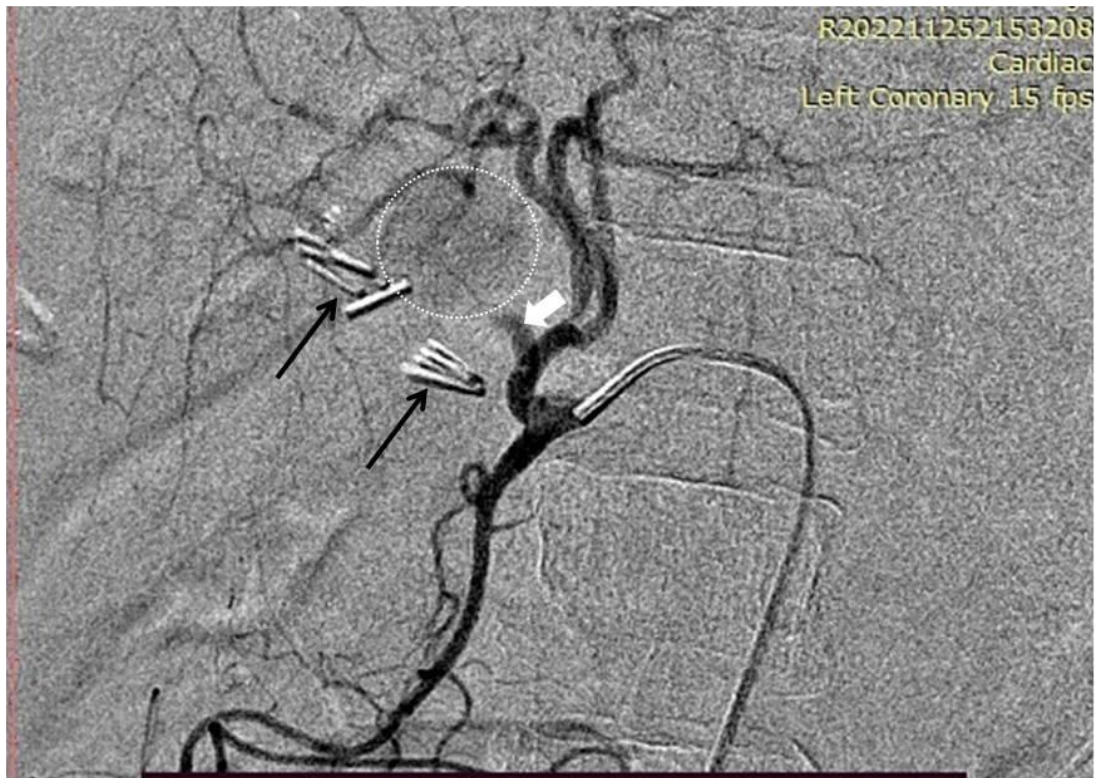

Fig (1)& (2): pseudoaneurysm at common hepatic artery



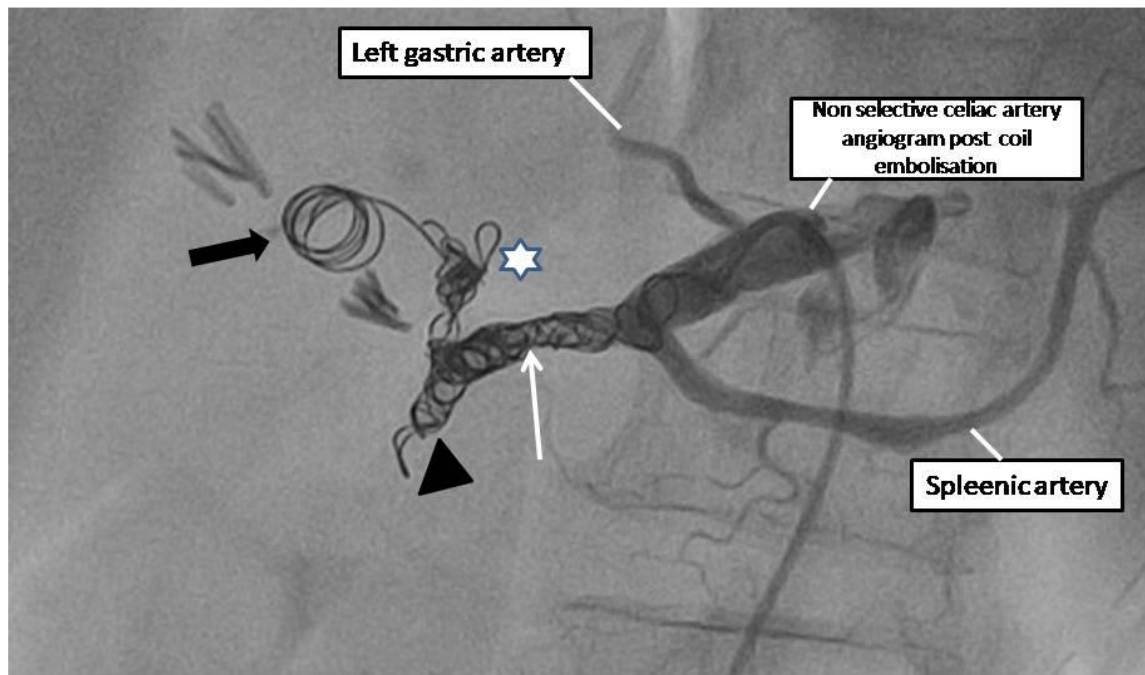


Fig (3) :Embolisationand coiling of common hepatic artery

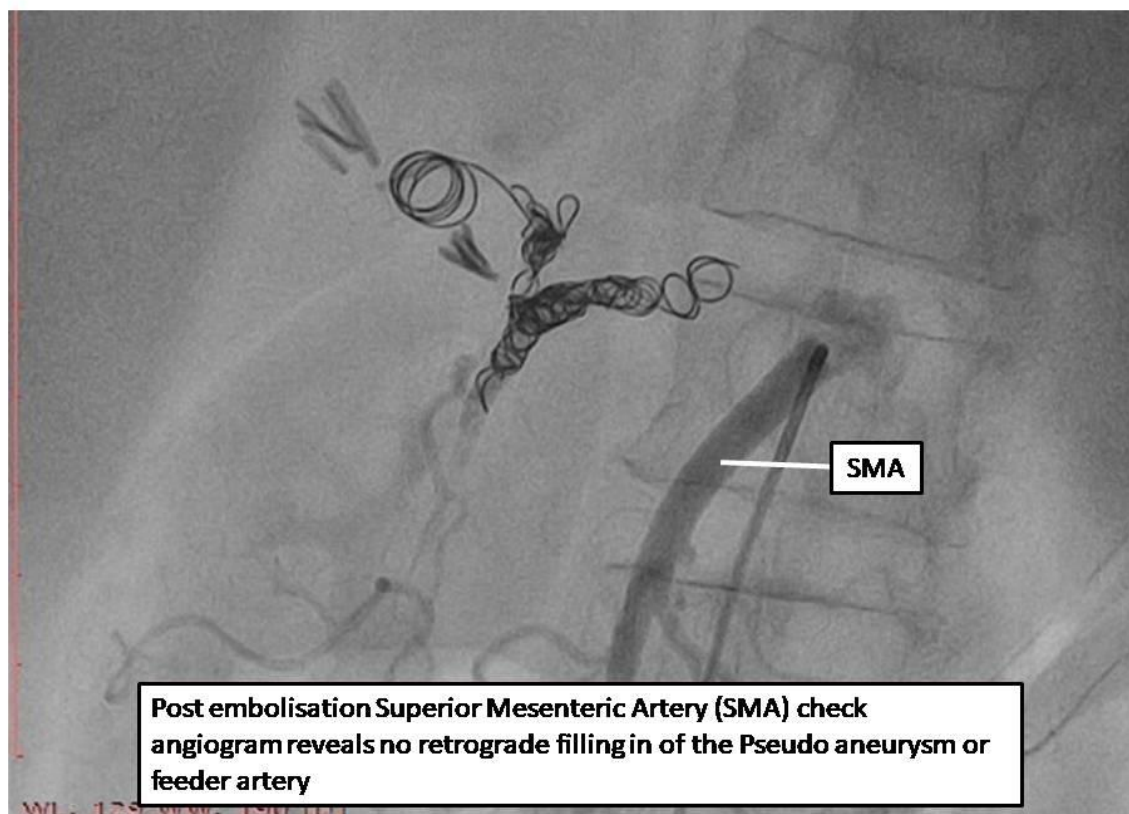


Fig (4) : Post Embolisation Superior mesentric artery check angiogramreveals no retrograde filling in the pseudoaneurysm or feeder artery.

UNDER PEER REVIEW