

# OSSIFYING FIBROMA OF THE MAXILLA: CASE REPORT

## **Abstract :**

Ossifying fibroma (OF) is a rare fibro-osseous lesion that occurs mainly in the cranio-facial bones, found more in the mandible than maxilla. It is characterized by fibrous connective tissue matrix with varying amount of osteoid, mature and immature bone. This benign bone tumor is more common in the second to fourth decades of life, with a high predilection into females.

The OF is divided into conventional and juvenile subtypes. The latter (JOF) is also called aggressive ossifying fibroma due to its aggressiveness and its high tendency to recur, unlike the other fibro-osseous lesions. In this article we report the case of a 5-year-old male child, with a left swelling cheek which turned to be a JOF on histopathology after surgical removal.

**Keywords:** Ossifying fibroma, juvenile, surgical removal, maxilla.

## **Introduction:**

Ossifying fibroma (OF) is a bone tumor found mostly in the jaws bones. Other rare sites were reported as the paranasal sinuses, orbital region, skull base, and temporomandibular joint[1]. "It histologically consists on the substitution of normal bone by fibrous tissues containing varying mineralized substances"[2]. In fact, based on clinical, pathological and histological features, OF subdivided these lesions into two categories, conventional and juvenile types. The first one is a slow growing tumor which occurs mostly in middle aged patients. In opposition to the juvenile subtype affecting an age group of 5 to 15, and tends to mimic malignant tumors.

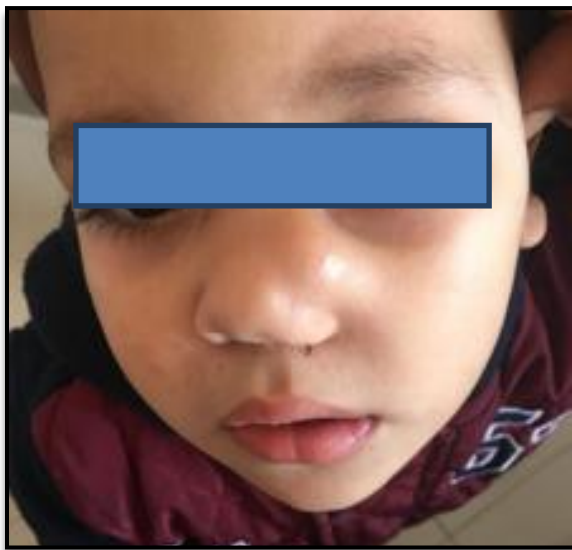"According to the WHO classification 2017, JOF has been recognized as a separate histopathological

entity among the fibro-osseous group of lesions due to its distinct histological characteristics"[3]. "The JOF is known to be highly recurrent, and an aggressive tumor"[4]. Because of its rarity, and its destructive growth, we report the case of a JOF of a 5-year-old patient successfully managed surgically in the ENT department of 20 august hospital in Casablanca, emphasizing its clinical, radiological, and histological features.

## **Case report:**

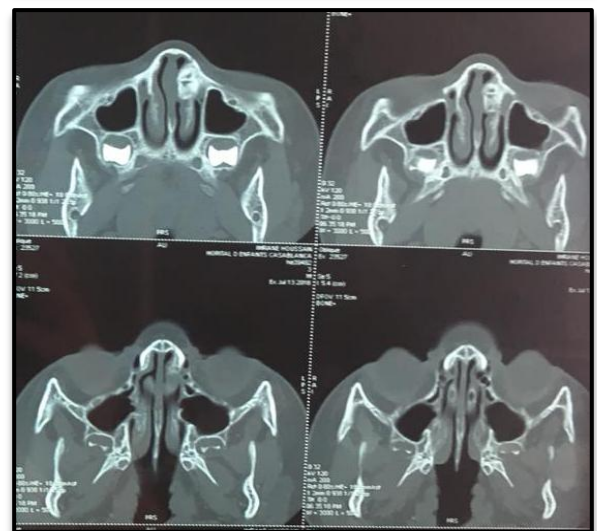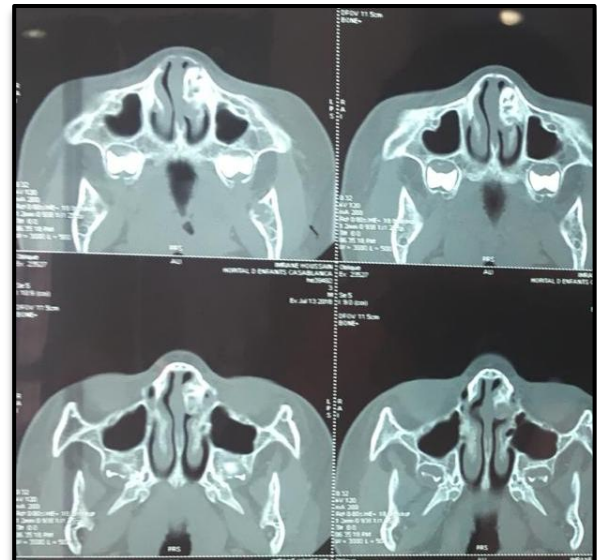A 5 year old child presented to our department complaining of a painless swelling on the left side of the face increasing gradually of size. No incident of trauma was found in the interrogation, neither a significant medical or family history. The swelling appeared spontaneously. Examination found a non tender mass, with a hard consistency

same as the bone which seems to be attached to. The skin overlying the mass appeared normal, intact, with no inflammatory signs or sensitivity disorders. Nasal examination found a normal overlying pituitary mucosa on a bone swelling hindering the examination of the rest of nasal cavity. There was no further complaint. General physical examination was quite normal.



**Figure 1:** Preoperative image of the 5 year old child.

CT scan reveals an osteolytic lesion, well demarcated, and bordered with an osteo-condensing edging, and dotted with fine radio-opacities having a radial disposition on CT. This lesion hangs from the edentulous maxillary ridge, except for a root remnant of 18. However, there was no intraorbital extension. Medially it was causing mass effect on ipsilateral nasal cavity.



**Figure 2:** CT scans images: axial cut.

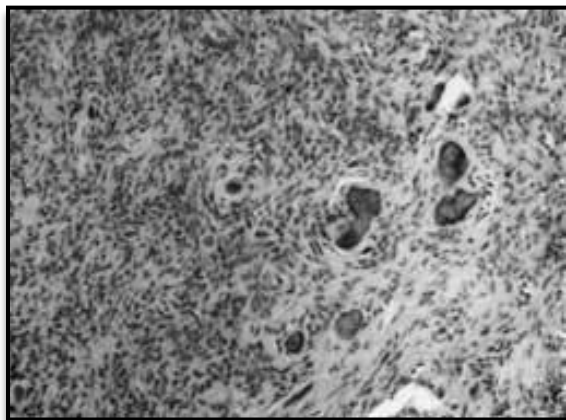
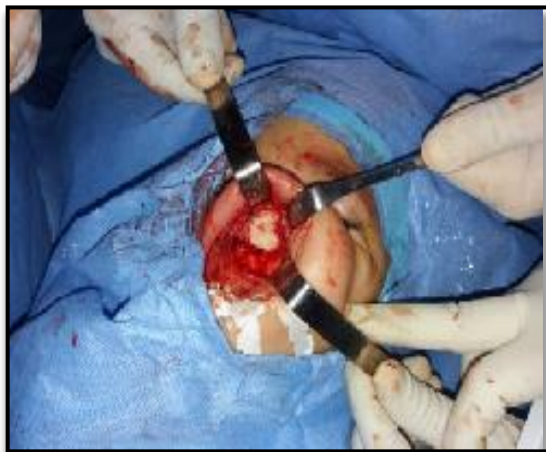The child underwent a surgical removal under general anesthesia.

Under aseptic procedure, the tumor was approached through a trans nasal endoscopic approach. Complete tumor enucleation and excision was done.

The Histological examination confirmed the diagnosis of ossifying fibroma.

The patient showed complete improvement. He was discharged from the hospital after two days, and return to all the follow ups. No signs of recurrence have been observed during the two years of check-up.

**Figure 3: Micro photography of an OF formed by fibroblast cells and calcified deposits.**



**Figure 4: Per operative image**

## **Discussion:**

Ossifying fibroma is a rare tumor entity affecting the jaws and craniofacial bones. They are characterized by the replacement of bone by cellular fibrous

and mineralized tissues that vary in amount and appearance.[14]“Real etiology remains unknown. Genetic, traumatic and developmental theories have been suggested”[5].Differentiation of the multi potential precursor cells of the periodontal ligament to form aberrant tissue is most noteworthy theory.

According to the new edition of the classification of the World Health Organization (WHO), OF is subdivided into two entities: conventional and juvenile types. Conventional subtype is usually slow growing and occurs often in the third to fourth decades of life. Their treatment consists on a simple curettage. Recurrences in this subtype are rare.

Whereas the juvenile subtype, it appears as a fast and aggressive growing lesion affecting predominantly but not exclusively younger patients under 15 years old with a slight male predilection [6]. However, in the literature some studies show no gender predilection[7]. This type tends to be highly recurrent. Owing to its aggressiveness and its high recurrence rate, early detection and complete surgical excision are essential for a good prognosis. Juvenile ossifying fibroma (JOF) usually involves craniofacial region especially orbital bones and paranasal sinuses (61.6%), maxilla (19.7%) and mandible (7%). Maxillary involvement may be responsible of nasal obstruction, epistaxis, and facial disfigurement. Other symptoms are related to the location and pressure effect on the region affected.

Radiographically, JOF appears as a well demarcated unilocular or multilocular osteolytic lesion with variable radiolucency and occasional opacification depending on the degree of calcification[8]. CT scan and MRI are used to assess the extending of the lesion.

This imaging examination including radiography, CT and MRI are neither specific nor diagnostic. In fact, diagnosis is obtained and confirmed by a histological examination[15]. Indeed, two distinct histopathological entities are described: Psammomatoid and trabecular type[9]. These two types can be distinguished from each other by the age in which they appear, the site involved and their clinical behavior. Psammomatoid JOF is predominantly but not exclusively described in children below 15 years old. According to many case series, it affects orbital bones, paranasal sinuses, and rarely mandible with an incidence of 8%. While the trabecular type, it occurs in older age, and affects mostly the maxilla followed by the mandible.[10],[11]

Accurate identification and diagnosis of these two different entities include fibrous dysplasia, which has for most authors a nearby histological structure. The only distinguishing feature between them is the fibrous capsule rarely seen in fibrous dysplasia[12]. Distinctness is important to make in order to establish a correct therapeutic management.

“Actually there is no definitive treatment of JOF. Surgical management including radical resection, local excision either conservatively or enucleation, with

curettage are among the treatment alternatives. In fact, treatment of choice is determined by the behavior, the location and the size of the lesion. However, JOF is known with its high rate of recurrence ranging from 30% to 58%”[13]. “Incomplete excision and difficulties in surgery are intimately linked to recurrences. So as to reduce recurrence rate, authors suggested segmental resection with a 5 mm margin as a definitive treatment of juvenile ossifying fibroma, a differed reconstruction and a long term follow up for at least 5 years”. [11]

### **Conclusion:**

Ossifying fibroma is a rare benign fibro osseous tumor. In fact, no cases of malignant transformation have been reported. It affects most of the time craniofacial region particularly the mandible. Pathogenesis is still unknown till now; diagnosis is based on clinical, radiological and histological criteria.

Despite the aggressive nature and the high rate of recurrence, the over-all prognosis is still good. Surgical management is the treatment of choice. The earlier diagnosis is done, the better surgical management.

### **Consent**

As per international standards, parental written consent has been collected and preserved by the author(s).

### **Ethical Approval:**

As per international standards or university standards written ethical approval has been collected and preserved by the author(s).

## **References:**

1. Shetty SK, Dasukil S, Arora G. Aggressive ossifying fibroma of the maxilla. *Ann Maxillofac Surg* 2020;10:262-6
2. Suleman AK, Naresh KS, Tarun S. Ossifying fibroma of maxilla in a male child: Report of a case and review of the literature. *Natl J Maxillofac Surg*. 2011; 2(1): 73–79
3. Wright JM, Vered M. Update from the 4th Edition of the World Health Organization classification of head and neck tumours: Odontogenic and maxillofacial bone tumors. *Head Neck Pathol* 2017;11:68-77
4. Luiz AB, Ondina KM, Rodrigo RR, Adriano RG, Márcia M. An aggressive case of juvenile ossifying fibroma of the craniofacial skeleton. *J Oral Maxillofac Surg Med Pathol* 2018; 30(5): 477-481
5. Şerefican FM, Yurttaş V, Ozan F, Akkaş I, Dağlı M. A rare cause of maxillary mass: juvenile ossifying fibroma. *Int J Otorhinolaryngol Head Neck Surg*. 2016 Apr;2(2):85-87.
6. Shetty SK, Dasukil S, Arora G. Aggressive ossifying fibroma of the maxilla. *Ann Maxillofac Surg* 2020;10:262-6.
7. Weerasinghe HR, Wijesuriya PC, Jayasooriya PR. Juvenile ossifying fibroma: an analysis of clinico-pathological features in a case series with a literature review. *Journal of Diagnostic Pathology*. 2016;11(2):14-21
8. Adepitan A, Owosho BChD et al. Psammomatoid and trabecular juvenile ossifying fibroma: two distinct radiologic entities.
9. Khawar A, Khan M, Khan M, Ahmad M. Juvenile ossifying fibroma in a 14-year-old female: A case report. *Ann Pak Inst Med Sci*. 2019; 15(2):85-88
10. Vura NG, Gaddipati R, Ramisetty S, Kumara R, Reddy R, Kanchi U. Surgical management of ossifying fibroma in maxilla. *Journal of International Oral Health*. 2015;7:115-8
11. Dwivedi A, Kour M. Juvenile ossifying fibroma of the mandible: a case report. *Indian J Case Reports*. 2019;5(6):545-547.
12. Oyosawa, S., Yuki, M., Kishino, M. et al. Ossifying fibroma vs fibrous dysplasia of the jaw: molecular and immunological characterization. *Mod Pathol* 20, 389–396 (2007).
13. Khanna J, Ramaswami R. Juvenile ossifying fibroma in the mandible. *Ann Maxillofac Surg* 2018;8:147-150
- [14] C. R., S. R., K. Mohideen, M. Balasubramaniam, S. Ghosh, et S. Dhungel, « Juvenile psammomatoid ossifying fibroma of the maxilla and mandible: A systematic review of published case reports », *Clin Exp Dent Res*, vol. 9, no 1, p. 186- 197, nov. 2022, doi: 10.1002/cre2.687.
- [15] L. H. C. Collins, N. F. T. Zeghal, I. Sassoon, et P. M. Speight, « A Clinical, Radiological and Histopathological Review of 74 Ossifying Fibromas », *Head and Neck*

Pathol, vol. 17, no 2, p. 433- 446, juin 2023,  
doi: 10.1007/s12105-022-01522-w.