

Phacolytic uveitis

Clinical Image :

We report the case of a 70-year-old diabetic and hypertensive patient on treatment who presented with progressive loss of visual acuity in both eyes, complicated by redness and slight pain in the left eye, Ophthalmological examination revealed visual acuity in the left eye with finger movements, conjunctival hyperhaemia, cornea with mixed retro-descemet precipitates, protein and cellular Tyndall rated at two crosses in the anterior chamber, with the presence of a hypopyon blade at an irregular upper level, cyclitic membrane with crystalline masses opposite the pupillary air, dense cataract on the lens (figure. 1,2,3), ocular tone at 19 mmhg, the rest of the examination inaccessible, examination of the Adelphe eye was normal, apart from a posterior subcapsular cortico-nuclear cataract, and additional B-mode ocular ultrasound to explore the posterior pole of the left eye was normal, apart from a posterior vitreous detachment. The patient was put on local and systemic corticosteroids, and her cataract was cured after mild control of ocular inflammation [1-3].

Phacoantigenic uveitis, also known as phacolytic uveitis, is caused by the release of soluble crystalline proteins through an intact capsule, following lysis of crystalline fibers in hypermature or rapidly progressing cataracts. Treatment is based on the early introduction of steroidal anti-inflammatory agents, using a combination of topical and systemic routes, to reduce the likelihood of secondary inflammatory

y complications and avoid affecting the prognosis of cataract surgery.



figure1: slit lamp image showing an inflammatory tyndall in the anterior chamber

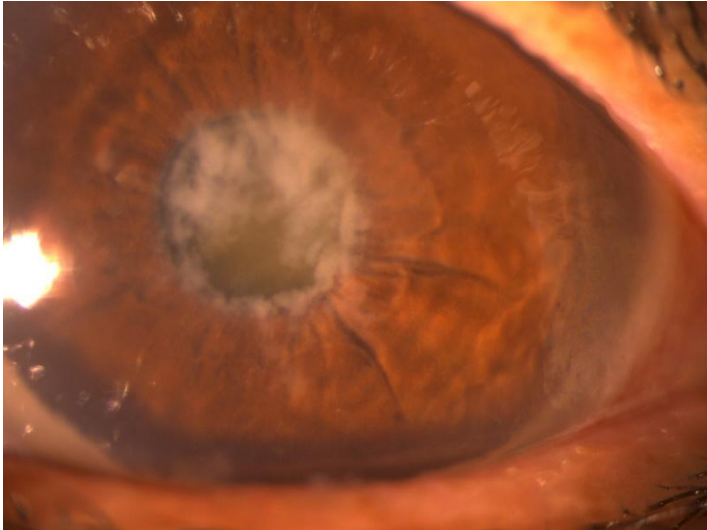


Figure2: slit lamp image showing crystalline masses with a cyclitic membrane

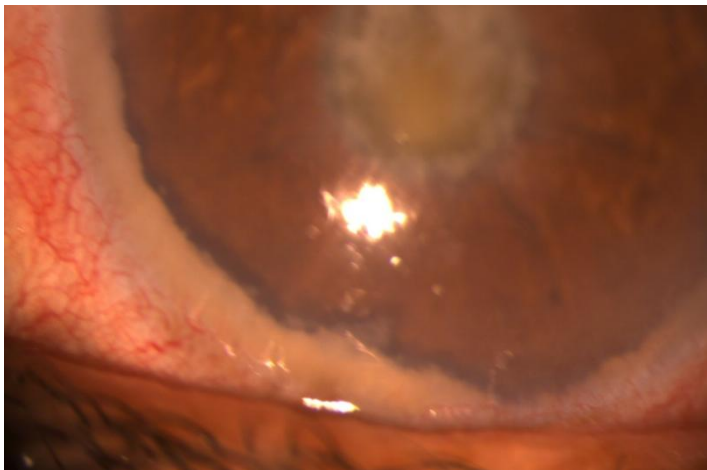


Figure3: slit lamp image showing a hypopyon in the anterior chamber

References

1. Van Der Woerdt A. Lens-induced uveitis. *Veterinary Ophthalmology*. 2000 Dec;3(4):227-34.
2. Filipe JC, Palmares J, Delgado LS, Lopes JM, Borges J, Castro-Correia J. Phacolytic glaucoma and lens-induced uveitis. *International Ophthalmology*. 1993 Oct;17:289-93.
3. Forster DJ. Phacoantigenic uveitis. *Ophthalmology Text Book*. 2004;2:1201-4.