

# Experimental infection with foodborne parasite (*Trichinella spiralis*) induced damage and apoptosis in rat skeletal muscle fibers

## ABSTRACT

**Aims:** Apoptosis, a type of host-cell death, frequently causes tissue damage in the deaths caused by parasite infections.

**Study Design:** In the current study, it was examined how experimental trichinellosis affected the skeletal muscles of rats and how it related to apoptosis.

**Methodology:** A total of 20 male rats (Sprague Dawley) were divided into 2 groups (Negative control and positive control or Infected).

**Results:** Current results revealed that; diffuse degenerative changes were present all over the muscle fibers with massive numbers of *T. spiralis* encysted larvae that were surrounded by a collagen capsule and mild inflammatory cellular infiltration in addition to elevation in apoptotic P53 proteins and reduction in anti-apoptotic Bcl2 in addition to muscle muscles injury.

**Conclusion:** So, we can it can be conclude that; eExperimental infection with *Trichinella spiralis* can induced damage and apoptosis in rat skeletal muscle fibers.

**Keywords:** *Trichinella spiralis*; Rats; Apoptosis; Skeletal muscles.

## 1. INTRODUCTION

Trichinellosis becomes a risk to public health as well as economic issues with the production of porcine animals and food safety [1]. One of the most common and prevalent zoonotic diseases in the world is the worm genus *Trichinella* [2]. Food is the primary source of transmission for the parasite disease trichinellosis [3]. Trichinellosis is caused incidentally when humans eat undercooked meat which containing *Trichinella* larvae [4]. Any type of *Trichinella* cannot infect humans if meat is properly cooked and frozen. The best method is to cook meat for one minute at 71°C Celsius. Furthermore, proper cooling to - 60°C for 2 minutes or - 55°C for 6 minutes typically kills *Trichinella* species. The smallest human nematode parasite ever detected is *Trichinella spiralis*. It has a tiny, light, thread-like appearance. Worms are tighter anteriorly than posteriorly in both male and female worms. *Trichinella* species start their life cycle by eating meat that has live larvae inside a cyst wall that is either raw or undercooked. The acidic environment (pepsin and hydrochloric acid) in the host's stomach causes the larvae to be freed from the cyst wall [5]. The quantity and frequency of exposure to contaminated meat affects The the severity of the Trichinellosis. There are three categories for the severity of the infection: light (0–10 larvae consumed),

Comment [u1]: Aims

Comment [u2]: Please elaborate on the aim of experiment

Comment [u3]: Write the methods used

Comment [u4]: induce

Comment [u5]: is a

Formatted: Strikethrough

Comment [u6]: this

Formatted: Strikethrough

Formatted: Strikethrough

Formatted: Strikethrough

Comment [u7]: contains

Formatted: Strikethrough

Formatted: Strikethrough

moderate (50–500 larvae consumed), and severe (more than 1000 larvae consumed). Humans and a number of other animal hosts that were infected with *Trichinella spiralis* developed an energetically costly liver organomegaly [6]. Other frequent side effects include CNS symptoms, cardiac inflammation, and/or pneumonia [7]. The most frequent symptoms are gastrointestinal (adult-caused) symptoms such as nausea, vomiting, diarrhoea, fever, periorbital oedema, and myalgia, but in severe circumstances, further effects of larvae migration can include encephalitis [8]. When cells are subjected to external stimuli that harm them, the expression of genes is regulated [9]. *Trichinella spiralis* promotes apoptosis in the lamina propria of the small intestine as well as in striated muscle, which may help to explain our findings, according to Karmaska et al. [10]. ~~Additionally, Boonmars et al. [12] investigate the function of apoptotic P53 in *Trichinella spiralis* cyst development. As a result, This study has evaluated how experimental trichinellosis affected the rats' skeletal muscles and its relationship to apoptosis.~~

Comment [u8]: in

Formatted: Strikethrough

Comment [u9]: Previous research have documented the function of apoptotic.....development [12].

Formatted: Strikethrough

## 2. MATERIAL AND METHODS

### 2.1. ANIMALS GROUPS

This study included 10 male albino rats (*Rattus norvegicus*), apparently healthy and free of parasitic infection and divided into 2 groups.

**Group 1:** Control group (-ve), in which normal healthy non-infected animal.

**Group 2:** Control Infected group (+ve), in which rats were challenged with 1000 larvae of *trichinella* *Trichinella spiralis*.

### 2.2. Sample collection

At the end of the experiment, overnight fasted rats ~~will be were~~ anaesthetized with diethyl ether, dissection ~~take took~~ place for 5 weeks and *T. spiralis* muscle larvae was obtained from laboratory bred infected rats. Larval preparation and extraction of inoculums were made ~~after as per~~ Dunn and Wright [13].

### 2.3. Histopathological assessment

Skeletal muscles were fixed in 10% formalin, and the fixed samples were paraffin sectioned, then examined using haematoxylin and eosin stains, as described by Tousson [14].

### 2.4. Determination of apoptotic markers expressions

Apoptotic P53 proteins and anti-apoptotic Bcl2 immunoreactivities were made in fixed tongue sections, which were evaluated using the avidin-biotin complex method [15&16].

## 3. RESULTS

### 3.1 Histopathological examination

~~Figure 1 shown~~ the histological changes in the rat skeletal muscle fibers in control and infected group have been presented in Figure 1. Normal myofibrillar structure with striations that consist of bundles of elongated were observed in the skeletal muscles in control group (Fig 1A), Skeletal muscles in infected group showed diffuse degenerative changes all over the muscle fibers with massive numbers of *T. spiralis* encysted larvae that were surrounded by a collagen capsule and mild inflammatory cellular infiltration (Fig. 1B & 1C).

### 3.2 P53 expression

~~Figure 2 shown the~~ The p53 expressions in the rat skeletal muscle fibers in control and infected groups are represented in Figure 2. Negative or faint positive reactions for p53 expressions were detected in

Formatted: Font: Italic

skeletal muscle fibers in control group (Fig 2A) while moderate to strong positive reactions for p53 expressions were observed in skeletal muscle fibers in infected group (Figure 2B & 2C).

### 3.3 Bcl2 expression

~~Figure 3 shown the~~ Bcl2 expressions in the rat skeletal muscle fibers in control and infected groups have been depicted in Figure 3. Strong positive reactions for Bcl2 expressions were detected in skeletal muscle fibers in control group (Figure 3A) while mild positive reactions for Bcl2 expressions were observed in skeletal muscle fibers in infected group (Figure 3B & 3C).

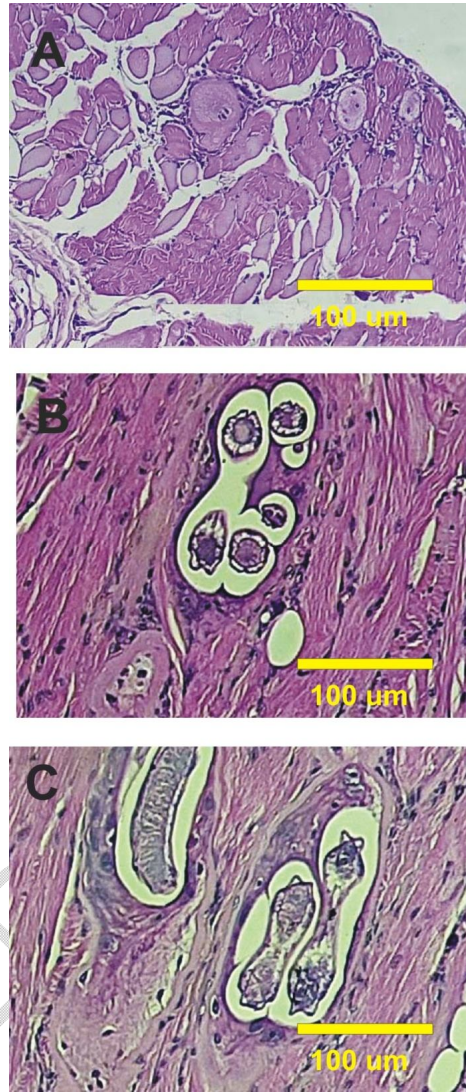
### 4. Discussion

Apoptosis, a type of host-cell death, frequently causes tissue damage in the deaths caused by parasite infections. But rather than being harmful, parasite-induced apoptosis might promote host survival. It is different than the direct injury brought on by the parasite itself, there are a number of different mechanisms that contribute to the tissue destruction in trichinellosis. One of the main causes of this damage is the oxidative stress state that results from *Trichinella* infection, as demonstrated by the increased production of numerous stress indicators [17]. There-fore current study aimed to study the effects of experimental trichinellosis on rat skeletal muscles damage. According to recent findings, *Trichinella spiralis* caused marked muscle fibrosis and widespread degenerative changes throughout the muscle fibres in experimentally infected rats' skeletal muscles. On the other hand, each encysted larva was surrounded by a collagen capsule and mild inflammatory cellular infiltration made up primarily of lymphocytes, eosinophils, and plasma cells, with areas of coagulative necrosis. Our results agree with Basyoni and El-Sabah [18] who found ~~find~~ that muscle cells in *Trichinella spiralis* infection revealed degenerative changes all over the muscle fibers and diffuse with massive numbers of *T. spiralis*.

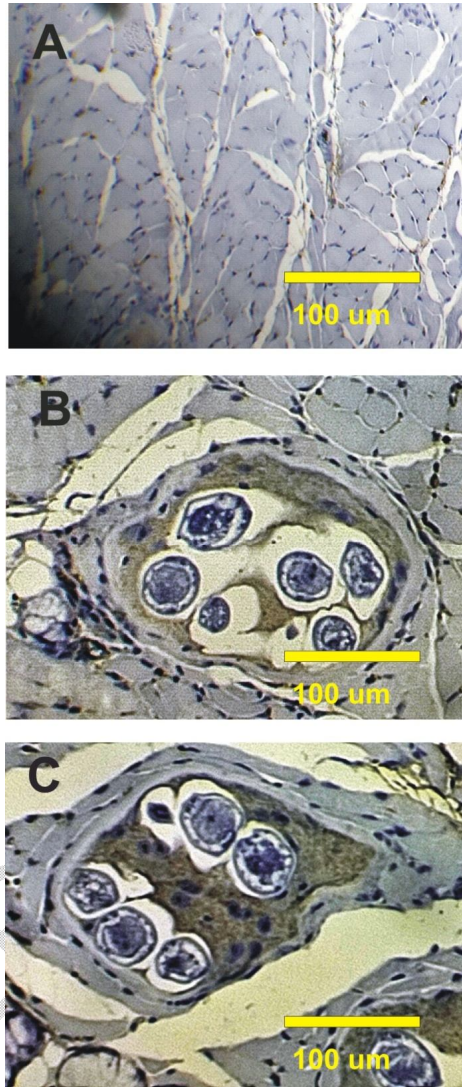
P53 may indeed play some role in mitochondria-mediated apoptosis in the basophilic cytoplasm, but it is not indispensable for the induction of apoptosis in the basophilic cytoplasm. Parasites can provoke apoptosis by two means; either directly via active mediators or indirectly through the mediators of inflammation. Current results revealed that; skeletal muscles that infected with *Trichinella spiralis* induced a significant elevation of the apoptotic protein p53 and significant depletion in Bcl2 comparing with the control one. Our findings may be explained by Karmańska *et al.*, [11] who reported that *Trichinella spiralis* induces apoptosis in the lamina propria of the small intestine and also in striated muscle. Also; Boonmars *et al.* [12] studies the role of apoptotic P53 during the cyst formation of *Trichinella spiralis*. These results also agreed with Etewa *et al.* [19] and Ibrahim *et al.* [20] who reported that infected rats with that *T. spiralis* showed degenerative changes with marked apoptosis.

Formatted: Font: Italic

Formatted: Font: Italic

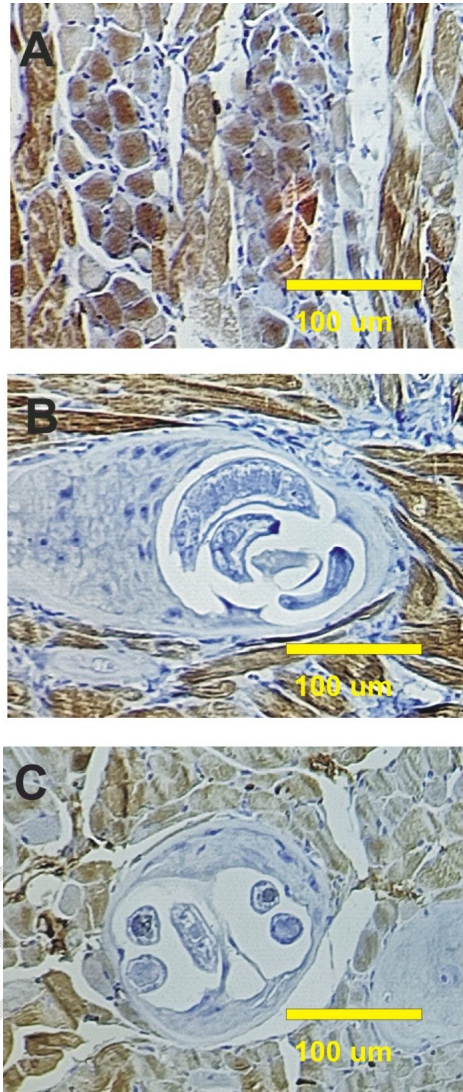


**Figure 1:** A Photomicrograph of skeletal muscle fibers section in control and infected experimental groups. A: Normal myofibrillar structure with striations in skeletal muscles in control group.. B&C: Muscle fibers with massive numbers of *T. spiralis* encysted larvae; encysted larvae were separated from thin cyst wall by spaces, muscle tissue has mild inflammatory cells.



**Figure 2:** A Photomicrograph of skeletal muscle section stained with P53 in section in control and infected experimental groups. **A:** Rat muscle fibers in control showed fine positive reactions for p53 expressions **B&C:** Strong to moderate positive reaction for P53 in muscle fibers of infected rats with *T. spiralis* in encysted larvae and intact muscles.





**Figure 3:** A Photomicrograph of muscle section stained with Bcl2 in control and infected experimental groups. A: Rat muscle fibers in control group showed strong positive reactions for Bcl2 expressions B&C: Mild positive reaction for Bcl2 in muscle fibers of infected rats with *T. spiralis* in encysted larvae and intact muscles.

## 5. CONCLUSION

In the present investigation, Skeletal muscles that were infected with *Trichinella spiralis* induced diffuse degenerative changes all over the muscle fibers with massive numbers of *Trichinella spiralis* encysted larvae that were surrounded by a collagen capsule and mild inflammatory cellular infiltration; in addition to

a significant elevation of the apoptotic protein p53 and significant depletion in bcl2 ~~compared comparing to~~ with the control ~~one~~.

#### CONSENT

It is not applicable.

#### ETHICAL APPROVAL

Animal Ethic committee approval has been collected and preserved by the author(s).

#### 6. REFERENCE

- 1 Dorny, P., Praet, N., Deckers, N., Gabriel, S., 2009. Emerging food-borne parasites. *Veterinary Parasitology*, 163, 196–206.
- 2 Zhang, N., Li, W. and Fu, B., 2018. Vaccines against *Trichinella spiralis*: progress, challenges and future prospects. *Transboundary and emerging diseases*, 65(6), pp.1447-1458.
- 3 Murrell, K.D. and Pozio, E., 2011. Worldwide occurrence and impact of human trichinellosis, 1986–2009. *Emerging infectious diseases*, 17(12), p.2194.
- 4 Neghina, R., Moldovan, R., Marincu, I., Calma, C.L. and Neghina, A.M., 2012. The roots of evil: the amazing history of trichinellosis and *Trichinella* parasites. *Parasitology research*, 110, pp.503-508.
- 5 Saad, A.E. and Ghanem, H.B., 2020. *Trichinella Spiralis* as a potential therapeutic agent: from a risky disease to a friend. *Journal of the Egyptian society of parasitology*, 50(1), pp.119-126.
- 6 Meagher, S. and Dudek, S.N., 2002. Effects of *Trichinella spiralis* on survival, total mass, and organ mass of oldfield mice (*Peromyscus polionotus*). *Journal of Parasitology*, 88(5), pp.833-838.
- 7 Watt, G., Saisorn, S., Jongsakul, K., Sakolvaree, Y. and Chaicumpa, W., 2000. Blinded, placebo-controlled trial of antiparasitic drugs for trichinosis myositis. *The Journal of infectious diseases*, 182(1), pp.371-374.
- 8 Gottstein B, Pozio E and Nöckler K. (2009): Epidemiology, diagnosis, treatment, and control of trichinellosis. *Clin Microbiol Rev*, 22(1):127–145.
- 10 El-Aarag, B., Attia, A., Zahran, M., Younes, A., Tousson, E., 2021. New phthalimide analog ameliorates CCl4 induced hepatic injury in mice via reducing ROS formation, inflammation, and apoptosis. *Saudi journal of biological sciences*. 28(11), 6384-95.
- 11 Karmańska, K., Houszka, M., Piekarska, J., 2000. The phenomenon of apoptosis in the course of experimental trichinellosis in mice. *Wiad Parazytol*. 46, 111–115.
- 12 Boonmars, T., Wu, Z., Nagano, I., Takahashi, Y., 2005. *Trichinella pseudo spiralis* infection is characterized by more continuous and diffuse myopathy than *T. spiralis* infection. *Parasitol Res*. 97, 13–20.
- 13 Dunn, I.J. and Wright, K.A., 1985. Cell injury caused by *Trichinella spiralis* in the mucosal epithelium of B10A mice. *The Journal of parasitology*, pp.757-766.
- 14 Tousson, E., 2016. Histopathological alterations after a growth promoter boldenone injection in rabbits. *Toxicology and industrial health*. 32(2), 299-305.
- 15 Tousson, E., Hafez, E., Zaki, S., Gad, A., 2014. P53, Bcl-2 and CD68 expression in response to amethopterin-induced lung injury and ameliorating role of l-carnitine. *Biomedicine & Pharmacotherapy*. 68(5), 631-9.
- 16 Tousson, E., Hafez, E., Zaki, S., Gad, A., 2016. The cardio protective effects of L carnitine on rat cardiac injury, apoptosis, and oxidative stress caused by amethopterin. *Environmental Science and Pollution Research*. 23(20), 20600-8.
- 17 Mido, S., Fath, E.M., Farid, A.S., Nonaka, N., Oku, Y. and Horii, Y., 2012. *Trichinella spiralis*: Infection changes serum paraoxonase-1 levels, lipid profile, and oxidative status in rats. *Experimental parasitology*, 131(2), pp.190-194.
- 18 Basyoni, MM., El-Sabah, AA., 2013. Therapeutic potential of myrrh and ivermectin against experimental *Trichinella spiralis* infection in mice. *Korean J. Parasitol*. 51(3), 297-304.
- 19 Etewa, S.E., Fathy, G.M., Abdel-Rahman, S.A., El-Khalik, D.A., Sarhan, M.H., Badawey, M.S., 2018. The impact of anthelmintic therapeutics on serological and tissues apoptotic changes induced by experimental trichinosis. *Journal of Parasitic Diseases*. 42(2), 232–242.

20 Ibrahim, S., Sarhan, MH., Farag, TL, Mohamed, AH., 2019. Apoptic and vascular changes in trichinella spiralis infected mice after parenteral artmethether treatment. Journal of the Egyptian Society of Parasitology. 49(1), 17-27.

UNDER PEER REVIEW