

Original Research Article

Panoramic Radiography- A Diagnostic Marker for early detection of Stroke

ABSTRACT

Purpose: To establish the validity of Panoramic radiography as an adjunct diagnostic tool for early detection of Stroke.

Materials and Methods: The Study Subjects were subjected to Panoramic Radiography to verify prevalence of CAC on Panoramic Radiographs.

Results: CAC was seen on right side in 72.5% case groups and on the left side in 87.5% case groups. Also, unilateral carotid calcification is seen in 40% cases and bilateral carotid calcifications seen in 60% cases

Conclusion: Dentists play a very important role in early detection of stroke by identifying the carotid artery calcification in a routine dental panoramic radiograph. This would help reduce morbidity and bring significant savings in overall health care costs associated with atherosclerosis.

Keywords: atherosclerosis, Carotid artery calcification, panoramic radiograph, stroke

1. INTRODUCTION

Panoramic imaging (orthopantomogram or OPG) is a technique for producing single image of facial structures including both maxillary and mandibular arches with supporting structures. Panoramic images are useful for diagnosing conditions requiring broad coverage of the jaws. Common examples include evaluation of jaw fractures, extensive osseous disease, suspected large lesions etc. **Lately,** OPGs provide an added advantage to be used as diagnostic aid for detection of systemic disease.¹

General dentists should be well acquainted with systemic conditions manifesting in the dentomaxillofacial complex, so that early diagnosis can be made. Oral health care is an integral part of medical care. Having an advantage of living in the 21st century and with recent advances in the field of radiology, it is very much possible to detect these conditions at an early stage and accordingly refer the patients for appropriate treatment.

Stroke is one such condition and is one amongst the leading causes of death and disability in India.

Atherosclerosis is the most common cause of stroke. It consists of formation of calcium rich fatty plaques on walls of arteries and their ramification which can be diffuse and/or localised and contribute to narrowing and hardening of arteries in combination with accumulation of fat in artery wall which is known as Atheroma.²

The main cause of cerebrovascular accidents is rupture of these atherosclerotic plaques present in carotid arteries. The carotid bifurcation is at the highest risk of atherosclerosis. At carotid arterial bifurcation, flow velocity and shear stress are reduced, and flow departs in a laminar, unidirectional pattern. Fatty streaks located at bifurcations may progress to smooth muscle-rich fibrous plaques that are prone to calcification.³

On occasion, these lesions are partially calcified and visible on a conventional panoramic dental radiograph. The known prevalence range of positive incidental carotid artery calcifications in the general dental population is 2% to 5%.⁴

The atheroma may appear either as a nodular radiopaque mass or as two radiopaque vertical lines within soft tissues of the neck at the level of lower margin of the third cervical vertebra (C3). These opacities are separate and distinct from the hyoid bone and variably appear above or below it. So, any radiopaque nodular mass adjacent to the cervical vertebrae inside or below the C3-C4 intervertebral disc level, or in the retro-mandibular area, generally at an angle of 45° from the angle of mandible independent of hyoid bone is considered as a Carotid artery calcification (CAC).

Considering that Atherosclerosis is a disease that has delayed clinical manifestations and may even show no clinical symptoms, any diagnostic method that allows the detection of Atherosclerotic plaques before the blood flow becomes too restricted is very important. Panoramic radiograph is one such method which is very valuable for early detection of atheroma plaques in carotid artery and thereby helps in minimising the patient's risk.

Dental practitioners as health care providers ought to play their part in this issue and contribute, ~~within their means,~~ to the early detection of patients at risk of having Cerebrovascular accidents.

If the oral and maxillofacial manifestations of a systemic disorder are identified during routine dental care and the patient is referred for appropriate follow up and management, it would help reduce morbidity and bring significant savings in overall health care costs associated with atherosclerosis as early treatment can be initiated by appropriate healthcare professional, with the objective of repairing or mitigating acute or chronic ischemic lesions, therefore preventing serious manifestations and preserving patient's quality of life.⁵

Panoramic radiographs are the most frequently used screening tool in dental practice. They consist of a radiographic method that uses low doses of radiation, is low cost and has technical simplicity that makes it extremely useful in identifying anatomical structures of head and neck region. It is therefore logical to use this widely available diagnostic tool to screen for calcifications in the cervical carotid arteries.^{6,7,8,9}

The need of the study is palpable-appreciable from the fact that not much recognition is given to this routine dental radiograph towards diagnosing the systemic disorders and so the present study aims to fill the lacunae / gaps in the existing knowledge and /or controversy regarding validation of panoramic imaging as an adjunct screening tool for early detection of cerebrovascular accidents (stroke).

2. METHODOLOGY

The study was carried out in the Department of Oral Medicine & Radiology.

Inclusion Criterion:

1. Subjects with medical history of hypertension, diabetes mellitus, hypercholesterolemia and coronary artery disease which are known to be associated with atherosclerosis and prone to develop stroke
2. Subjects with a positive habit history of long-term smoking, alcohol abuse which are known to be associated with atherosclerosis and prone to develop stroke

3. Inadequate Diet and Eating Habits coupled with overweight and a sedentary lifestyle which are known to be associated with atherosclerosis and prone to develop stroke
4. Patients who require panoramic radiographs for dental needs
5. An equal number of healthy controls were recruited from the outpatient department (OPD) of Department of Oral Medicine and Radiology

Exclusion Criterion:

Panoramic radiographs with low diagnostic quality.

All Panoramic Radiographs were interpreted. Any radiopaque nodular mass adjacent to the cervical vertebrae inside or below the C3-C4 intervertebral disc level, or the retro-mandibular area, generally at an angle of 45° from the angle of mandible independent of hyoid bone was considered as a Carotid artery calcification (CAC). CAC were scored as present or absent.

3. RESULTS

The subjects consisted of 80 individuals whose panoramic radiograph was evaluated to detect carotid artery calcification. CAC was seen on right side in 72.5% case groups and on the left side in 87.5% case groups. Also, unilateral carotid calcification is seen in 40% cases and bilateral carotid calcifications seen in 60% cases. (table 1)(figure 1)

Table 1: Descriptive data of all variables among cases and controls

Variables	Case	Control
Age		
35-45 years	11 (13.8%)	11 (13.8%)
45-55 years	10 (12.5%)	10 (12.5%)
55-65 years	9 (11.2%)	9 (11.2%)
>65 years	10(12.5%)	10(12.5%)
Gender		
Male	25(31.2%)	25(31.2%)
Female	15 (18.8%)	15 (18.8%)
BMI		
Normal	1(1.2%)	18 (22.5%)
Overweight	31(38.8%)	22(27.5%)
Obesity	8(10%)	0(0%)
Medical Condition		
Diabetes	26 (40%)	0(0%)
Coronary Artery	6 (15%)	0(0%)

Disease		
Hypercholestrimia	13 (32.5%)	0(0%)
Hypertension	25 (62.5%)	0(0%)
Smoking	8 (20%)	0(0%)
Alcohol	8(20%)	0(0%)
Carotid calcification		
Right	29(72.5%)	0(0%)
Left	35(87.5%)	0(0%)
Unilateral	16(40%)	0(0%)
Bilateral	24(60%)	0(0%)

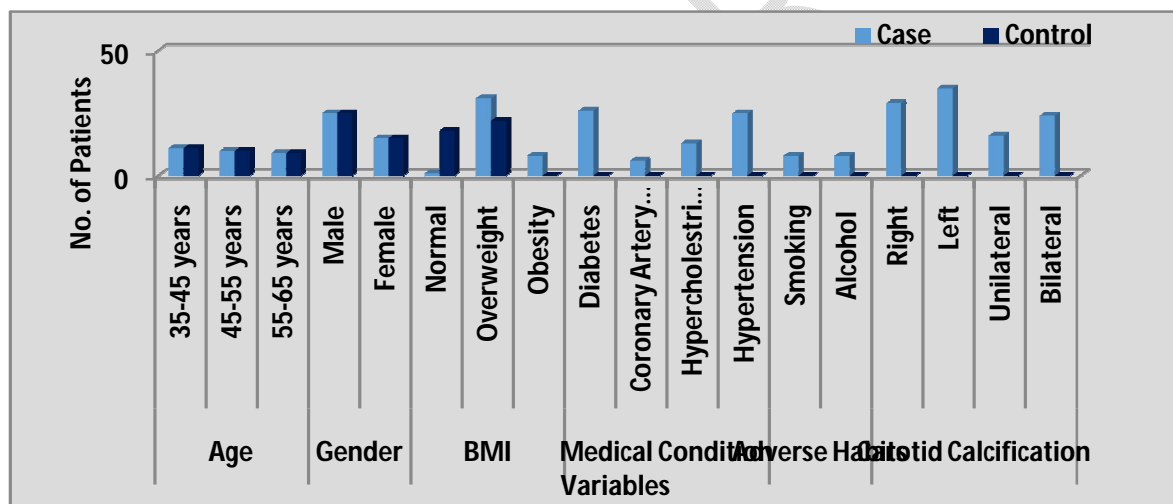


Figure 1: Descriptive data of all variables among cases and controls

40% patients had history of diabetes, 62.55% were hypertensive, 32.5% had hypercholestrimia and 15% were patients with history of coronary artery calcification. . In diabetic patients, CAC was seen on right side in 45% case groups and on the left side in 57.5% case groups. Hypertensive patients had CAC on right side in 47.5% and on left side in 20% case groups. In patients with coronary artery disease, it was seen in 10% and 15% case groups and in patients with hypercholestrimia in 22.5% and 27.5% case groups on right and left side respectively.(table 1& 2)(figure 1&2)

Table 2 : Association between medical condition and carotid calcification

Medical Condition	Right	Left	Unilateral	Bilateral
Diabetes	18(45%)	23(57.5%)	11(27.5%)	15(37.5%)
Coronary Artery Disease	4(10%)	6(15%)	2(5%)	4(10%)
Hypercholestrimia	9(22.5%)	11(27.5%)	6(15%)	7(17.5%)
Hypertension	19(47.5%)	20(%)	11(27.5%)	14(35%)
Chi-square value	3.497	17.143	6.204	6.204
p-value	0.836	0.016	0.516	0.516
S/NS	NS	S	NS	NS

($p \leq 0.05$ – Significant, CI = 95 %)

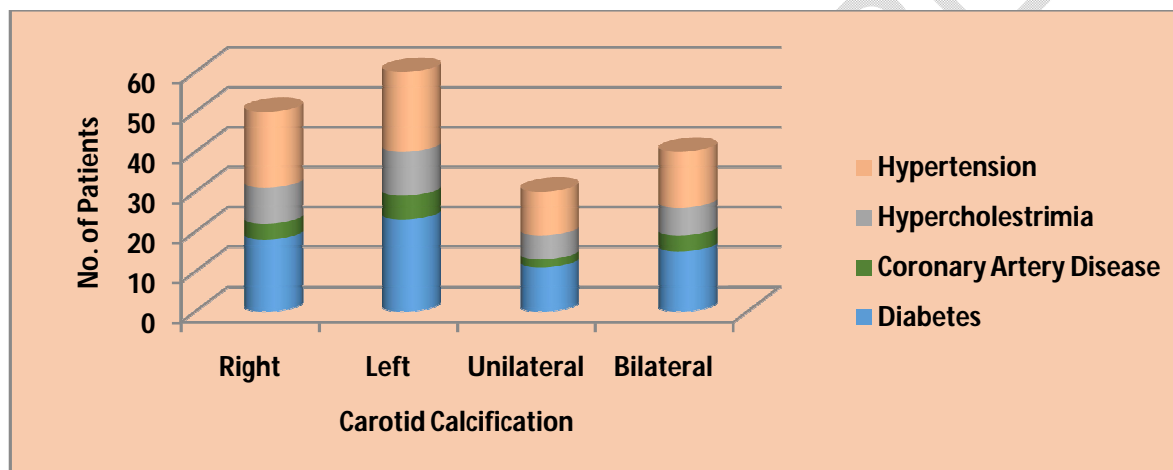


Figure 2 : Association between medical condition and carotid calcification

CAC on right side was seen in 22.5%, 17.5%, 15% and 17.5% case groups and on left side in 25%,22.5%,15% and 25% case groups belonging to age group 35-45years, 45-55years,55-65years and >65 years respectively.(table 3)(figure 3)

Table 3 : Association between age groups and carotid calcification

Age	Right	Left	Unilateral	Bilateral
35-45 years	9(22.5%)	10(25%)	3 (7.5%)	8(20%)
45-55 years	7(17.5%)	9(22.5%)	4 (10%)	6 (15%)

55-65 years	6(15%)	6(15%)	6 (15%)	3 (7.5%)
>65 years	7(17.5%)	10(25%)	3 (7.5%)	7(17.5%)
Chi-square value	0.695	5.174	6.204	3.826
p-value	0.874	0.159	0.516	0.218
S/NS	NS	NS	NS	NS

($p \leq 0.05$ – Significant, CI = 95 %)

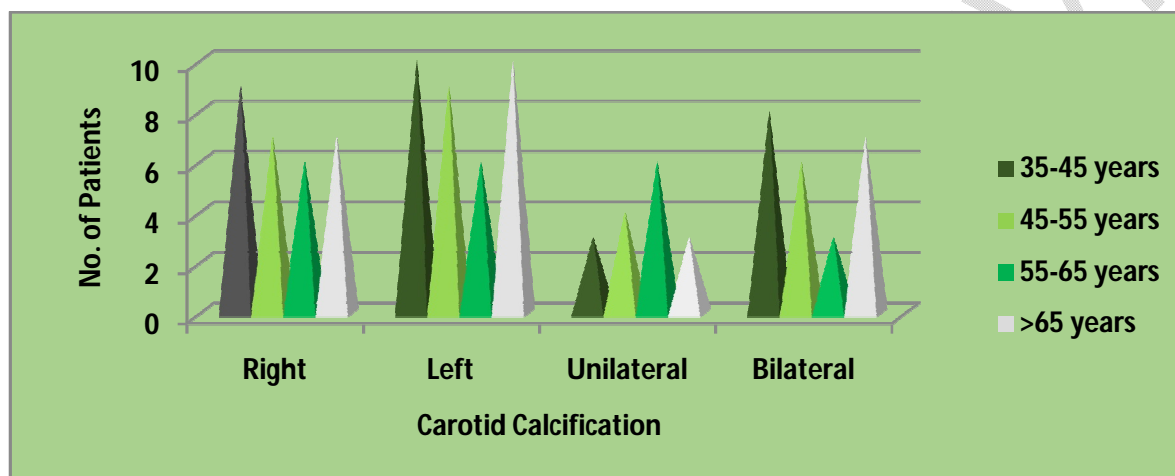


Figure 3 : Association between age groups and carotid calcification

Also, CAC seen on right side were in 47.5% male and 25% female case groups and on left side , it was seen in 55%male and 32.5% female age groups.(table 4)(figure 4)

Table 4 : Association between gender and carotid calcification

Gender	Right	Left	Unilateral	Bilateral
1	19(47.5%)	22(55%)	9 (22.5%)	16(40%)
2	10 (25%)	13(32.5%)	7 (17.5%)	8 (20%)
Chi-square value	0.410	0.015	0.444	0.444
p-value	0.522	0.902	0.505	0.505
S/NS	NS	NS	NS	NS

($p \leq 0.05$ – Significant, CI = 95 %)

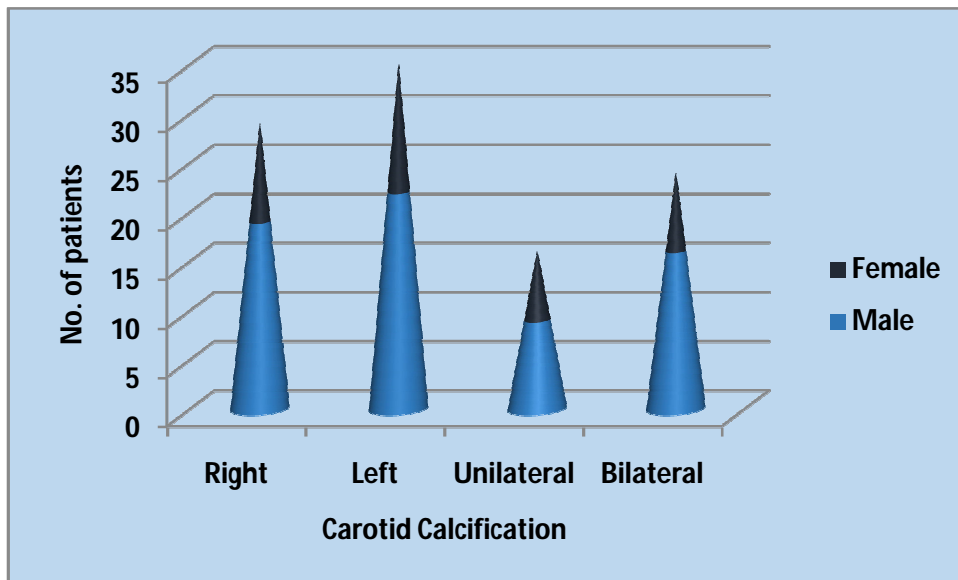


Figure 4 : Association between gender and carotid calcification

Patients with smoking habit had CAC on right side in 47.5% case group and on left side in 55% case groups. In patients with alcohol consumption habit, CAC was seen in 25% and 32.5% cases on right and left side respectively. (table 5)(figure5)

Table5 : Prevalence of Carotid calcification among smokers and alcohol consumers

Risk Factor	Right	Left	Unilateral	Bilateral
Smoking	29(47.5%)	35(55%)	16 (40%)	24(60%)
Alcohol	5 (25%)	8(32.5%)	3 (17.5%)	5 (20%)

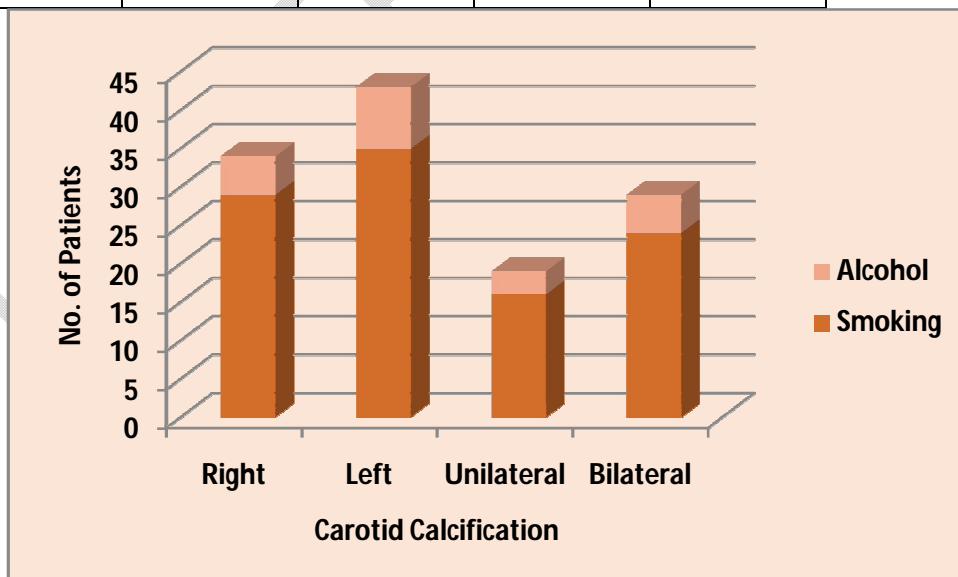


Figure 5 : Prevalence of Carotid calcification among smokers and alcohol consumers

In overweight patients, CAC was 57.5% and 67.5% case groups on right and left side respectively and in patients with obesity, it was seen in 15% and 17.5% case groups on right and left side respectively. However, in patients with normal BMI, no CAC was found on right side and on left side only 2.5% case groups showed CAC.(table 6)(figure 6)

Table6 : Association between BMI and carotid calcification

BMI	Right	Left	Unilateral	Bilateral
1	0(0%)	1(2.5%)	1 (2.5%)	0(0%)
2	23 (57.5%)	27(67.5%)	12 (30%)	19 (47.5%)
3	6 (15%)	7(17.5%)	6 3(7.5%)	5 (12.5%)
Chi-square value	2.706	0.147	1.542	1.542
p-value	0.258	0.929	0.462	0.462
S/NS	NS	NS	NS	NS

($p \leq 0.05$ – Significant, CI = 95 %)

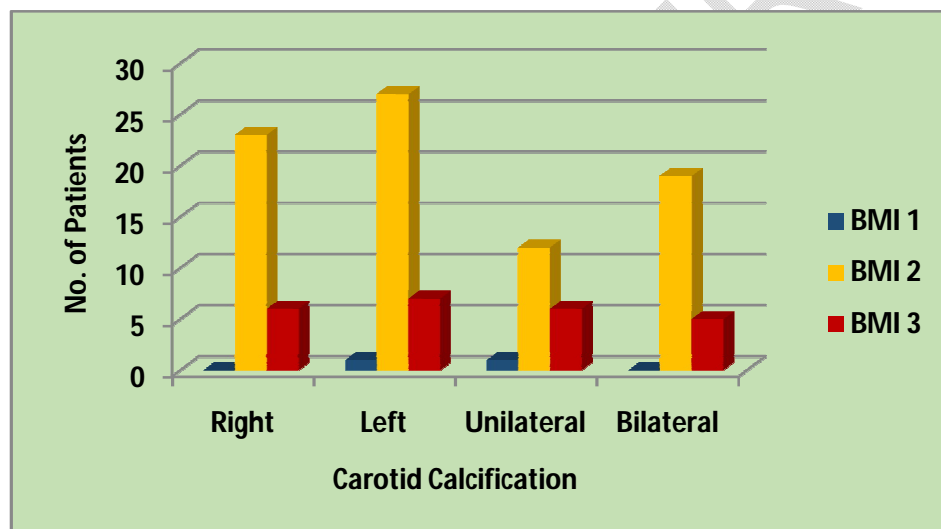


Figure 6 : Association between BMI and carotid calcification

Discussion

Atherosclerosis is the main cause of myocardial infarctions and strokes in the world population, determining the death of many people. The disease presents a complex etio-pathogenesis involving a sequence of biological mechanisms.

Diabetes mellitus, obesity, arterial hypertension and inadequate diet and eating habits are the classical risk factors for this disease

One of the manifestations of atherosclerosis is formation of atheroma, which are characterized by large accumulations of lipids, fibrous tissues, calcium deposits, blood, and blood products, among others

Atheromas are the base plates of atherosclerosis, especially constituted of lipids and fibrous tissue, which are deposited on the arterial walls and become calcified, making it feasible to identify them in certain radiographic exams. In view of this, the atheromas that affect the carotid arteries are capable of being viewed in panoramic radiograph, widely used exam in routine dental practice

In dentistry, panoramic radiography is a common procedure performed to detect signs of oral diseases. Several studies have identified that it is possible to detect signs of carotid calcifications from such radiographs given that the region of interest is exposed. Radiographs, exposed for dental reasons, can be assessed for calcifications in the carotid area.

The main aim of our study was to establish the validity of panoramic radiography as an adjunct diagnostic tool for early detection of stroke.

Also, our objectives were to identify Carotid Artery calcifications (CAC) on panoramic radiographs in high risk patients.(Disease group) as well as in healthy controls.(Control group)

And to compare the occurrence between disease group and control group.

Our present study evaluated 80 panoramic radiographs to detect carotid artery calcification as a diagnostic marker for early detection of stroke, and assessed their relationship with the risk factors for vascular diseases.

In the present study Carotid calcification seen on right side in 72.5% case groups and on the left side in 87.5% case groups. Also, unilateral carotid calcification is seen in 40% cases and bilateral carotid calcifications seen in 60% cases.

In certain previous studies, the prevalence of CAC in Panoramic radiographs has been reported to range from 0.43% to 5%, depending on variables such as age, gender, ethnicity, and lifestyle^{10,11,12}

Friedlander and Lande first found the incidence of CCA on PRs and suggested that the panoramic image may be a helpful in detecting patients at risk of stroke. Since the first report, many studies have been carried out to determine the incidence of CCA on Panoramic radiographs and to verify the usefulness of the Panoramic radiograph in the identification of stroke-prone patients through correlation with medical history^{9,10}

In our study, CAC~~has~~ was found to be associated with medical histories. In diabetic patients, CAC was seen on right side in 45% case groups and on the left side in 57.5% case groups. Hypertensive patients had CAC on right side in 47.5% and on left side in 20% case groups. In patients with coronary artery disease, it was seen in 10% and 15% case groups and in patients with hypercholesterolemia in 22.5% and 27.5% case groups on right and left side respectively.

CAC was also found in patients who were overweight or ~~obess~~obese. In overweight patients, CAC was 57.5% and 67.5% case groups on right and left side respectively and in patients with obesity, it was seen in 15% and 17.5% case groups on right and left side respectively. However, in patients with normal BMI, no CAC was found on right side and on left side only 2.5% case groups showed CAC.

A study by Tamura *et al* evaluated the prevalence of carotid calcifications in 2568 panoramic radiographs, and assessed their relationship with the risk factors for vascular diseases. They found that individuals with carotid calcifications had medical histories that included hypertension (27.6%), obesity (21.1%), hyperlipidemia (14.5%), and cardiovascular diseases (13.2%), all of which are recognized risk factors for atheromas and showed that the detection of carotid calcifications on panoramic radiographs may help prevent stroke.¹¹

Other authors associate CAC with other diseases, such as diabetes, hypertension and hyperlipidemia.^{9,13,14}

However, Ohba *et al* report~~that~~ found no difference in blood pressure, cholesterol and blood sugar in patients with CAC and patients without CAC.¹⁵

Ertas and Sisman also found no association between diabetes and CAC.¹⁶

A study by Tofangchiha *et al*/involving 158 patients with diabetes mellitus type 2 showed that the frequency of calcified carotid atheromas on panoramic radiographs is higher in diabetic patients than in normal individuals. Thirty-eight (82.6%) of the 46 diabetic patients diagnosed with calcification, in the afore-mentioned study, presented with unilateral calcifications, while 8 (17.4%) of them had bilateral calcifications ($P < 0.001$).¹⁷

In our study, **prevalence** of CAC varied among the gender. CAC seen on right side were in 47.5% male and 25% female case groups and on left side, it was seen in 55% male and 32.5% female age groups.

Also, the association between age groups and carotid calcification include CAC on right side in 22.5%, 17.5%, 15% and 17.5% case groups and on left side in 25%, 22.5%, 15% and 25% case groups belonging to age group 35-45 years, 45-55 years, 55-65 years and >65 years respectively

Friedlander and Cohen reported that 26% of men (mean age 66 years) with CAC diagnosed by Panoramic Radiograph showed some adverse vascular event (myocardial infarction, stroke, revascularization, transient ischemic attack, angina).

¹⁸These authors suggest that the accidental finding of CAC predicts a significant risk of future vascular event.

The results obtained by Griniatsos *et al* corroborate those reported by Friedlander and Cohen when indicate that patients with carotid calcified plaque detectable by PR are more likely to have suffered a stroke.¹⁹

Kumagai *et al*, Ardakani *et al* and Madden *et al* associate increasing age with the highest prevalence of CAC. In men over 50 years the prevalence was between 2% and 3.8%. In samples from individuals of both sexes, aged ≥ 30 years, the prevalence varied among 2.1%-6.2%^{9,10,18}

Brand *et al* and Johansson *et al*, who also worked with individuals of both sexes, reported the prevalence of 9.4% and 9.9%, respectively, very expressive values when we consider the general population.²⁰

According to our study, certain habits serve as a risk factor in development of calcification seen in carotid artery which commonly include smoking and alcohol. Patients with smoking as habit had CAC on right side in 47.5% case group and on left side in 55% case groups. In patients with alcohol consumption as habit, CAC was seen in 25% and 32.5% cases on right and left side respectively.

Ertas and Sisman report that the increased risk of CAC is associated with an increase in ~~length of time~~ smoking duration, a finding also reported in other studies.²¹

Panoramic radiography is of fundamental importance in early and incidental diagnosis of carotid atheroma. It is the dental surgeon's duty to recognize atheroma in carotid artery area while inspecting panoramic radiography images and to refer the patients to the relevant health professional for appropriate treatment. This is in order to ensure patients' quality of life and their well-being.

Since Atherosclerosis is a cardiovascular disease with enormous impact all over the world and preventive measures must be taken to diminish its incidence. Changes in lifestyle, including ~~adequate~~ proper diet and eating habits, practicing physical activity and a less stressful life are important strategies in the primary prevention of this pathology.

When dentists are faced with a suspicion of the presence of carotid artery atheromas in panoramic radiographs, they play **an** important role in guiding and immediately referring their patients to doctors for adequate medical treatment, thus contributing to many lives possibly being saved.

UNDER PEER REVIEW

4. CONCLUSION

~~As a result,~~ CACs found as incidental findings on ~~standard PRs~~ Panoramic radiographs may serve as important markers for future coronary artery disease, strokes and death

Panoramic radiographs should be clearly examined for detection of carotid artery calcification especially in patients associated with certain risk factors such as medical history (diabetes, hypertension, coronary artery disease, hypercholesterolemia etc.) or habits (smoking, alcohol consumption) etc.

In conclusion, we believe that dentists play a very important role in early detection of stroke by identifying the carotid artery calcification in a routine dental panoramic radiograph. This would help reduce morbidity and bring significant savings in overall health care costs associated with atherosclerosis.

CONSENT

All authors declare that 'written informed consent was obtained from the patient (or other approved parties) for publication of this case report and accompanying images

ETHICAL APPROVAL

All authors hereby declare that all experiments have been examined and approved by the appropriate ethics committee and have therefore been performed in accordance with the ethical standards laid down in the 1964 Declaration of Helsinki.

REFERENCES

1. Oral Radiology by S.C. White and M.I. Pharoah, First South Asia Edition.
2. Friedlander AH, El Saden SM, Hazboun RC, Chang TI, Wong WK, Garrett NR. Detection of carotid artery calcification on the panoramic images of post-menopausal females is significantly associated with severe abdominal aortic calcification: a risk indicator of future adverse vascular events.
3. Yoon SJ, Yoon W, Kim OS, Lee JS, Kang BC. Diagnostic accuracy of panoramic radiography in the detection of calcified carotid artery. *DentmaxillofacRadiol* 2008;37:104-8.
4. Roldan-Chicano R, Onate-Sanchez RE, Lopez-Castano F, Cabrerizo-Merino MC, Martinez-Lopez F. Panoramic radiograph as a method for detecting calcified atheroma plaques. Review of literature. *Med Oral Patol Oral Cir Bucal*. 2006;11(3):61-66.
5. Hoke M, Schmidt B, Schillinger T, et al. Evidence of carotid atherosclerosis in orthopantomograms and the risk for future cardiovascular events. *Vasa*. 2010;39(4):298–304
6. Friedlander AH, Friedlander IK. Panoramic dental radiography: an aid in detecting individuals prone to stroke. *Br Dent J*. 1996 ;181(1):23-26.
7. Ramesh A, Pabla T. Panoramic radiographs: a screening tool for calcified carotid atheromatous plaque. *J Mass Dent Soc*. 2007;56(2):20-21.
8. Almog DM, Illig KA, Elad S, Romano PR, Carter LC. Supplementary role of panoramic radiographs in the medical surveillance of a patient at risk for stroke. *Compend Contin Educ Dent*. 2005; (6):369-72.

9. Friedlander AH, Garret NR, Norman DC. The prevalence of calcified carotid artery atheromas on the panoramic radiology of patients with type 2 diabetes mellitus. *J Am Dent Assoc* 2002; 133:1516-23.
10. Cohen SN, Friedlander AH, Jolly DA, Date L. Carotid calcification on panoramic radiographs: An important marker for vascular risk. *Oral Surg Oral Med Oral Pathol Oral RadiolEndod* 2002;94:510-4.
11. Tamura T, Inui M, Nakase M, Nakamura S, Okumura K, Tagawa T. Clinicostatistical study of carotid calcification on panoramic radiographs. *Oral Dis* 2005;11:314-7.
12. Carter LC, Haller AD, Nadarajah V, Calamel AD, Aguirre A. Use of panoramic radiography among an ambulatory dental population to detect patients at risk of stroke. *J Am Dent Assoc* 1997;128:977-84
13. Pornprasertsuk-Damrongsri S, Thanakun S. Carotid artery calcification detected on panoramic radiographs in a group of Thai population. *Oral Surg Oral Med Oral Pathol Oral RadiolEndod*. 2006;101:110–115.
14. Lewis DA, Brooks SL. Carotid artery calcification in a general dental population: a retrospective study of panoramic radiographs. *Gen Dent*. 1999;47:98–103.
15. Ohba T, Takata Y, Ansai T, Morimoto Y, Tanaka T, Kito S, Awano S, Akifusa S, Takehara T. Evaluation of calcified carotid artery atheromas detected by panoramic radiograph among 80-years-olds. *Oral Surg Oral Med Oral Pathol Oral RadiolEndod*. 2003;96:647–650.
16. Ertas ET, Sisman Y. Detection of incidental carotid artery calcifications during dental examinations: panoramic radiography as an important aid in dentistry. *Oral Surg Oral Med Oral Pathol Oral RadiolEndod*. 2011;112:e11–17
17. Tofangchiha M, Foroozia M, Bakhshi M, Bashizade H. The carotid artery calcification in type II diabetic patients on panoramic radiographs: An important marker for vascular risk. *Sci Res Essays* 2011;6:6548-53.
18. Friedlander AH, Cohen SN. Panoramic radiographic atheromas portend adverse vascular events. *Oral Surg Oral Med Oral Pathol Oral RadiolEndod*. 2007;103:830–835
19. Griniatsos J, Damaskos S, Tsekouras N, Klonaris C, Georgopoulos S. Correlation of calcified carotid plaques detected by panoramic radiograph with risk factors for stroke development. *Oral Surg Oral Med Oral Pathol Oral RadiolEndod*. 2009;108:600–603.
20. Brand HS, Mekenkamp WC, Baart JA. Prevalence of carotid artery calcification on panoramic radiographs. *Ned Tijdschr Tandheelkd*. 2009;116:69–73.
21. Lee JS, Kim OS, Chung HJ, Kim YJ, Kweon SS, Lee YH, Shin MH, Yoon SJ. The prevalence and correlation of carotid artery calcification on panoramic radiographs and peripheral arterial disease in a population from the Republic of Korea: the Dong-gu study. *DentomaxillofacRadiol*. 2013;42:29725099.