

# **Esthetic rehabilitation of spaced Maxillary anterior teeth using a fully Digitized 3D guidetechnique : A Case Report**

## **Abstract**

This case report explores the successful closure of diastema spaces through the integration of digital scanners and the injection moulding technique using a flowable composite material. Digital impressions were obtained using intraoral scanners, providing precise 3D models of the patient's dentition. The digital workflow facilitated meticulous treatment planning and customization of the space closure using computer-aided design (CAD) software. A flowable composite material was selected for its adaptability and aesthetic qualities. The significance of complete digitization in the field of aesthetic dentistry, offering a highly accurate and efficient solution for diastema closure. The integration of digital scanners and injection moulding techniques allows for a minimally invasive, patient-centric approach that preserves natural tooth structure while achieving optimal aesthetic enhancement.

Keywords- Injection Moulding Technique, computer aided design(CAD)design, Composite, Diastema ,Esthetics.

## **INTRODUCTION**

Direct composite resin restorations are increasingly being used by dentists as a viable option for patients who need anterior restorative procedures. These procedures help to create a natural-looking smile with minimal wear to the dental structure. They offer satisfactory esthetic results, making them a popular choice among patients[1]. Various treatment modalities for esthetic rehabilitation exist like microabrasion, direct composite resin restorations or combination of both, indirect composites, crowns, esthetic veneers[2].

Diastema refers to the space between two teeth , which can occur for a variety of reasons and is common in the front part of the upper jaw . Diastemas have various causes, such as size anomalies, congenital tooth loss, atypical swallowing and hypertrophy of the labial frenulum, and can be treated with minimally invasive techniques

Diastemas with several causes, such as size anomalies, congenital tooth loss, atypical swallowing, and hypertrophy of the labial frenulum, can be treated with minimally invasive techniques. Direct composite restorative materials are generally cheaper, minimally invasive, easy to apply, and repairable than indirect veneers [3,4]. Since the optical (color stability) and physical properties of the direct composites have improved, the treatment method with direct composite restorative material in a single visit was preferred in this study. In direct composite restoration, restorative procedures can be performed in a short time with one-shaded composite materials and errors in color-matching are minimized[5,6,7].

In the year 2007 Coachman and Calamita[8] described Digital smile design as a multi-use conceptual tool that can support diagnostic vision, improve communication, and enhance treatment predictability, by permitting careful analysis of the patient's facial and dental characteristics that may have gone unnoticed by clinical, photographic or diagnostic cast based evaluation procedures [8,9].

DSD software also allows the clinician to educate the patients regarding the improvements that can be done. Also helps in collecting the patient's own preference and requirements, thereby making the patient a part of the decision-making process rather than just being on the receiving end [10,11].

#### Advantages of DSD

- complements psychological characteristics of the patient,
- relating patient to an emotional level,
- increasing their confidence in the process
- better acceptance of the anticipated treatment[11].

Injection moulding technique is defined as, injecting a low viscosity resin composite in a pressurised, transparent silicone index made from a diagnostic wax-up, which aim to replicate an already performed mock-up. Modern injectable resins, such as G-aenial Universal Injectable (GC), have a high filler content, wear resistance and gloss retention. The IMT has the advantage of replicating the excellent anatomy defined by a lab-made diagnostic wax-up [12,13].

Digital impressions obtained through intraoral scanners create highly accurate 3D models of the patient's oral anatomy. This eliminates the need for traditional moulding materials and provides a detailed digital representation of the patient's teeth and surrounding structures. With the digital

model at hand, dental professionals can use CAD software to design the desired prosthetic or appliance. This step allows for precise customization, ensuring a perfect fit and optimal functionality [14,15].**The purpose of this case report was to demonstrate the use of digital flow to correct anterior dental diastemas with 3D guide."**

## **CASE REPORT :**

### **CHIEF COMPLAINT**

A 34 years old male Patient reported to department of conservative dentistry and endodontics with a chief complaint of spacing in upper front tooth region and wants to get it corrected

Medical History – No relevant history

### **INTRAORAL EXAMINATION**

Midline Diastema noted along with Spacing in the anterior teeth between 13 to 23(Fig-1.a).

**Treatment plan :** Direct composite restoration using Injection Moulding Technique - 11,12,13,21,22,23 with the help of complete digital work flow

### **Requirements To Digitize the whole treatment process:**

Intraoral Scanner(Primescan )

Exocad ( designing software)

3D printer

**Procedure-** First Appointment the preoperative photographs were taken to keep as a reference. Then digital impression(Fig-1.b) of the maxillary and mandibular arch was taken using Primescan(intraoral scanner ) and exported the digital impression to lab in STL format(Fig-1.c). The shade selection was made on the same day. Patient was recalled after 3days.

The designing for space closure was done using exocad software(Fig-1.d) and discussed with the patient and any changes that patient requires. After the design was finalised by patient, the cast was 3D printed using Shining 3D uTab-Dis(3D Printer)(Fig-2). The hard splint was used to fabricate a try over 3D printed model. After the tray fabrication the margins were kept 1mm above the gingiva and fit of the tray was checked on model to check for undercut (Fig-3).

Second appointment – 3D printed model was shown to the patient to educate the patient about how the final outcome looks like, then the fit of the tray was checked on the patient mouth to check the adaptation of the tray intraorally(Fig-4.a). Once the proper fit of the tray was

confirmed the vents were created on the incisal edges of the individual tooth on the tray from canine to canine (Fig-4.b).

The treatment was started with left central incisor(21) by isolating the adjacent two teeth by Teflon (Fig-4.c), 21 was acid etched using 37% phosphoric acid., washed and air dried , bonding agent was applied on 21 and then the tray was inserted. After the fit was confirmed the A2 Shade G -Aenial universal Flo composite was injected from the cervical moving to incisal edge into the tray. After the material has fully flowed over the tray, the syringe was slowly taken out from the tray (rapid removal might cause void formation) and extra material was wiped off and light cured. Same procedure was repeated for all the teeth from canine to canine and interproximal space was confirmed using mylar strip (Fig-4.d). Very minimal finishing the polishing was required. Post operative picture was taken (Fig-5).

## DISCUSSION

Indirect restorations are more time consuming and costly. Direct composite restorations require significant chair side time, good operator skills and knowledge of the material used. Compared to freehand or indirect restorations, the IMT provides quicker, more consistent results with less adjustments required[16,17].

Advantages of Digitizing the process Chair side is Intra oral scanner has simplified the process chain between dentist and dental technician. Avoided work such as tray preparation, disinfecting, shipping of the conventional impression further preparations for the fabrication of gypsum dental casts. Major advantage of digitization are faster, reduction of possible human errors and improved accuracy. Use of designing softwares have avoided the work of mockup and have more accuracy and precision. With the help of 3D printer, confirmed design pattern will be 3D printed for the further use like explaining about the treatment outcome to the patient, preparing a tray upon 3D printed cast. The CAD-designed restoration is used to create a mould. This mould will be the template for the final restoration. The precision of the mould is crucial in achieving an accurate fit and a natural look[5].

The injection moulding technique using flowable composite offers several advantages in specific clinical situations, providing dentists with a valuable tool for certain restorative and aesthetic procedures. Flowable composites have a low viscosity, allowing them to flow easily into even the smallest spaces which enables excellent adaptation to tooth surfaces and margins, resulting in

restorations with minimal voids or gaps. The injection moulding process is typically faster than traditional layering techniques. The flowable composite can be injected directly into the mould, reducing chair time and improving overall efficiency in the dental office. The flowable nature of the composite material allows for the precise replication of natural tooth anatomy. This is particularly important when restoring anterior teeth, where aesthetics and anatomical details are critical[18,19]. When used appropriately for suitable cases, the injection moulding technique with flowable composite can provide predictable and aesthetically pleasing outcomes. Compared to some traditional layering techniques, the injection moulding technique may be less technique-sensitive.

While the injection moulding technique using flowable composite offers several advantages, it's essential to consider potential disadvantages and challenges associated with this method. Here are some drawbacks of the injection moulding technique using flowable composite: Limited Strength and Durability-making them less suitable for load-bearing areas. Flowable composites tend to exhibit more significant shrinkage during the curing process compared to conventional composites. Flowable composites may be more prone to wear over time, especially in areas with significant occlusal forces. This could lead to the need for more frequent repairs or replacements compared to restorations made from stronger composite materials. One potential drawback associated with the injection moulding technique, especially when using a monoshade or a single shade of composite material, is the challenge of achieving natural and nuanced color variations in the final restoration. This limitation becomes more prominent in cases where multiple shades are necessary to mimic the complexity of a patient's natural dentition[20].

This case was done with the help of intraoral scanner, designing software, 3D printer(complete digital workflow) which has eliminated all the lab procedure (impression making , pouring cast, mock up).With the help of designing software we are able to get accurate and predictable outcome, which is difficult to get with manual mockup.And to make it more economical instead of using clear silicon index, hard splint tray was used which was able to replicate all the minor detail (contours, curvatures) with minimal cost.

## **Conclusion**

The fusion of Injection Molding and Digital Dentistry offers high levels of precision, customization and efficiency. As technology continues to advance, the collaboration between

traditional manufacturing methods and digital tools will undoubtedly shape the future of dental care. This will provide patients with improved solutions and dental professionals with innovative ways to achieve optimal oral health outcomes.

#### Ethical Approval:

As per international standard or university standards written ethical approval has been collected and preserved by the author(s).

#### Consent

Patient was explained about the procedure and written consent was taken.

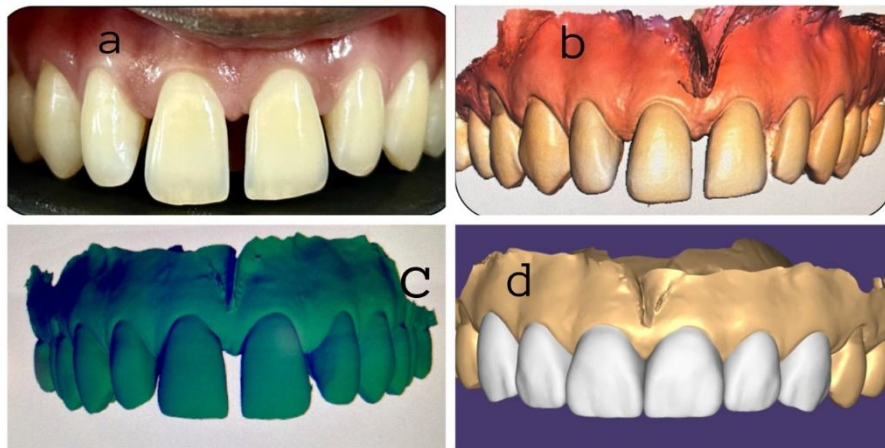
#### References

1. Jafri Z, Ahmad N, Sawai M, Sultan N, Bhardwaj A. Digital Smile Design-An innovative tool in aesthetic dentistry. J Oral BiolCraniofac Res. 2020 Apr-Jun;10(2)
2. Nahsan FP, Mondelli RF, Franco EB, Naufel FS, Ueda JK, Schmitt VL, Baseggio W. Clinical strategies for esthetic excellence in anterior tooth restorations: understanding color and composite resin selection. Journal of Applied Oral Science. 2012;20:151-6.
3. G-ænial® Universal Injectable from GC TECHNICAL MANUAL Version 1.0 – October 2018
4. Ranka S, Rao AS, et al Comparative Evaluation of Two Different Fiber-Reinforced Composite Materials in Class 1 Post-Endodontic Restorations in Molars-A Randomized Clinical Study. Materials (Basel). 2022 Nov 7;15(21):7858
5. Thomas PA, Krishnamoorthi D, Mohan J, Raju R, Rajajayam S, Venkatesan S. Digital Smile Design. J Pharm Bioallied Sci. 2022 Jul;14(Suppl 1):S43-S49
6. Mennatallah N Salem, Shereen Hafez. Aesthetic Management of Erosive Tooth Wear in a Young Egyptian Swimmer: A Case Report , Clinical, Cosmetic and Investigational Dentistry, 2021:13 201–209
7. Shamir B Mehta, Selar Francis and Subir Banerji A Guided, Conservative Approach for the Management of LocalizedMandibular Anterior Tooth Wear, RestorativeDentistry. 2016; 43: 106–112
8. Thomas PA, Krishnamoorthi D, Mohan J, Raju R, Rajajayam S, Venkatesan S. Digital Smile Design. J Pharm Bioallied Sci. 2022 Jul;14(Suppl 1):S43-S49.

9.


10. Geštakovski D. The injectable composite resin technique: minimally invasive reconstruction of esthetics and function. *Quintessence Int.* 2019 Oct;50(9):712-20.
11. Zanardi PR, Zanardi RL, Stegun RC, Sesma N, Costa BN, Laganá DC. The use of the digital smile design concept as an auxiliary tool in aesthetic rehabilitation: a case report. *The open dentistry journal.* 2016;10:28.
12. Stanley M, Paz AG, Miguel I, Coachman C. Fully digital workflow, integrating dental scan, smile design and CAD-CAM: case report. *BMC oral health.* 2018 Dec;18(1):1-8.
13. Jafri Z, Ahmad N, Sawai M, Sultan N, Bhardwaj A. Digital Smile Design-An innovative tool in aesthetic dentistry. *Journal of oral biology and craniofacial research.* 2020 Apr 1;10(2):194-8.
14. Zanardi PR, Zanardi RL, Stegun RC, Sesma N, Costa BN, Laganá DC. The use of the digital smile design concept as an auxiliary tool in aesthetic rehabilitation: a case report. *The open dentistry journal.* 2016;10:28.
15. WidyaNugrohowati C, Hadriyanto W, Nugraheni T. Direct composite resin restoration of anterior maxillary teeth and esthetic smile design: a case report. *Journal of Dentistry Indonesia.* 2020;27(2):103-8.
16. Wahbi MA, Al Sharief HS, Tayeb H, Bokhari A. Minimally invasive use of coloured composite resin in aesthetic restoration of periodontially involved teeth: Case report. *The Saudi dental journal.* 2013 Apr 1;25(2):83-9.
17. Coachman C, De Arbeloa L, Mahn G, Sulaiman TA, Mahn E. An improved direct injection technique with flowable composites. A digital workflow case report. *Operative Dentistry.* 2020 May 1;45(3):235-42.
18. Hosaka K, Tichy A, Yamauti M, Watanabe K, Kamoi K, Yonekura K, Foxton R, Nakajima M. Digitally Guided Direct Composite Injection Technique with a Bi-layer Clear Mini-Index for the Management of Extensive Occlusal Caries in a Pediatric Patient: A Case Report. *The Journal of Adhesive Dentistry.* 2023 Aug 8;25:211-7.
19. Tong KW, Kwong CK, Chan CY. Initial process-parameters setting of transfer moulding in microchip encapsulation: a case-based reasoning approach. *Journal of Materials Processing Technology.* 2001 Jun 15;113(1-3):432-8.

20. Sabatini C, GUZMÁN- ARMSTRONG SA. A conservative treatment for amelogenesis imperfecta with direct resin composite restorations: a case report. Journal of esthetic and restorative dentistry. 2009 Jun;21(3):161-9.
21. Muhamad AH. Restoring Fractured Anterior Tooth Using Direct Composite Restoration: A Case Report. Global Journal of Dental Sciences1. 2019;1.
22. Soliman S, Meyer-Marcotty P, Hahn B, Halbleib K, Krastl G. Treatment of an Adolescent Patient with Dentinogenesis Imperfecta Using Indirect Composite Restorations-A Case Report and Literature Review. Journal of Adhesive Dentistry. 2018 Jul 1;20(4).

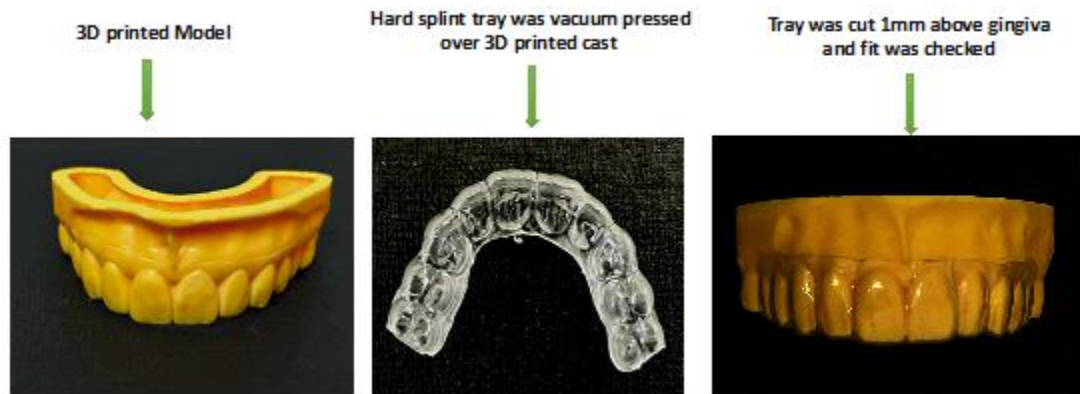

**Fig 1- a)Midline Diastema with Spacing in anterior teeth, b)Digital impression made using PRIMESCAN , c) STL format of the digital impression, d)Designing was done using exocad software**

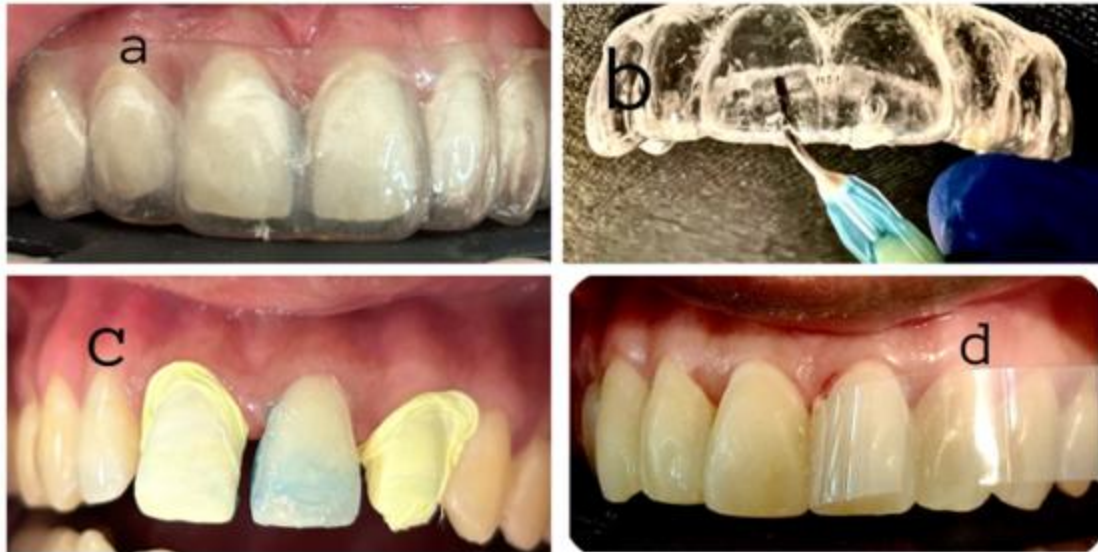



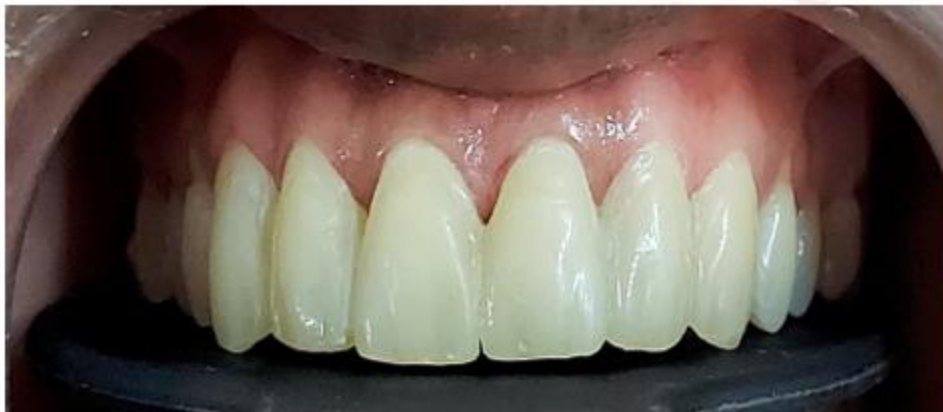**Fig 2-** Finalized model was 3D printed and cured



**Fig 3-**shows 3D printed model, hard splint tray , fit of the tray was check on 3D printed model and cut 1mm above the gingiva.



**Fig 4-** a)Tray fit was checked intraorally, b)Vents made at the incisal edges on the tray, c)Each tooth was prepared separately (isolation of adjacent teeth using Teflon Etching , bonding and injecting the composite), d) Inter proximal space was confirmed using Mylar strip



**Fig 5-** post operative picture after completion of injection moulding.