

## **Case study**

### Cryptogenic stroke with a patent foramen ovale in a patient with pulmonary embolism and thrombophilia: a case-based discussion

#### Abstract :

The patent foramen ovale (PFO) is a common abnormality that is often associated with cryptogenic stroke in young people. The management of PFO requires endovascular closure which prevents recurrence better than antithrombotic treatment. In the presence of concomitant thrombophilia, the risk of recurrence of stroke after closure of the FOP is increased, and need to institute antithrombotic therapy. The choice and duration of the treatment are controversial. Our study focuses on a 37-year-old patient admitted for ischemic vascular accident in whom a patent foramen ovale was found with an interatrial septal aneurysm on a ground of thrombophilia associated with a left pulmonary embolism and an occlusion. total left internal carotid artery.

Since at present, there is no optimal therapeutic strategy for these patients, the indications must be considered on an individual basis. The aim of the clinical case is to relate our experience in the management of cryptogenic stroke associated with FOP on a ground of thrombophilia.

#### Keys words :

cryptogenic stroke , patent foramen ovale , hypercoagulability, thrombophilia

#### Introduction

Patent foramen ovale (PFO) is a congenital hole between the right and the left atria. In 15-30% of the population PFOs tend to persist through adulthood. In the majority of the population PFOs remain asymptomatic, but clinical manifestations are believed to be associated with PFOs, such as cryptogenic stroke, especially in patients with atrial fibrillation [8-10]. The increased risk of ischemic stroke has been reported in several studies in patients with PFOs and acute pulmonary embolism. The risk of ischemic stroke is shown to be higher in patients with PE and PFO compared to those without PFO, as reported by several studies with small number of subjects [11]. The present case study highlights the Cryptogenic stroke with a patent foramen ovale in a patient with pulmonary embolism and thrombophilia.

#### Clinical case :

A 37-year-old patient with no particular pathological history presents for left hemiplegia with dysarthria and exertional dyspnea evolving for 2 months.

The clinical examination found a patient with a tachycardia at 114 bpm with no other associated abnormalities. Cerebral magnetic resonance imaging objectified a deep right Sylvian DALY with signs of hemorrhagic infarction (1). The electrocardiogram showed sinus tachycardia with an S1Q3 pattern and negative T waves anteriorly.

Transthoracic ultrasound revealed an aspect of acute cor pulmonale with a right ventricle dilated at 49 mm and systemic pulmonary arterial pressures at 73 mmHg (2). Pulmonary CT angiography confirmed left pulmonary embolism (3). The venous echo-Doppler of the lower limbs did not objectify deep vein thrombosis.

Transesophageal ultrasound revealed a PFO with an interatrial septum aneurysm (ASIA) of 16x10 mm (4). CT angiography of the supra-aortic trunks showed total occlusion of the left IC without dissection (5).

The biological assessment found a protein C and antithrombin 3 deficiency.

The decision was to put the patient on unfractionated heparin and then on anticoagulant treatment based on acenocoumarol.

## Discussion

The management of patients with PFO-related stroke is complex. The choice of a treatment is based on the following criteria: the anatomical characteristics of the severity of the PFO, a high risk of stroke recurrence on the RoPe score and an unfavorable benefit/risk ratio of the antithrombotic treatment [2]. Recent trials demonstrated that closure of high-risk PFO can reduce the risk of recurrent stroke compared to antithrombotic therapy [3].

Few data are available on the impact of thrombophilia in patients with cryptogenic stroke [4]. Current studies demonstrate an increased risk of cryptogenic stroke in patients with thrombophilia and FOP [5]. In our case, the deficiency in antithrombin 3 and in protein C constitutes a non-negligible risk factor.

The origin of the stroke of the patient arises. The first hypothesis is the increased risk of venous thrombosis with paradoxical embolism, in front of the FOP/ASIA association on thrombophilia. Closing the PFO is then an optimal choice. In our case, the high pressures of the right cavities secondary to the massive left pulmonary embolism mean that closure of the PFO cannot be considered at this phase.

The second hypothesis is that her embolism was purely of arterial origin, given the total occlusion of the left CI that she presents, or that her neurological lesion was intracerebral. Closing the PFO would then provide no additional benefit.

Some studies recommend that antithrombotic treatment, despite PFO closure, should be considered on an individual basis [4]. There is a significant reduction in stroke recurrence in patients on anticoagulants compared to antiplatelets [6]. The American Heart Association recommends anticoagulant therapy for high-risk patients with coexisting venous thrombosis [7].

## Conclusion

For patients with thrombophilia, with an indication for anticoagulation, closure of the PFO seems reasonable but prolonged antithrombotic treatment remains a subject of debate.

## References

- [1] Hart RG, Diener HC, Coutts SB, Easton JD, Granger CB, O'Donnell MJ, et al; Cryptogenic Stroke/ESUS International Working Group. Embolic strokes of undetermined source: the case for a new clinical construct. *Lancet Neurol*. 2014 Apr;13(4):429-38.
- [2] Abdelghani M, El-Shedoudy SAO, Nassif M, Bouma BJ, de Winter RJ. Management of Patients with Patent Foramen Ovale and Cryptogenic Stroke: An Update. *Cardiology*. 2019;143(1):62-72.
- [3] Garg A, Thawabi M, Rout A, Sossou C, Cohen M, Kostis JB. Recurrent Stroke Reduction with Patent Foramen Ovale Closure versus Medical Therapy Based on Patent Foramen Ovale Characteristics: A Meta-Analysis of Randomized Controlled Trials. *Cardiology*. 2019;144(1-2):40-49.
- [4] Hviid CVB, Simonsen CZ, Hvas AM. Recurrence Risk in Patients with Cryptogenic Stroke, Patent Foramen Ovale, and Thrombophilia: A Systematic Review and Meta-Analysis. *Thromb Haemost*. 2019 Nov;119(11):1839-1848.
- [5] Gerstein NS, Clegg SD, Levin DB, Fish AC, Tolstrup K, Nakanishi K, et al. A Case-Based Discussion on the Management of Cryptogenic Stroke and Patent Foramen Ovale in the Patient With a Hypercoagulable Disorder. *J Cardiothorac Vasc Anesth*. 2019 Dec;33(12):3476-3485.
- [6] Sagris D, Georgiopoulos G, Perlepe K, Pateras K, Korompoki E, Makaritsis K, et al. Antithrombotic Treatment in Cryptogenic Stroke Patients With Patent Foramen Ovale: Systematic Review and Meta-Analysis. *Stroke*. 2019 Nov;50(11):3135-3140.
- [7] Kernan WN, Ovbiagele B, Black HR, et al. Guidelines for the prevention of stroke in patients with stroke and transient ischemic attack. A guideline for healthcare

professionals from the American Heart Association/American Stroke Association. Stroke 2014;45:2160–236.

[8] Hara H, Virmani R, Ladich E, Mackey-Bojack S, Titus J, Reisman M, Gray W. et al. Patent foramen ovale: current pathology, pathophysiology, and clinical status. J Am Coll Cardiol. 2005;46(9):1768–1776. doi: 10.1016/j.jacc.2005.08.038

[9] Wu LA, Malouf JF, Dearani JA, Hagler DJ, Reeder GS, Petty GW, Khandheria BK. Patent foramen ovale in cryptogenic stroke: current understanding and management options. Arch Intern Med. 2004;164(9):950–956. doi: 10.1001/archinte.164.9.950

[10] Kerut EK, Norfleet WT, Plotnick GD, Giles TD. Patent foramen ovale: a review of associated conditions and the impact of physiological size. J Am Coll Cardiol. 2001;38(3):613–623. doi: 10.1016/S0735-1097(01)01427-9.

[11] Roy S, Le H, Balogun A, Caskey E, Tessitore T, Kota R, Hejirika J, Yu S, Nguyen L, Lazo AL, Yard C. Risk of Stroke in Patients With Patent Foramen Ovale Who Had Pulmonary Embolism. Journal of Clinical Medicine Research. 2020 Mar;12(3):190.

artwork

fig. (1): Brain MRI

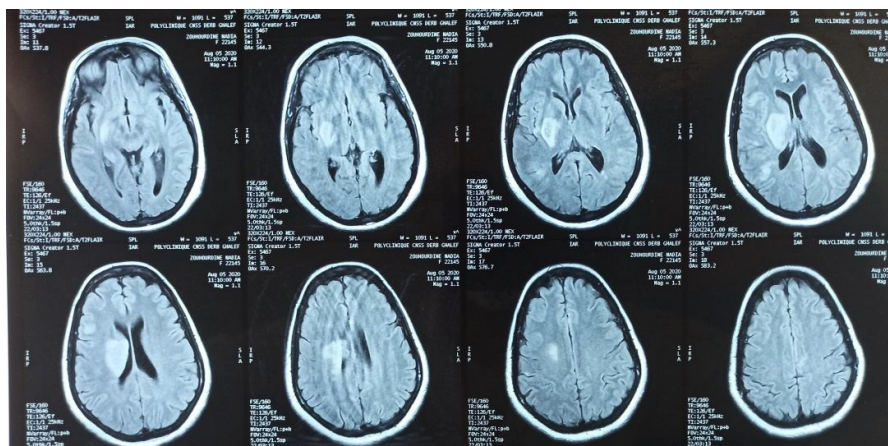


fig .(2) :ETT

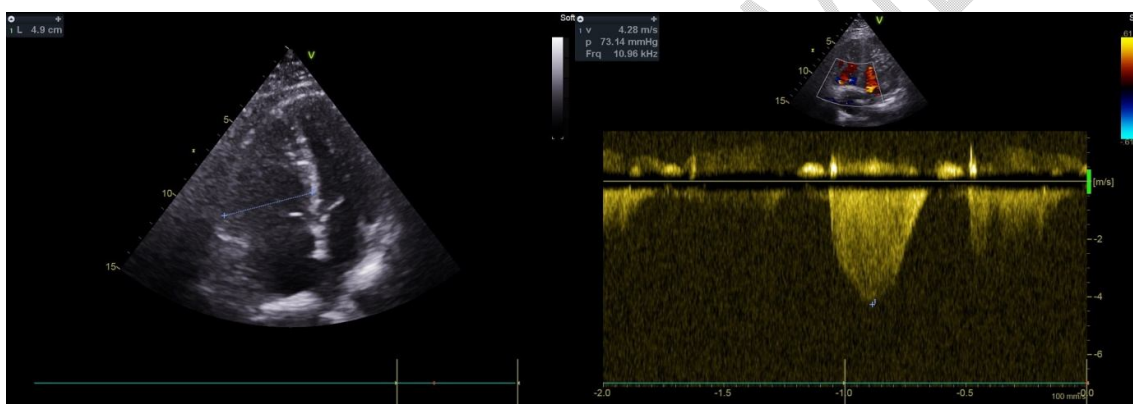


fig .(3): Chest CT angiography



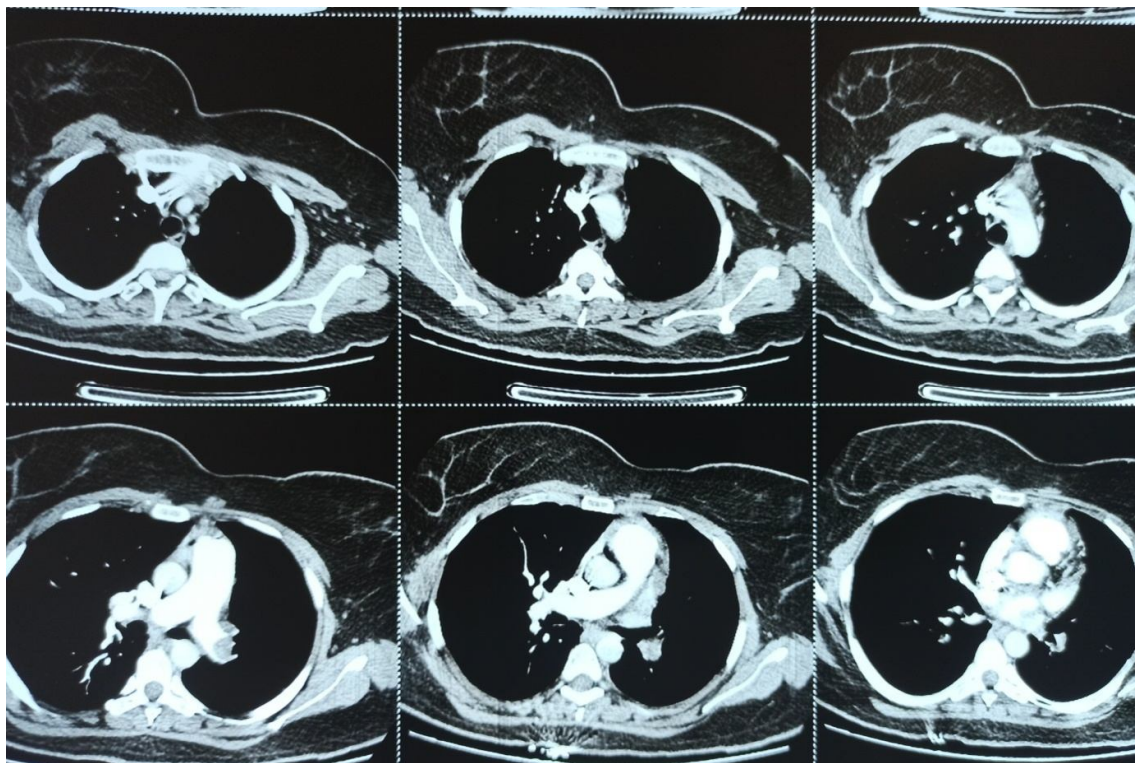


fig .(4): ETO

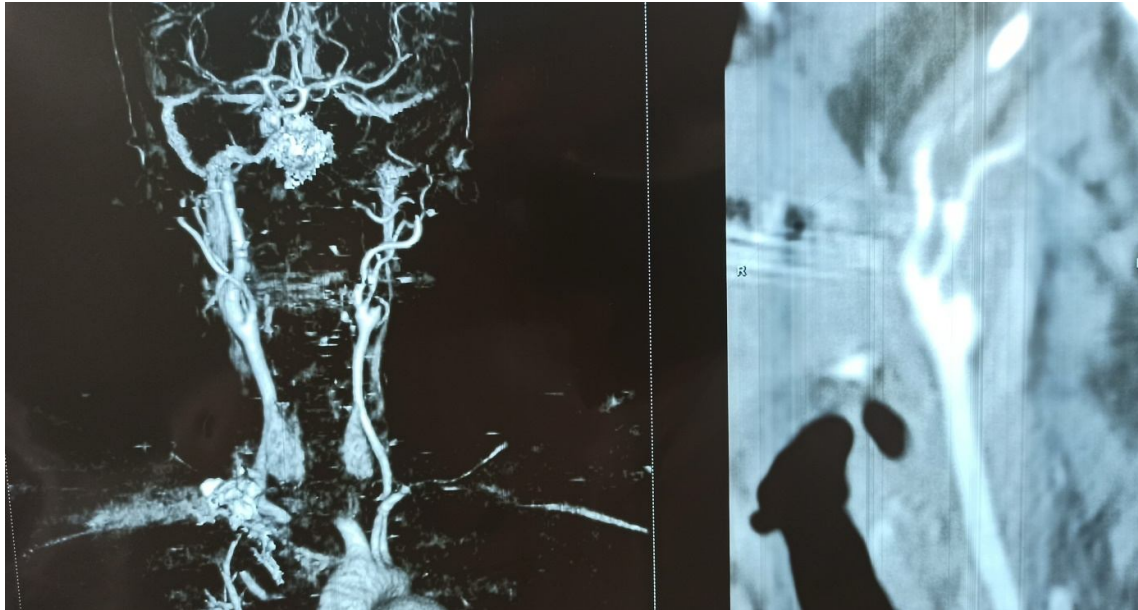
a: FOP

b: Bubble test

c: ASIA

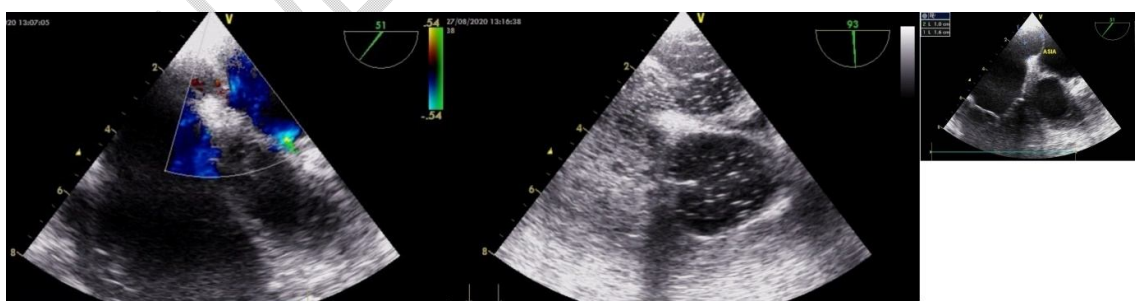

fig .(5): CT angiography of the supra-aortic trunks



"All authors declare that written informed consent has been obtained from the patient (or other approved parties) for publication of this case report and accompanying images. A copy of the written consent is available for review. by the editorial board/editor/editorial board members of this journal."