

## Post-traumatic acute disseminated encephalomyelitis (ADEM): a case report

### Abstract

We report the case of a child who developed ADEM after a trauma at home. This is a 25-month-old child, born of a non-consanguineous marriage with no perinatal history or any recent viral infections, with good psychomotor and intellectual development. Diagnosis of encephalopathy can be difficult in children, with nonspecific, subtle, and transient symptoms, such as drowsiness or irritability, that can be easily overlooked, especially in the emergency department. The best available diagnostic tool is based on clinical and radiological findings. MRI could be useful for a precise and early diagnosis necessary to solve some unanswered questions.

Keywords: psychomotor, acute disseminated encephalomyelitis, radiological findings, monophasic immune-mediated inflammatory disease

### I-Introduction

The term acute disseminated encephalomyelitis (ADEM) was first used in 1950 as a rare monophasic immune-mediated inflammatory disease of the CNS that is potentially functionally and vitally serious (1).

It is a curable encephalomyelitis, with rapid onset and combination of multifocal neurologic symptoms (2).

The diagnosis of ADEM requires two essential elements: typical clinical presentation and magnetic resonance imaging (MRI) findings (3).

Its association with various infections is well described, less often with a vaccination such as polio and rarely with trauma, but can also occur without any cause (4-6).

We report the case of a child who developed ADEM after a trauma at home.

### II – Case report :

This is a 25-month-old child, born of a non-consanguineous marriage with no perinatal history or any recent viral infections, with good psychomotor and intellectual development. He presented **with** walking disorders 48 hours after a fall from a staircase with a cranial impact point.

On examination he had cerebellar ataxia, bidirectional horizontal nystagmus, divergent strabismus of the right eye, abnormal head movements and hypersialorrhea.

**Both the blood test and the cephalospinal fluid analysis were normal.**

Brain MRI showed (Fig.1) inflammatory demyelinating lesions of the supra- and subtentorial white matter, located in the juxtaventricular and juxtacortical regions.

Large areas of hyperintense signal in axial sections, there is an associated right thalamic lesion. The associated involvement of the basal ganglia points to an acute disseminated encephalomyelitis.

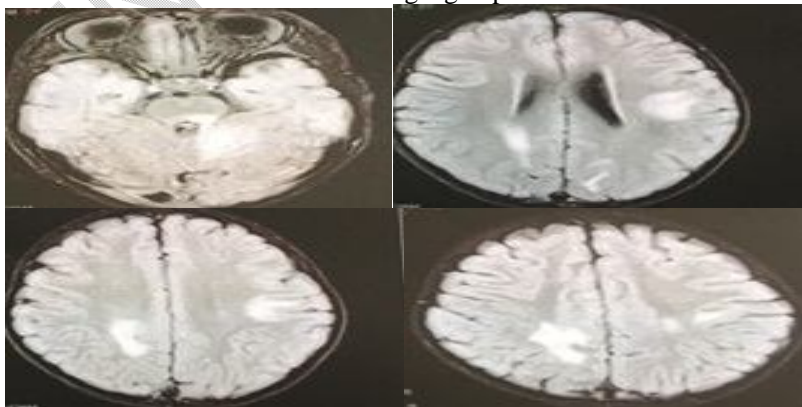


Fig 1: MRI scan report

He was treated with a bolus of intravenous methylprednisolone (30mg/kg/d for 3 days) followed by oral corticosteroids for one month with complete recovery of the motor and neurological deficit.

### **III. DISCUSSION**

We have described an atypical case of ADEM that initially manifested after head trauma. This case report suggests a possible new association between the two, which should be considered in the management of patients with any kind of head trauma, whether minimal or severe, especially in the presence of neurological or neuropsychiatric symptoms.

It can affect both adults and children (7). The age of presentation is usually between 5 and 8 years in children described in association with rabies and smallpox vaccines.

Krupp et al. 2013 updated consensus **criteria** for ADEM (which remains a diagnosis of exclusion) **requires** all of the following:

- First event of encephalopathy plus multifocal neurologic deficits.
- Presumed inflammatory demyelinating cause.
- Encephalopathy (altered consciousness or behavior unexplained by fever, systemic illness, or post-critical symptoms).
- Brain MRI abnormalities consistent with acute phase (3 months) demyelination.
- Typical brain MRI lesions:
- Diffuse, poorly delineated, large (>1 to 2 cm) lesions.
- Involving mostly cerebral white matter.
- T1 hypointense lesions should not be observed.
- Deep lesions of the gray matter (e.g., thalamus or basal ganglia) may be present, especially in children (A.Rovira et al)

This frequency in children was explained by the greater frequency of vaccinations and exposure to infectious antigens (8,9)

In the definition and **the pathogenesis** of ADEM, infections and vaccination seem to be the exclusive triggers of the condition. This case report is a call to investigate whether ADEM could indeed occur "as a result of trauma."

This could contribute to early diagnosis and management of this condition, which is not always easy to treat and can sometimes be fatal.

Post-traumatic ADEM is rarely reported in the literature. Neuroinflammation is well established as a key secondary injury mechanism after traumatic brain injury, and it has long been considered a contributor to the damage following brain injury (10)

**The association** with polio vaccine has been reported [11] other explanation of its occurrence post infectious through the involvement of T cells cross-reacting with Myelin basic protein antigens include HHV-6 (Tejada-Simon et al., 2003), coronavirus (Talbot et al., 1996), influenza virus hemagglutinin (Markovic-Plese et al., 2005) and EBV (Lang et al., 2002) Viral or bacterial epitopes ex urinary (12) resembling myelin antigens **with** ability to activate myelin-reactive T-cell clones by molecular mimicry (Wucherpfennig et al) .

It has also been described in association with the use of certain drugs such as sulfonamides and para-amino-salicylic acid/streptomycin (T. Michelle et al)

MRI is extremely important in establishing the diagnosis of **EMAD**.

Lesions are usually large, patchy, but different sizes can be identified in the same patient (from a few millimeters to several centimeters). In large lesions with a tumor-like appearance, mass effect is usually mild or absent. Ovoid lesions (Dawson's fingers) are much less frequent. (A.Rovira)

Clinical symptoms (convulsions, headache, fever, focal neurological deficits, cerebellar syndrome, consciousness disorders, transverse myelitis) (L.Dietemann et al ) **appear usually one to three weeks after a vaccination** [13,14]

(C. Hemingway et al) reports that the initial symptoms of ADEM may include lethargy, fever, headache, vomiting, meningeal signs and seizures, including status epilepticus. Encephalopathy ranging from behavioral changes and persistent irritability to coma. Focal neurologic deficits may be difficult to determine in the obnoxious or very young child, but common neurologic signs of ADEM include visual loss, cranial neuropathies, ataxia, and motor and sensory deficits, as well as bladder, bowel, and bladder dysfunction with concomitant demyelination of the spinal cord

The clinical course is usually rapidly progressive over days.

Intensive care unit admission may be required, especially for patients with brainstem dysfunction or high intracranial hypertension

Diagnosis of encephalopathy can be difficult in children, with nonspecific, subtle, and transient symptoms, such as drowsiness or irritability, that can be easily overlooked, especially in the emergency department

ADEM lacks a specific biological marker, and diagnosis depends upon retaining a high index of clinical suspicion and always considering the condition in differential diagnoses [15],

Post-traumatic ADEM is rarely reported in the literature, it has long been considered as contributing to the secondary damage of brain trauma, although 'Irani,D et al' mentioned that ADEM could occur "in the aftermath of a trauma"(16)

Brain CT may be normal or show hypodense areas.

MRI visualizes multiple hyperintense patches of proton density in T2 and FLAIR in the supratentorial white matter, brainstem and cerebellum, often associated with localizations in the brain.

The association with lesions of the basal ganglia, especially the thalamus, is an argument in favor of ADEM, but the preservation of the periventricular white matter rather points to ADEM [17]

MRI abnormalities sometimes appear delayed compared to the first clinical signs and these same abnormalities may still increase, while the clinical picture is regressing [18].

In case of a single lesion with mass effect, the problem of differential diagnosis with a tumor process or an abscess arises [19,20].

There is increasing evidence of reduced mortality and improved outcome in patients treated with high-dose intravenous corticosteroids, IVIG [21].

Therapeutic approaches for ADEM include steroids, IV immunoglobulin (IVIG) or plasmapheresis.

High-dose steroid therapy is recommended in the form of IV methylprednisolone (10-30 mg/kg/day) or dexamethasone (1 mg/kg) for 3 to 5 days.

Then gradually tapers the oral steroid dose over 4 to 6 weeks.

Recovery is reported in 50-80% of patients if treatment is continued with reduction of oral steroids. IVIG should be used at a dose of 1-2 g/kg as a single dose or over 3-5 days. IVIG is recommended if steroid therapy fails or if demyelination recurs. In a small number of case series, the use of plasma exchange has been reported for children diagnosed with ADEM.

#### **IV. Conclusion:**

There appears to be a common pathway by which the brain responds to aggression, whether it be physical trauma or infection. Whether this can lead to ADEM is a question to be resolved by further study. A single case report can only introduce the subject, especially in the face of the near absence of diagnostic tools in developing countries and the absence of studies.

The best available diagnostic tool is based on clinical and radiological findings. MRI could be useful for a precise and early diagnosis necessary to solve some unanswered questions

#### **Bibliography :**

1. Van Bogaert L. Post-infectious encephalomyelitis and multiple sclerosis, the significance of perivenous encephalomyelitis. J Neuropathol Exp Neurol 1950, 9(3):219-49.
- 2- Cheryl. H. acute disseminated encephalomyelitis. in : Robert M. Kliegman, MD éditeurs. Nelson textbook of pediatrics 20em. Philadelphia : Elsevier ; 2015.p. 3196-3209.
- 3-Bisker Kassif, et al. Acute disseminated encephalomyelitis in children - clinical and MRI decision making in the emergency department American Journal of Emergency Medicine 2019 Févr ;37: 2004-2007.
4. Allen SH, Malik O, Lipman MC, Johnson MA, Wilson MA. Acute demyelinating encephalomyelitis (ADEM) in a patient with HIV infection. The journal of infection 2002; 45(1); 62-4.

5. Hagiwara H, Sakamoto S, Katsumata T, Katayama Y. Acute disseminated encephalomyelitis developed after mycoplasma pneumonia infection complicating subclinical measles infection. *Intern Med* 2009;48(6):479–83.
- 6- Ozawa H, Noma S, Yoshida Y, Sekine H, Hashimoto T. Acute disseminated encephalomyelitis associated with poliomyelitis vaccine. *Pediatr Neurol* 2000; 23(2): 177–9.
- 7- Gray MP, Gorelik MH. Acute disseminated encephalomyelitis. *Pediatr Emerg Care* 2016;32(6):395–400.
- 8- Apak RA, Kose G, Anlar B, Turanli G, Topaloglu H, Ozdirim E. Acute disseminated encephalomyelitis in childhood: report of 10 cases. *J Child Neurol* 1999;14:198–201.
- 9- Leake JA, Albani S, Kao AS, Senac MO, Billman GF, Nespeca MP, et al. Acute disseminated encephalomyelitis in childhood: epidemiologic, clinical and laboratory features. *Pediatr Infect Dis J* 2004;23:756–64.
- 10- Kumar A, Loane DJ. Neuroinflammation after traumatic brain injury: opportunities for therapeutic intervention. *Brain Behav Immun* 2012; 26:1191-1201.
- 11- Ozawa H, Noma S, Yoshida Y, Sekine H, Hashimoto T. Acute disseminated encephalomyelitis associated with poliomyelitis vaccine. *Pediatr Neurol* 2000; 23(2): 177–9.
- 12- Panicker JN, Nagaraja D, Koor JM, et al: Lower urinary tract dysfunction in acute disseminated encephalomyelitis, *Mult Scler* 15(9):1118–1122, 2009.
- 13- Houeto JL, Gout O. Manifestations neurologiques des infections. *Encycl Med Chir (Elsevier, Paris), Maladies infectieuses*, 14-003-A-60, Neurologie, 17-049-A-10, 1999, 10 p.
- 15- Giri PP, Bhattacharya S, Das D, Mukhopadhyaya S. Acute disseminated encephalomyelitis: a clinical and neuroradiological profile of pediatric patients. *Neurol India* 2016 Nov-Dec;64(6):1187–92.
- 16- Irani D. Neuroimmunological lessons learned from acute disseminated encephalomyelopathy. *Transverse Myelitis Association*, 2006, volume 1, article 11. Online: <http://www.myelitis.org/newsletters/j1/journal-1-11.htm>, last accessed August 18, 2012.
- 17- Alper G, Heyman R, Wang L. Multiple sclerosis and acute disseminated encephalomyelitis diagnosed in children after longterm follow-up : comparison of presenting features. *Dev Med Child Neurol* 2009 ; 51 : 480–6.
- 18 - Honkaniemi J, Dastidar P, Kahara V, Haapasalo H. Delayed MR imaging changes in acute disseminated encephalomyelitis. *AJNR Am J Neuroradiol* 2001 ; 22 : 1117–24
- 19 -Firat AK, Karaka ? HM, Yakinici C et al. An unusual case of acute disseminated encephalomyelitis confined to brainstem. *Magn Reson Imaging* 2004 ; 22 : 1329–32.
- 20- Miller DH, Scaravilli F, Thomas DC et al. Acute disseminated encephalomyelitis presenting as a solitary brainstem mass. *J Neurol Neurosurg Psychiatry* 1993 ; 56 : 920–2.
- 21- Alexander M, Murthy JM. Acute disseminated encephalomyelitis: treatment guidelines. *Ann Indian Acad Neurol* 2011;14(Suppl 1):S60–4.