

## **Case study**

### **Nasopharyngeal Carcinoma with an Unusual Metastatic Presentation**

#### **Abstract:-**

Nasopharyngeal carcinoma usually presents with regional lymphadenopathy and involvement of lymph nodes follows a particular pattern. Parotid lymph node involvement is a rare phenomenon in nasopharyngeal carcinoma. The occurrence of parotid lymph node involvement has been reported in various studies and is approximately 1%. Here we present a case of a 55-year-old male, a case of nasopharyngeal carcinoma whose nasopharyngeal biopsy and scans were negative. Patient had recurrent level II node which was subjected to fine needle aspiration cytology(FNAC) and trucut biopsy which was suggestive of basal cell adenocarcinoma features favouring salivary gland primary. The patient underwent left-sided parotidectomy with lymph node dissection. On examination of the specimen one lymph node was positive for p16 and p40 which was suggestive of Epstein Barr aetiology. Then Epstein-Barr encoded RNA in situ hybridization( EBER ISH) was done which was in favour of Epstein Barr etiology. The patient was treated as a case of nasopharyngeal carcinoma with Epstein Barr virus( EBV) positive metastatic neck node. The patient then received external beam radiotherapy concurrent with cisplatin and is on follow up and doing well.

Keywords: Nasopharyngeal carcinoma, Parotid gland metastasis, Epstein barr virus , EBER ISH

**Introduction:** Nasopharyngeal carcinoma has a high predilection for regional lymph node metastasis, up to 85% of cases present with lymphadenopathy at diagnosis<sup>(1)</sup> The pattern of nodal metastasis in nasopharyngeal carcinoma follows an orderly spread down the neck with infrequent node skipping; the most commonly involved regions include the retropharyngeal space, levels II, III, IV and V, followed by levels Ib and the supraclavicular nodes<sup>(1,2,3,4,5,6)</sup>.

The parotid lymph nodes, classified as level VIII in the latest 'International Consensus Guidelines for nodal levels'<sup>(7)</sup>, are also at risk of harbouring metastasis from the nasopharynx. The occurrence of parotid lymph node metastasis has been reported in several studies and is approximately 1%<sup>(3,4,5,7,11,12)</sup>, the prognostic significance and clinical staging system for parotid lymph nodes metastasis have not been investigated in nasopharyngeal carcinoma due to the low incidence of parotid lymph node involvement.

Neck lymph node metastasis from occult primary constitutes about 5%-10% of all patients<sup>(8)</sup> In many instances neck node metastasis is the only manifestation of this disease. An endoscopic examination or biopsy of the nasopharynx often fails to detect the primary because of submucosal and infiltrative nature of nasopharyngeal carcinoma. This difficulty in diagnosis of primary therapy may result in suboptimal therapy.

The strong association of nasopharyngeal carcinoma with the Epstein Barr virus is well documented<sup>(9)</sup>. The significant relationship between the presence of EBV in neck metastasis and nasopharyngeal carcinoma has been shown by in situ hybridization and the polymerase chain reaction<sup>(10)</sup>. Various studies have tested the efficacy of the Epstein-Barr in situ hybridization (EBER-ISH) technique in identifying the nasopharyngeal histogenesis of neck masses of unknown primary tumours.<sup>(10)</sup> In this case, we also diagnosed the patient with unknown primary using Epstein-Barr encoding region in situ hybridization(EBER -ISH).

### **Case presentation:-**

55 years old male presented with swelling left upper side upper neck (level II node) for last 3 years. The patient underwent excision biopsy of the node which revealed basal cell adenocarcinoma with lymphocytic infiltration of the submandibular gland. The Patient then developed recurrent swelling at the same site after one year. Fine needle aspiration cytology(FNAC) was done which was suggestive of lymphocytic infiltration of submandibular gland. The oral examination was normal. MRI neck was suggestive of an enlarged 2.5 X1.2 cm left level II node, a few subcentimetric level Ib nodes which likely were inflammatory. An image-guided true cut biopsy from the left level II node was suggestive of poorly differentiated carcinoma and IHC markers CK, P40 and c kit were positive, p16 was negative which were suggestive of metastatic basal cell adenocarcinoma favouring a salivary gland primary. PETCT was suggestive of mildly active nodular lesion(2.3x1.0 cm, Suv max 2.1) near inferior angle of left parotid and along lateral surface of left sternocleidomastoid muscle with preserved fat plane. Lesion was closely abutting retromandibular vein, rest was normal. The patient underwent left-sided parotidectomy with ipsilateral lymph node dissection (levels Ia and V). **Histopathology was suggestive of metastatic nasopharyngeal carcinoma** and IHC markers were positive for p16 and P40 while negative for TTF1, PAX8 and GATA 3. Tumour cells were positive for EBER – ISH expression. Nasopharyngeal biopsy was normal. The patient then came to our hospital. The case was discussed with the operating surgeon who was of opinion that in view of EBV positive node with occult primary, nasopharyngeal carcinoma is a strong clinical possibility. PET CT and MRI too were unremarkable for nasopharyngeal carcinoma, but literature is divided in this case as 15-20% of primary salivary gland tumours are EBV positive. The case was discussed in detail with patients and patients' proxies regarding the clinical scenario and treatment option. Then review biopsy of the initial excised node was done which was suggestive of that there was no evidence of native salivary gland in the specimen. The case was then discussed with reporting pathologist who was of opinion that the lesion in the parotid is a node –an Intra parotid node well encapsulated. Presumably, very high likelihood of an nasopharyngeal carcinoma primary, so in

this case, it was decided to treat this patient as a case of nasopharyngeal carcinoma. Issues faced while treating were patient had been subjected to neck dissection on one side IB-IV. All nodes were negative except level II.so radiation doses were de-escalated because of the possibility of toxicity.

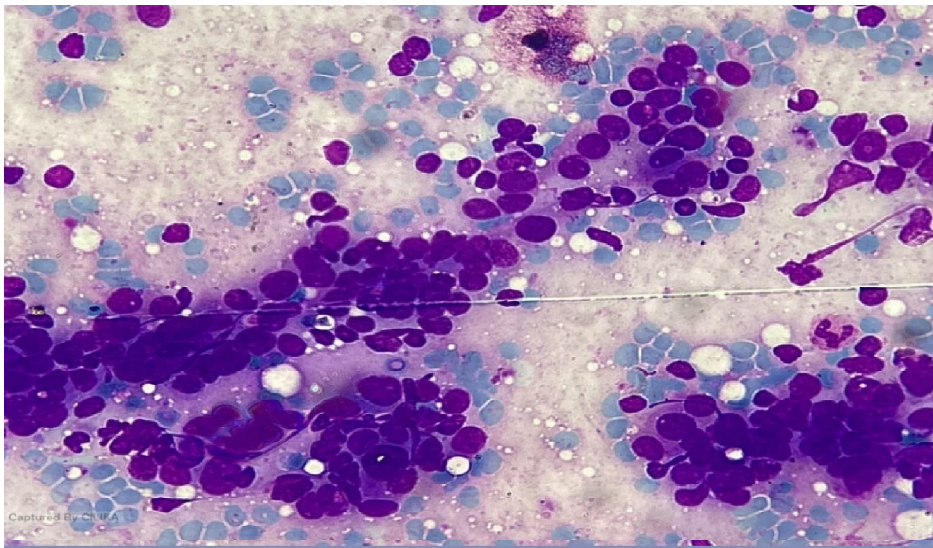


Fig 1. Microscopic examination cellular smears show groups of tumour cells and poorly formed acini and few singly dispersed cells.Tumour cells have round nuclei with dense chromatin without nucleoli. Cytoplasm is scanty and ill defined. No nuclear pleomorphism,mitosis or necrosis seen.Background is clean .(Basaloid cell neoplasm salivary gland.)

**DISCUSSION:-** This report presents a rare case of involvement of parotid lymph node which according to studies is > 1%. Nasopharyngeal carcinoma presents with a heavy disease burden in level II that may cause blockage of normal routes and induce retrograde tumour spread to the parotid lymph node. The prognostic value and staging category of the parotid lymph node in nasopharyngeal carcinoma remains unknown.

However, the close association between EBV and nasopharyngeal carcinoma is well known. In patients with EBV positive cervical lymph nodes in metastatic carcinoma of unknown origin, the most common primary sites involved are nasopharyngeal carcinoma (51.7%), salivary glands (24.5%), and lung (7.8%), oropharynx (3.3%).

Various studies have utilized the EBER –ISH test for diagnosis in case of metastatic unknown origin in the neck when a biopsy primary is not informative. EBER –ISH has the advantage of being able to precisely localize EBV in tumour cells.

### **Conclusion:**

In this case, Epstein-Barr encoding area in situ hybridization was used to diagnose the patient with an unknown primary tumour. It is well known that the Epstein-Barr virus and nasopharyngeal carcinoma are strongly correlated. EBER-ISH technique is useful in identifying the nasopharyngeal histogenesis of neck masses of unknown primary tumours.

### **Ethical Approval and Consent :**

#### **Ethical Approval:**

As per international standard or university standard written ethical approval has been collected and preserved by the author(s).

#### **Consent**

As per international standard or university standard, patients' written consent has been collected and preserved by the author(s).

Acknowledgements:-.Authors would like to acknowledge Dr A.R.Khan ,pathologist for helping us with cytological examination and providing us with pictures and the patient involved in the study.

Conflict of interest:- The authors declare that the research was conducted in the absence of any commercial or financial relationships that could be constructed as potential interest of conflict.

Author information

Authors and Affiliations

Department of Radiation oncology, Government Medical College ,Srinagar, India.

Irfan Rasool Gadda, Syed Arshad Mustafa.

Corresponding author

Correspondence to Irfan Rasool

Author contributions:- IR ans SA devised the study design and concept,obtained the data and figures,drafted the manuscript and references,and carried out a critical review.

Consent :- Written informed consent was obtained from patient for publication of this case report.

## References

1. Ho, F. C., Tham, I. W., Earnest, A., Lee, K. M. & Lu, J. J. Patterns of regional lymph node metastasis of nasopharyngeal carcinoma: a meta-analysis of clinical evidence. *BMC Cancer* 12, pp98 (2012)
2. Sham, J. S., Choy, D. & Wei, W. I. Nasopharyngeal carcinoma: orderly neck node spread. *Int J Radiat Oncol Biol Phys* 19,pp 929–933 (1990).
3. Ng, S. H. et al. Nodal metastases of nasopharyngeal carcinoma: patterns of disease on MRI and FDG PET. *Eur J Nucl Med Mol Imaging* 31, pp1073–1080 (2004).
4. . Liu, L. Z. et al. Magnetic resonance imaging of retropharyngeal lymph node metastasis in nasopharyngeal carcinoma: patterns of spread. *Int J Radiat Oncol Biol Phys* 66,pp 721–730 (2006).
5. Tang, L. et al. The volume to be irradiated during selective neck irradiation in nasopharyngeal carcinoma: analysis of the spread patterns in lymph nodes by magnetic resonance imaging. *Cancer* 115,pp 680–688 (2009).

6. Li, W. F. et al. Locoregional extension patterns of nasopharyngeal carcinoma and suggestions for clinical target volume delineation. *Chin J Cancer* 31, pp579–587 (2012)
7. King, A. D. et al. Neck node metastases from nasopharyngeal carcinoma: MR imaging of patterns of disease. *Head Neck* 22,pp 275–281 (2000).
8. L Calabrese, BA Jereczek-Fossa,<sup>1</sup> J Jassem,<sup>3</sup> A Rocca,<sup>2</sup> R Bruschini, R Orecchia,<sup>1,4</sup> and F Chiesa Diagnosis and management of neck metastases from an unknown primary. *Acta Otorhinolaryngol Ital.* 2005 Feb; 25(1): pp 2–12
9. Lawrence S. Young<sup>1</sup> and Christopher W. Dawson<sup>2</sup> Epstein-Barr virus and nasopharyngeal carcinoma *Chin J Cancer.* 2014 Dec; 33(12):pp 581–590.
10. Kelly Y. Kim, Quynh-Thu Le, Sue S. Yom, Benjamin A. Pinsky, Scott V. Bratman, Raymond H. W. Ng, Haja S. El Mubarak, K. C. Allen Chan, Miriam Sander, and Barbara A. Conley Current State of PCR-Based Epstein-Barr Virus DNA Testing for Nasopharyngeal Cancer *J Natl Cancer Inst.* 2017 Apr; pp109(4)
11. Wang, X., et al. Patterns of level II node metastasis in nasopharyngeal carcinoma. *Radiother Oncol* 89,pp 28–32 (2008).
12. . Chong, V. F. & Fan, Y. F. Parotid gland involvement in nasopharyngeal carcinoma. *J Comput Assist Tomogr* 23,pp 524–528 (1999).